

# Lung and Liver Hydatid Cyst: A Unique Single Stage Approach

Dr. Dharmik Patel<sup>1</sup>, Dr. JG Bhatt<sup>2</sup>, Dr. JG Vagadiya<sup>3</sup>, Dr. Binoy Behra<sup>4</sup>

<sup>1</sup>2nd Year Surgery Resident, <sup>2</sup>HOD & Professor, <sup>3</sup>Associate Professor, <sup>4</sup>3rd Year Surgery Resident  
<sup>1, 2, 3, 4</sup>PDUMCH, Rajkot

## Abstract

Hydatid cyst commonly affects liver followed by lung, but rarely affects both organs simultaneously. Here we presented a patient who presented with concurrent involvement of both lungs and liver. Concomitant pulmonary and liver hydatid cysts occur in 4% to 25% of patients with echinococcosis. Ultrasonography, computed tomography, and magnetic resonance imaging can recognise certain details of the lesions and discover others that are not visible by conventional radiography. For a specific serologic diagnosis, our experience favours the immunoglobulin G enzyme-linked immunosorbent assay and immunoelectrophoresis. Four treatment options are currently available: radical surgery, conservative surgery, puncture-aspiration-injection-respiration (PAIR), and anti parasitic medical treatment. Surgery is gold standard for liver hydatid cyst and can be done by open/laparoscopic approach. The prognosis has changed during the last few years, and results are now commonly satisfactory. Operative mortality does not exceed 1% to 2%.

## Introduction

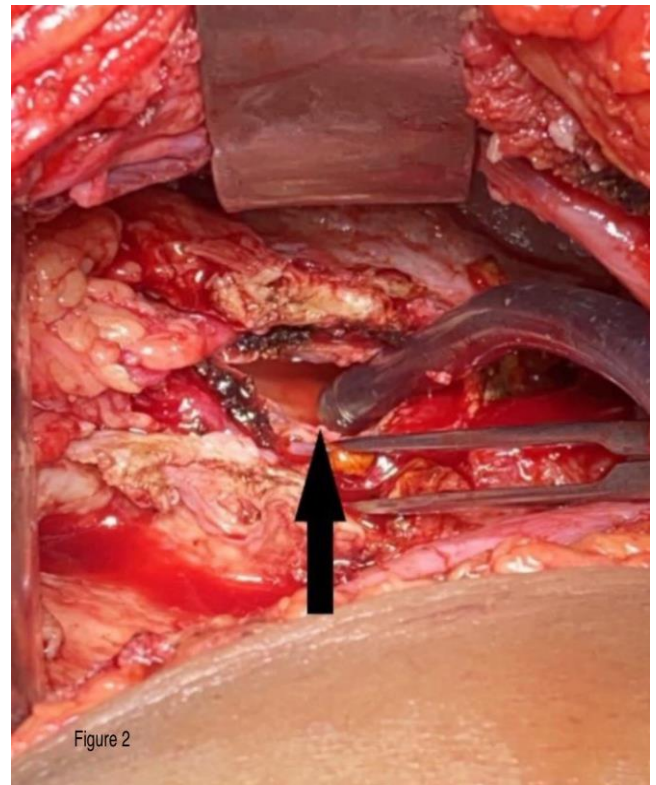
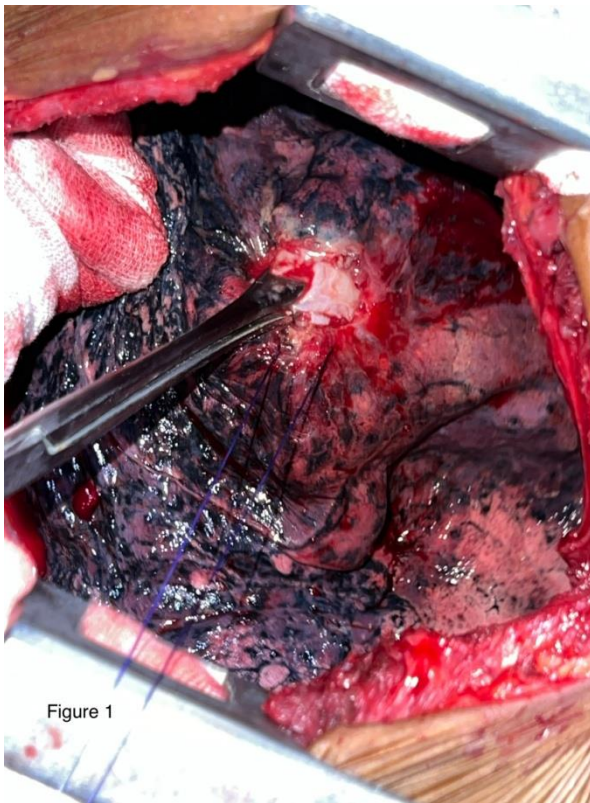
Hydatid disease (HD), or echinococcosis, is a widespread zoonotic parasitic disease caused by a tapeworm that till date continues to be a clinical and public health problem worldwide, especially in areas where animal grazing (especially sheep grazing) and subsistence farming form an integral part of community life. The most common sites affected are the liver (63%), the lungs (25%), followed by muscles (5%), bones (3%), kidney (2%), spleen (1%), and other sites (1%) Humans are accidental hosts and play little part within the transmission of the disease, making them so-called “dead-end hosts.” There are different treatment modalities in management of liver hydatid cyst, treatment should be considered as early as possible due to risk of complications associated with the disease if left untreated. Despite availability of non-surgical management for hydatid cyst, surgery remains mainstay treatment either through open or laparoscopic approach. The goal of surgical management of echinococcosis is to eliminate local disease, treat associated complications and avoid recurrence of the disease while minimizing morbidity and mortality related to the treatment itself. Despite surgical and medical management available for hydatid cyst treatment, recurrence remains one of the common complications encountered in surgical practice. In approximately 8% of cases, the hydatid cyst is located in both the liver and lungs. When the hydatid cyst is intact, it appears on direct radiographs as a round radiopacity with smooth margins. In endemic areas, the diagnosis is made by clinical and radiologic findings. Although hydatid cysts can be large, the coexistence of giant cysts in both the liver and lungs is rare in a forty-two year old patient as of ours.

## Case report

A forty-two year old female admitted with complaints of gradually enlarging abdominal mass involving the lower abdomen since six months which is associated with dull aching and non radiating pain. On examination an abdominal mass of size approx 6x5cm present over the umbilical region extending with upper border 5cm above umbilicus with no movement on respiration (figure 1). Mass was ovoid in shape with smooth surface, firm in consistency with regular margins, non mobile and on head and leg raising test the mass does not increase in size suggesting peritoneal mass. Ultrasound suggestive of 7x7 cm of cystic lesion noted in right lobe of liver. CECT abdomen and pelvis suggestive of well defined thick walled non enhancing cystic lesion within abdominal cavity measures 7x7x6 cm (APxTRxCC) with wall thickness of 3-4mm noted in segment IVb of liver. No evident of internal septations, solid areas or daughter cysts within. Similar cystic lesion is also noted in right lower pleural cavity along mediastinal and posterior

costal pleura. It abuts adjacent rib and vertebral body without invasion. The lesion measures 6.8x8.7x9.3 cm (APxTRxCC). Minimal pleural effusion is noted on right side. There is resultant atelectasis of basal segments of right lower lobe. Findings suggestive of hydatid cyst likely (type 1 GHARBI and type CE1 WHO grading likely).

Single stage approach for both liver and lung hydatid cysts was planned. First through right lateral thoracotomy lung hydatid cyst was approached (figure 1) and cyst was removed and thorough wash was given in cavity with scolicidal agent. Cavity was closed and two ICDs was placed and layered closure of the thoracotomy incision was done. This concluded first phase of single stage approach. For second phase, for liver hydatid cyst, right sided subcostal incision was made and liver hydatid cyst was identified. After confirmation with needle aspiration the cyst was removed (figure 2) and cavity was thoroughly washed with scolicidal agent. Abdominal Drain was placed and layered closure of right side subcostal incision was done. Post operatively oxygen support was kept and physiotherapy along with spirometry was started on POD 0 itself. Two ICDs were placed on the right side. The upper ICD was removed on POD3 as there was no output for consecutive three days but the lower ICD was having air leak and continuous serous discharge for which it was kept till POD-7. Serial chest X-rays and Ultrasonography were done till patient becomes completely normal. Patient was discharged on POD-10 with oral Albendazole. Patient is on regular follow up on out-patient basis till now.



### Discussion & Conclusion

Cystic echinococcosis is still a major problem, especially in rural areas.. Even though mortality due to echinococcosis is very low, it can produce a very disabling illness. Dissemination of Echinococcus in the body occurs through the bloodstream. Hydatid cyst can occur anywhere in the body but the two most commonly organs involved are liver and lungs. (Sachar S, 2014) Concurrent involvement of lung and liver accounts for 4% to 25% of patients with hydatid disease as depicted in the case report published by Aghajanzadeh et al. (M, 2008) Hydatid cyst can be found as solitary or multiple in numbers. In our case, the patient was found to have multiple hydatid cysts involving both lungs and liver. Mostly hydatid cysts found as the incidental finding and they remain asymptomatic. When these cysts produce symptoms, it is due to growing cyst which encroaches the involved organ as well as nearby structures. (Iqbal N, 2017) It has been noticed that lung cysts grow much faster than cyst in another organ of the body because of negative pleural

pressure. (Dincer SI, 2006) A cough, dyspnoea and haemoptysis can be the typical features of hydatid cyst affecting the lung. (S, 2012) Hepatomegaly and right upper quadrant abdominal pain can be the presenting features of hydatid cyst affecting the liver. In our case, the patient presented with abdominal pain and enlarging mass without any symptoms of cough or Diagnosis of echinococcosis of liver can be made easily but hydatid cyst at unusual sites (like lung, spleen, bone, kidney) needs clinical correlation, serological tests, and imaging study (USG, CT scan, and MRI scan) before any intervention can be planned. (Swamy PT, 2021)The diagnosis is usually difficult when hydatid cyst occurs at unusual locations. But USG is the preferred radiological method for cyst diagnosis because of its low cost and high specificity and sensitivity and it is easily available even at peripheral centers. CT, MRI, and MRCP have gained importance because of their ability to reveal characteristic relations of the Biliary/vascular system and hydatid cyst, as well as its relations with adjacent structures. The objectives of the perfect treatment modality are threefold: (1) removal of the whole parasite, (2) removal of the residual cavity (cyst wall), and (3) the identification and treatment of Biliary fistula. Four treatment options are currently available: radical surgery, conservative surgery, PAIR (puncture-aspiration-injection-respiration), and ant parasitic medical treatment with benzimidazoles (BMZs). (Blumgart LH, 2017) Surgery, which is the only treatment that reaches all the three objectives of the ideal treatment modality as mentioned above, is the most efficient treatment and can be done either conventionally or laparoscopically. (Swamy PT, 2021) Percutaneous and medical treatments represent alternative methods to surgery and are associated with their own sets of drawbacks and advantages. Sometimes surgical approach might not be feasible in patient with multi organ hydatid cyst. The introduction of chemotherapy and PAIR of the hydatid cysts of the liver (puncture-aspiration-injection-respiration) offers an alternate treatment option, especially in inoperable patients and for cases with a high surgical risk. Cysts with homogeneously calcified cyst wall probably need no surgery but only a 'wait and observe' approach. Many studies are conducted to check the feasibility of laparoscopic management of hydatid cyst disease. Laparoscopic surgery is safe and feasible in the majority of cases, but in case of large size and intra parenchymal cyst, open surgery is more commonly performed due to technical problems encountered during laparoscopic surgery. (M B. , 2019) Within the hands of an experienced surgeon complications in laparoscopic surgery decreases and is a better option, as it drastically reduces post op hospital stay and morbidity of patient. Albendazole and mebendazole are the two effective chemotherapeutic agents approved for the treatment of hydatid cysts. The duration of medical treatment ranges from 3 to 6 month, and it can be prolonged without any risk of side effects of the medication. (Iqbal N, 2017) In our case, the patient was successfully treated with albendazole 400mg (two times a day) for 6 months and showed sign of improvement both symptomatically and radiologically and currently under regular follow-up and on albendazole.

## References

- [1]. Sachar S, Goyal S, Goyal S, Sangwan S. Uncommon Locations And Presentations Of Hydatid Cyst. *Ann Med Health Sci Res.* 2014 May;4(3):447-52. Doi: 10.4103/2141-9248.133476. PMID: 24971224; PMCID: PMC4071749.
- [2]. Aghajanzadeh M, Safarpour F, Amani H, Alavi A. One-Stage Procedure For Lung And Liver Hydatid Cysts. *Asian Cardiovasc Thorac Ann.* 2008 Oct;16(5):392-5. Doi: 10.1177/021849230801600510. PMID: 18812348.
- [3]. Iqbal N, Hussain M, Idress R, Irfan M. Disseminated Hydatid Cyst Of Liver And Lung. *BMJ Case Rep.* 2017 Nov 28;2017:Bcr2017222808. Doi: 10.1136/Bcr-2017-222808. PMID: 29184009; PMCID: PMC5720282.
- [4]. Dincer SI, Demir A, Sayar A, Gunluoglu MZ, Kara HV, Gurses A. Surgical Treatment Of Pulmonary Hydatid Disease: A Comparison Of Children And Adults. *J Pediatr Surg.* 2006 Jul;41(7):1230-6. Doi: 10.1016/J.jpedsurg.2006.03.053. PMID: 16818054.
- [5]. Toleti S, Subbarao M, Dwarabu P. Hydatid Disease Of The Lung Presenting With Hemoptysis And Simulating A Lung Abscess.

Trop Parasitol. 2012 Jan;2(1):69-70. Doi: 10.4103/2229-5070.97248. PMID: 23508291; PMCID: PMC3593498.

[6]. Swamy PT, Vagadia JG, Bhatt JG, Dave JP. Recurrent Liver Hydatid Cyst And Port Site Hydatid Cyst In Anterior Abdominal Wall

In Operated Case Of Laparoscopic Cystostomy For Liver Hydatid Cyst: A Rare Complication. Int Surg J 2021;8:3495-7.

[7]. Blumgart's Surgery Of The Liver, Biliary Tract, And Pancreas, By Blumgart LH, Jarnagin WR, Elsevier. 2017;1102-21.

[8]. Bayrak M, Altıntas Y. Current Approaches In The Surgical Treatment Of Liver Hydatid Disease: Single Center Experience. BMC

Surg. 2019;19:95.