

Role of high resolution ultrasonography and elastography in cervical lymphadenopathy

Dr Vitthal Nagargoje, Dr Gautam M

Junior Resident, Professor and HOD
Rajarajeswari Medical College and Hospital, Bengaluru

ABSTRACT:

Back ground: This study was carried out to compare the results of ultrasonogram and elastography with histopathological examination(HPE) so as to determine the accuracy and efficacy of sonoelastography in differentiating benign and malignant nodes as well as differentiating between various benign cases like tuberculous and other reactive nodes.

Materials and methods: A Prospective study was conducted among 85 patients with cervical lymphadenopathy referred to the department of Radio-diagnosis, RRMCH for duration of one year. They were subjected to Ultrasonography and Doppler study of the neck and Ultrasonogram guided FNAC / biopsy. The characteristic features of each lymph node and intra nodal vascular pattern was noted down. The pattern of elastography was stored and analysed. The histopathological results were compared with sonographic and elastographic diagnosis.

Results: Majority of the lymph nodes were round (62.4%), hypoechoic (92.9%), had unsharp margins (54.1%). Most common pattern seen on radiodiagnosis was hilar (34.1%) whereas on elastography, most common pattern was very soft in 29.4%. HPE showed significant association with both radio-diagnosis and elastography diagnosis ($P<0.05$). The sensitivity of radiological diagnosis was 88.9 and the specificity was 98.0 which are quite high. The sensitivity and specificity were 88.9% and 89.8% respectively which is slightly lower compared to radiological diagnosis.

Conclusion: Combination of elastography and B- mode ultrasonogram, can increase the sensitivity to 100% and specificity also increases in differentiating benign and malignant nodes Elastography can be included in the initial workup of the patients with cervical lymphadenopathy, so that more malignancy can be brought into light.

Keywords: Cervical lymphadenopathy, Elastography, Ultrasonography, Sensitivity, Specificity.

INTRODUCTION:

Physicians frequently encounter cervical lymphadenopathy in clinical practice. The etiology behind it could be a number of pathologic conditions, including infections, vasculitis, and cancers including lymphoma and metastases. In head and neck oncology, metastatic cervical lymphadenopathy is a frequent issue. Up to 80% of patients with upper aerodigestive mucosal cancer have been documented to develop cervical nodal metastases upon presentation, depending on the initial site.¹ The ability to distinguish between benign and malignant lymph nodes (LNs) is crucial for decision-making and management planning, as well as for predicting the prognosis of the patient.²

The foremost investigation used for the evaluation of cervical lymphadenopathy is B-mode ultrasonography and is considered the initial investigation of choice. This along with Doppler study is a useful imaging tool in the assessment and characterisation of nodal morphology and their vascular pattern. But, there is no single US criterion for diagnosing malignant LNs with satisfactory sensitivity and specificity.^{3,4}

A new noninvasive imaging technique called real-time elastography (RTE) compares the local tissue displacement from US data before and after a compressive force is applied in order to evaluate the elasticity of the tissue.[6] When a transducer compresses soft tissues, stiff tissues exhibit less deformation (strain). Numerous studies have shown the value of US elastography in distinguishing between malignant and benign lesions in the breast, prostate, liver, thyroid, and cervix because malignant tissues are often stiffer than their benign counterparts.^{5,6,7,8} Shear wave-based elastography and strain elastography are the two categories of elastography procedures.

Strain elastography measures tissue displacement along the axis of the applied force. An elastic spring that is compressed or stretched along its axis exhibits this kind of displacement. Shear wave-based elastography is a recently developed elastography technique that measures a different type of wave that is generated when tissues are mechanically stimulated by focused pulses.⁹

OBJECTIVES:

To compare the results of ultrasonogram and elastography with histopathological examination so as to determine the accuracy and efficacy of sonoelastography in differentiating benign and malignant nodes as well as differentiating between various benign cases like tuberculous and other reactive nodes.

METHODOLOGY:

A Prospective study was conducted among 85 patients with cervical lymphadenopathy referred to the department of Radio-diagnosis, RRMCH for duration of one year (November 2022 to November 2023). After Ethical Committee approval, informed consent was obtained from all the study subjects before data collection. Data on complaints with duration, relevant past history was obtained, following which clinical examination of cervical lymph nodes was done. After this patients were subjected to Ultrasonography and Doppler study of the neck and Ultrasonogram guided FNAC / biopsy.

Sample size:

A sample size of 85 patients were included in the study.

Inclusion criteria:

- Patients with unilateral or bilateral cervical lymphadenopathy who are referred for ultrasonogram and ultrasonogram guided FNAC/biopsy.
- Patients with head and neck carcinoma with lymph nodal enlargement.
- Patients suspected with cervical lymph node secondaries of unknown primary.
- Patients suspected with pulmonary or extra pulmonary lymph nodal tuberculosis.
- Patients with reactive cervical lymphadenopathy, if not responding to treatment, after a period of follow up.

Exclusion criteria:

- Patients who underwent radiotherapy/ chemotherapy for cervical lymph node malignancy.
- Those who are on or completed treatment like anti-tuberculous drugs.
- Those who have undergone surgery like cervical lymph node excision.
- Those who have already underwent biopsy from the cervical lymph node.

Imaging technique:

Conventional B-Mode Ultrasonogram was done using Ultrasonogram machine SAMSUNG ACCUVIX XG AVXGE30/IN which was equipped with Elastoscan. The characteristic features of each lymph node and intra nodal vascular pattern was noted down. Once the Doppler evaluation was over, the setting was switched to elastography mode. The pattern of elastography was stored and analysed based on the scoring system proposed by Alam et al.¹⁰ After finishing the sonoelastography, ultrasound guided trucut biopsy of the studied node was taken on the same day. In cases where there is difficulty in obtaining biopsy, ultrasound guided FNAC was done. The histopathological results were obtained from the pathologist and they were compared with the results of sonographic and elastographic diagnosis.

Figure 1:

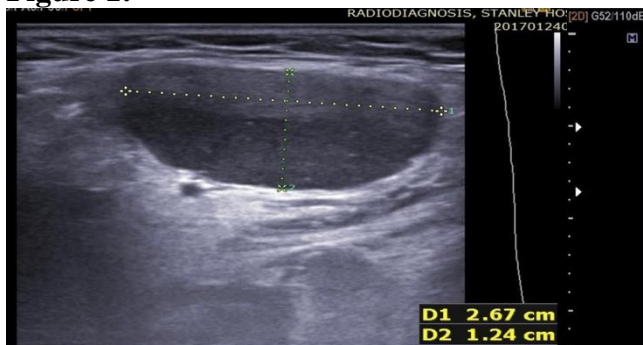


Figure 2:

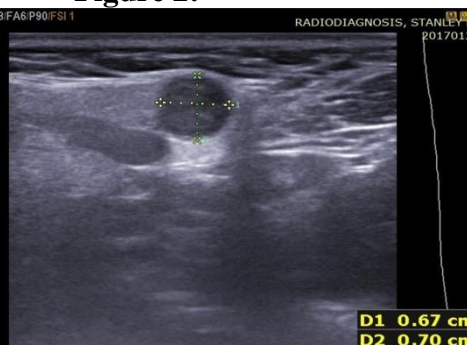


Figure 1: The picture shows B- mode ultrasonographic image of the benign cervical lymph node and its size and shape. The node is hypoechoic ,enlarged and is oval in shape with short to long axis ratio <0.6.
Figure 2: B- mode ultrasonographic image of the malignant cervical lymph node , node is not much enlarged but is round in shape with short to long axis ratio >0.6, borders sharply defined with absence of echogenic hilus. There is intranodal necrosis.

Figure 3:

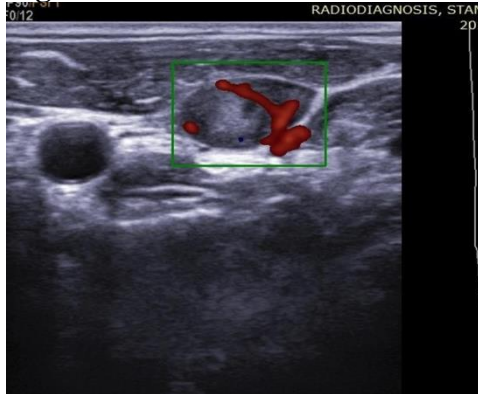


Figure 4:

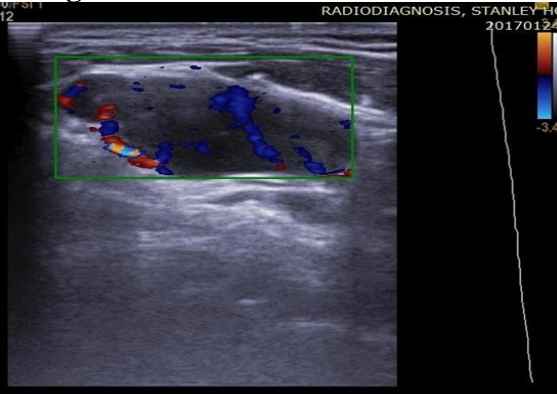


Figure 3: The picture shows B- mode ultrasonography along with colour doppler image of a cervical lymph node. The node is oval in shape with short to long axis ratio <0.6 and there is echogenic hilus, hilar vascularity within the node is noted. These features favours the benign nature of the node

Figure 4: B- mode ultrasonogram and colour doppler image of a cervical lymph node. The vascularity is both hilar as well as peripheral.

Figure 5:

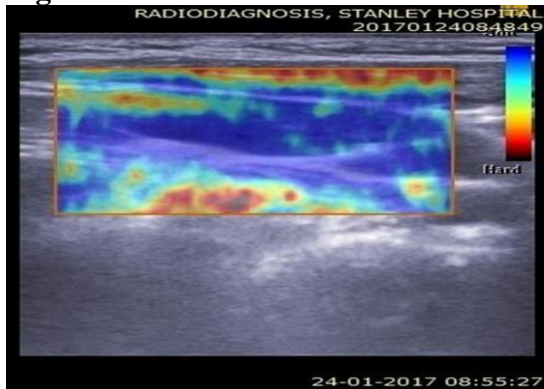


Figure 6:

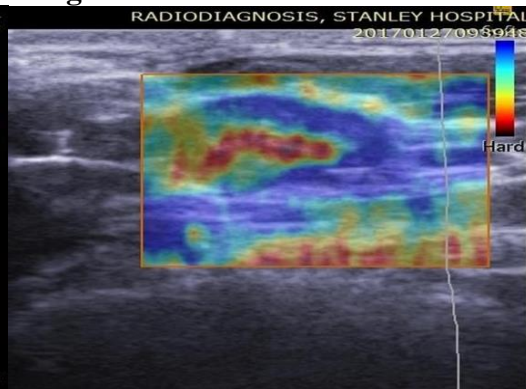


Figure 5: The picture shows elastographic image of a cervical lymph node. Elastographic image shows the node is predominantly blue in colour with red areas <45% suggestive of pattern 2 - soft node.

Figure 6: The picture shows elastographic image of a cervical lymph node. Elastographic image of the node shows mixed blue and red areas, red area is >45% suggestive of pattern 3 – mildly hard node.

Figure 7:

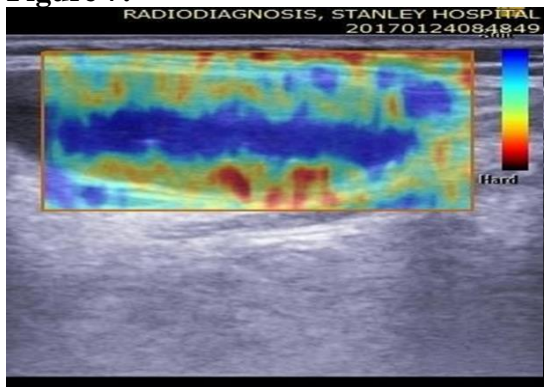


Figure 8:

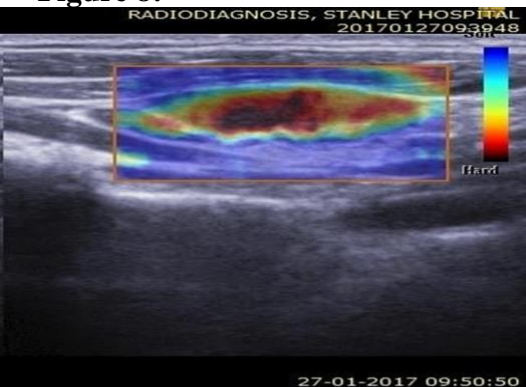

Figure 7: The picture shows elastographic image of a cervical lymph node. The node shows central blue areas and peripheral red areas, suggestive of pattern 4 – moderately hard node.

Figure 8: The picture shows elastographic image of a cervical lymph node. The node shows complete red areas without any blue area, suggestive of pattern 5– very hard node.

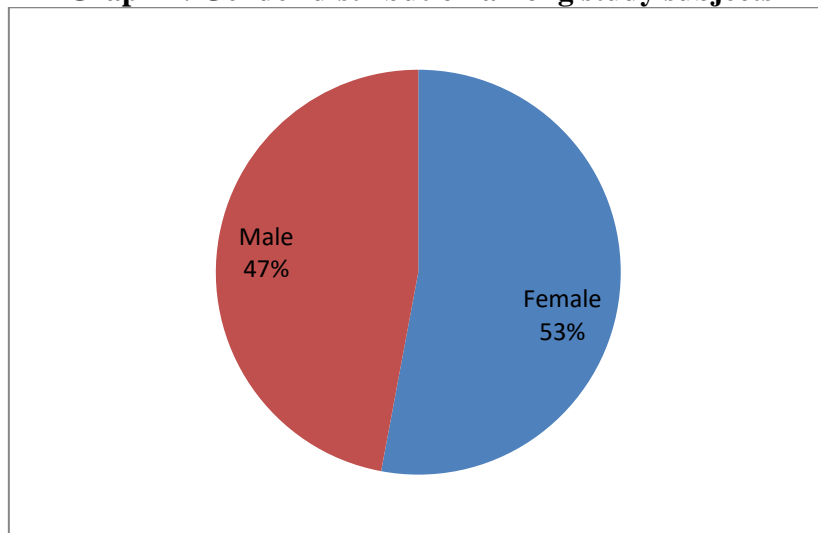
STATISTICAL ANALYSIS:

The collected data was entered in an excel sheet and was analysed with SPSS statistics software (version 26.0). Continuous variables were expressed as mean with standard deviation (SD) or median with interquartile range (IQR) were used depending on the normality of distribution. Categorical variables were expressed as frequency and percentages. To find the significance in categorical data, Chi-Square test was used. All statistical tools were carried out at the level of significance of 5% and the probability - p value <0.05 was considered significant. The receiver operating characteristic (ROC) curves were used and area under the curve was calculated to find the sensitivity, specificity, positive predictive value and negative predictive value on comparison of radiological diagnosis and elastographic diagnosis with histopathological examination.

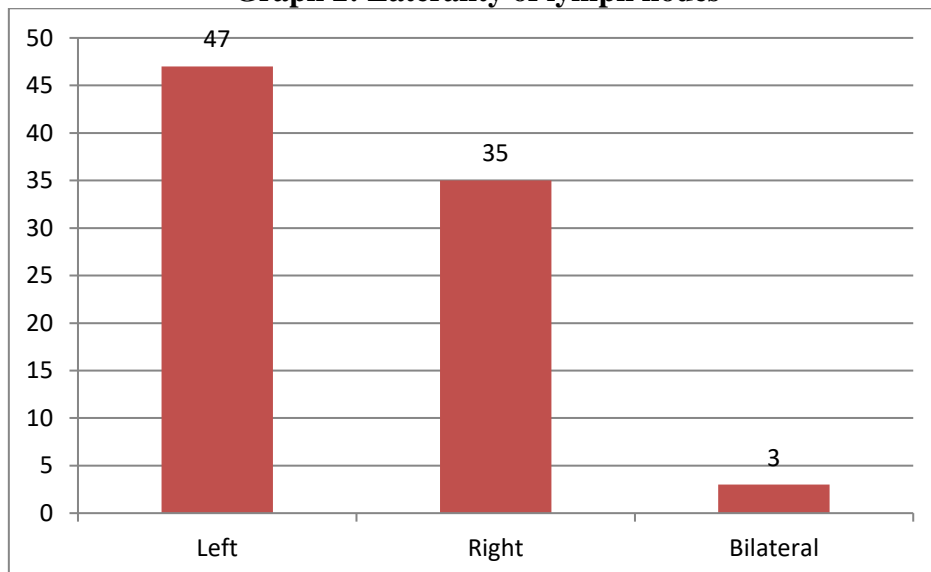
RESULTS:

Total 85 subjects were included in the study. Mean age was found to be 43.16±15.917 years, mean number of lymph nodes included in the study were 6.68±3.441. Mean short axis diameter was 15.67±4.772 mm and mean long axis diameter was 23.85±5.241 mm and the mean short axis to long axis diameter ratio was 0.65±146. Female predominance was observed in the study (53%) (Graph 1)

Graph 1: Gender distribution among study subjects



Graph 2: Laterality of lymph nodes



Majority of the subjects presented with left sided cervical lymphadenopathy (55.3%), followed by right sided (41.2%) and bilateral (3.5%). (Graph 2)

Table 1: Characteristics of lymph nodes

Characteristic		Frequency	Percentage
Shape of the node	Round	53	62.4
	Oval	32	37.6
Echogenicity	Hypoechoic	79	92.9
	Hyperechoic	4	4.7
	Isoechoic	2	2.4
Margins	Unsharp	46	54.1
	Sharp	24	28.2
	Illdefined/blurred	15	17.6
Hilar echogenicity in nodes	Absent	53	62.4
	Present	32	37.6
Necrotic/cystic areas in nodes	Absent	48	56.5
	Present	37	43.5
Calcifications in nodes	Absent	82	96.5
	Present	3	3.5
Eccentric cortical hypertrophy	Absent	75	88.2
	Present	10	11.8
Matting/edema	Absent	61	71.8
	Present	24	28.2

Table 1 shows the characteristic features of the lymphnodes. Majority of the lymph nodes were round (62.4%), hypoechoic (92.9%), had unsharp margins (54.1%). Hilar echogenicity was present in 37.6%, necrotic/cystic areas in 43.5%, calcification in 3.5%, eccentric cortical hypertrophy was seen in 11.8% and matting/edema was seen in 28.2% of the lymphnodes.

Table 2: Distribution of vascularity pattern of lymph nodes

	Frequency	Percent
On Radio-diagnosis		
Hilar	29	34.1
Peripheral	16	18.8
Both	27	31.8
Displaced Hilar	7	8.2
Absent	6	7.1
On Elastography		
Very Soft	25	29.4
Soft	23	27.1
Mildly hard	9	10.6
Moderately hard	16	18.8
Very hard	12	14.1

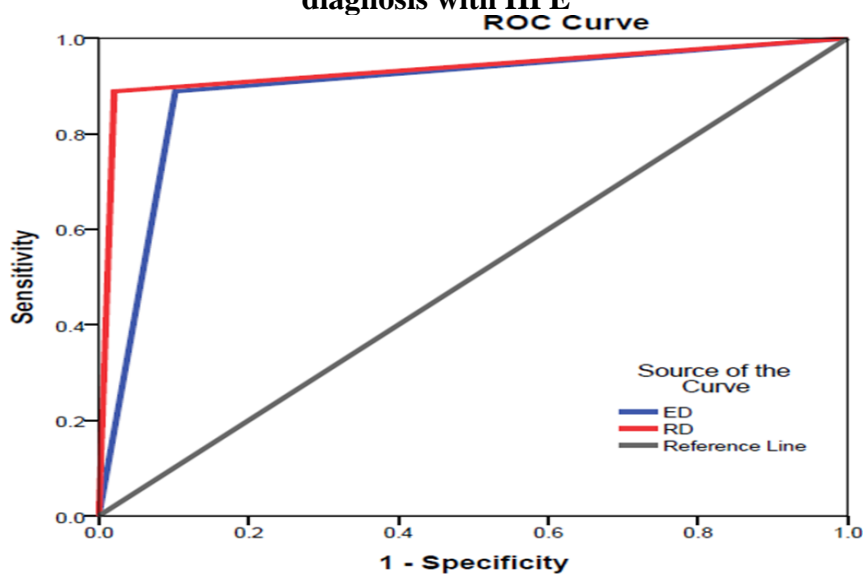
Most common pattern seen on radiodiagnosis was hilar (34.1%), followed by both hilar and peripheral in 31.8%. On elastography, most common pattern was very soft in 29.4% followed by soft in 27.1%. (Table 2)

Table 3: Association between Radio-diagnosis and HPE, Elastography diagnosis and HPE

			HPE REPORT				Total	P value
			Benign	Malignant	Reactive	Tuberculosis		
RADIOLOGICAL DIAGNOSIS	Benign	N	10	3	1	0	14	0.0005
		%	90.9%	8.3%	7.1%	0.0%	16.5%	
	Malignant	N	1	32	0	0	33	
		%	9.1%	88.9%	0.0%	0.0%	38.8%	
	Reactive	N	0	1	13	0	14	
		%	0.0%	2.8%	92.9%	0.0%	16.5%	
	Tuberculosis	N	0	0	0	24	24	
		%	0.0%	0.0%	0.0%	100.0%	28.2%	
ELASTOGRAPHIC DIAGNOSIS	Benign	N	9	2	9	6	26	0.0005
		%	81.8%	5.6%	64.3%	25.0%	30.6%	
	Malignant	N	1	31	1	4	37	
		%	9.1%	86.1%	7.1%	16.7%	43.5%	
	Reactive	N	1	3	4	14	22	
		%	9.1%	8.3%	28.6%	58.3%	25.9%	

Significant association was observed between radio diagnosis and HPE and also between elastography diagnosis and HPE. (P<0.05). (Table 3).

Graph 3: Receiver operating characterizing curve for comparing Radio diagnosis and Elastography diagnosis with HPE



**Table 4: Results of ROC curve
AREA UNDER THE CURVE**

Test Result Variable(s)	Area	p value	Sensitivity	Specificity	PPV	NPV	Asymptotic 95% Confidence Interval	
							Lower Bound	Upper Bound
RD	.934	.0005	88.9	98.0	97.0	92.3	.869	.999
ED	.893	.0005	88.9	89.8	86.5	91.7	.816	.971

ED – elastographic diagnosis RD – radiological diagnosis

For radiological diagnosis, result of ROC curve showed that the area under the curve was 0.934 which was well above the value of 0.5 with 95% confidence interval between 0.869 and 0.999. With this, the sensitivity of radiological diagnosis was 88.9 and the specificity was 98.0 which are quite high. The positive predictive value and negative predictive value were also high, the values being 97.0% and 92.3% respectively. (table 4)

For elastographic diagnosis, the area under the curve was 0.893 which was well above 0.5, but little lower when compared to the radiological diagnosis. The 95% confidence interval here was between 0.816 and 0.971. The sensitivity and specificity were 88.9% and 89.8% respectively which is slightly lower on comparing with radiological diagnosis. The positive predictive value was 86.5% and negative predictive value was 91.7%. (table 4).

DISCUSSION:

We conducted the study in the Department of Radiodiagnosis, RRMCH with 85 patients having cervical lymphadenopathy who satisfied the inclusion and exclusion criteria. The mean age of the participants was 43.16 ± 15.91 with minimum age of 9 and maximum age of 76. There was a female preponderance in our study constituting 52.9% with male occupying 47.1%. 55.3% of the patients had left sided disease in our study, 41.2% were right side with only 3.5% of the patients showing bilateral disease.

The number of nodes in a single patient was variable in our study population ranging from 1 to maximum of 17 with mean value of 6.68. However, for our study we took single node from each patient, with nodal selection criteria as size – single largest node was studied. This was because for a single patient, the pathology would be the same and so we would not be able to study a variety of pathologies if we took all nodes from a single patient.

We studied all the ultrasound criteria for every node including shape, short axis and long axis diameter, short to long axis ratio, margin, echogenicity, hilar presence, presence or absence of other features like necrosis, calcification, eccentric cortical hypertrophy, matting and adjacent edema. Ying M. et al.¹¹ and Alam et al.¹⁰ also studied the above criteria for in their studies of ultrasound of cervical lymphnodes.

The Doppler flow pattern was also included in our study. This was comparable with the study by Ying M. et al.¹¹ regarding the ultrasonographic and Doppler criteria for cervical lymphadenopathy.

The mean short axis diameter of the nodes was 15.67 ± 4.772 mm with minimum and maximum values of 7 and 25mm respectively. If the short axis diameter is >8 mm, it was considered malignant. Alam et al.¹⁰ also considered the same size for short axis diameter as a cut off with sensitivity of 84%. But in our study, there were some nodes which had smaller diameter but the presence of other features were suggestive of malignancy. Similarly mean of the long axis diameter was 23.85 with minimal value of 13 and maximum value of 36.

Short-long axis ratio considered as the most important criteria for the nodes to be characterized as malignant. Its mean value was 0.65 with maximum and minimum value of 0.4 and 0.96 respectively. We

took the value of 0.6 as the cut off for benignity and malignancy. It gave the sensitivity value of 88.9% and specificity of 98%, the positive predictive value and negative predictive value were 97% and 92.3% respectively. Alam et al.¹⁰ and Mohamed et al.¹² also referred the cut off value for S/L ratio as 0.6. The sensitivity and specificity in Mohamed et al.¹² were 79.2% and 51.1% only which was lesser compared to the present study. Considering the S/L ratio, the shape of the node was also noted either oval or round. In our study round nodes were malignant which were pathologically proved.

Most of the nodes were hypoechoic which included both benign as well as malignant nodes and it did not confer any diagnostic value. However 4.7% of the nodes were hyperechoic which were proved to be papillary carcinoma metastasis. And 2.4% of nodes were isoechoic to surrounding structures.

On assessing the margin of the nodes, considering the sharpness of the margin as a criteria for malignancy, 72.72% of the malignant nodes in our study showed sharp margin. Others show either unsharp or illdefined margins. Very few studies done by Ying et al.¹³ Ahuja et al.¹⁴ Ying et al.¹¹, and Alam et al.¹⁰ evaluated lymph node borders as sharp and unsharp.

Absence of echogenic hilus in the node was considered as either malignancy or tuberculosis, but their presence is not a criteria for benign nodes. In our study, only 62.4% of the nodes showed hilar absence, even though malignant and tuberculous nodes constitute 67%. Only 43.5% of nodes showed the presence of necrotic areas which was considered another criteria for the malignancy and tuberculosis against 67% of total malignant and tuberculous nodes.

Cortical hypertrophy if present, that too eccentrically located was diagnostic of malignancy. In our study only 30.3% of the malignant nodes had eccentric cortical hypertrophy.

In our study 3 patients had intranodal calcifications, they were proved to be metastasis from papillary carcinoma of thyroid. Calcification was not considered as a criteria of malignancy, but in specific malignancies like papillary and medullary carcinoma metastasis it plays a role in diagnosis.

Matting of nodes was considered as an important criteria for tuberculosis, which was seen in all tuberculous nodes in our study.

In our study Doppler flow was used as another entity for diagnosing malignant nodes. Normal hilar flow was seen in 34.1% of the nodes including benign as well as malignant conditions, but the presence of peripheral vascularity with or without hilar vascularity was specific for malignancy. Peripheral vascularity was seen in 18.8% of nodes and both peripheral and hilar vascularity was seen in 31.8% of nodes. On combining these two groups, 50.6% of nodes had peripheral vascularity with or without vascularity in the hilum. However, in our study malignant nodes comprised only 38.8%, which proved that peripheral vascularity was not a specific criteria for malignancy. It was also seen in some reactive and inflammatory nodes. Mohamed et al.¹² and Ying.M et al.¹¹ also studied the Doppler features to differentiate the benign and malignant nodes.

Thus, comprising all the above criteria, we divided the nodes into four radiological diagnostic groups – normal benign, reactive, tuberculosis and malignancy. We considered the nodes to be malignant when 4 or more criteria favoured malignancy. Among the 85 nodes we studied, 16.5% were benign, another 16.5% were reactive, 28.2% were tuberculosis and 38.8% were malignant nodes. On comparing this with histopathological report, radiological diagnostic rate of malignancy was slightly decreased – HPE showed 42.3% of nodes to be malignant. However, reactive as well as tuberculous nodes were diagnosed with 100% accuracy when compared to HPE results.

The sensitivity and specificity of diagnostic value of sonography in differentiating the malignant nodes from benign nodes were 88.9% and 98.0% respectively with positive predictive value of 97.0% and negative predictive value of 92.3%.

We grouped the patterns of elastography obtained from 85 nodes into five which was according to the pattern classification by Alam et al.¹⁰ The distribution of five patterns were as follows – very soft pattern was seen in 25 patients which accounts for 29.4%, soft pattern was seen in 23 nodes accounting for 27.1%. These two patterns were considered as benign nodes, constituting totally of 56.5% (48 nodes). Remaining 43.5% of nodes were malignant which showed other three patterns like hard pattern seen in 9 patients accounting for 10.6%, moderately hard nodes seen in 16 patients accounting for 18.8% and very hard nodes were seen in 12 patients which constitutes 14.1%.

Thus in elastography, 37 nodes were diagnosed as malignant, 26 nodes as benign and 22 nodes as reactive

which constitute about 43.5%, 30.6% and 25.9% respectively. The sensitivity and specificity for elastography in differentiating benign and malignant nodes were 88.9% and 89.8% with PPV and NPV of 86.5% and 91.7% respectively.

With elastography, we could confidently distinguish only the malignant and benign nodes, but there was little difficulty in distinguishing the various causes of benign nodes. There was overlap between the first two patterns in case of normal benign, reactive and tuberculous nodes diagnosed by sonography. Very soft pattern was noted only in benign normal nodes. However, second pattern - soft node was seen in most of the reactive nodes. So, we gave a diagnosis of reactive node for the pattern 2 on elastography. But some of the tuberculous nodes also show this pattern which was also reported as reactive nodes. And some of the tuberculous nodes with central necrosis show pattern 4 of elastography which was considered malignant. In western countries where the previous studies of elastography were done, malignancy was the most common problem. But in India, tuberculosis is the predominant disease.

Hence there are slight variations in the sensitivity and specificity of elastography in our study when compared to the study by Alam et al.¹⁰ which showed sensitivity of 83% and specificity of 100%.

CONCLUSION:

The conclusions derived from our study are:

- The real time strain elastography shows maximum strain over benign lymph nodes and less strain over the malignant lymph nodes. Thus it can distinguish benign and malignant cervical lymph nodes with high sensitivity and specificity.
- But it is not very useful in case of differentiating various etiologies in benign nodes – like reactive or tuberculosis.
- On combining elastography with B- mode ultrasonogram, the sensitivity to differentiate benign and malignant nodes will increase to 100% and specificity will also be very high.
- Elastography can be included in the initial workup of the patients with cervical lymphadenopathy, so that more malignancy can be brought into light.
- It can be used as an adjunct tool with sonography in characterising the cervical lymph node in the work up of patients with head and neck carcinoma.
- Even though it can differentiate the malignant nodes from benign nodes, HPE is needed to confirm the diagnosis since few percent of malignancy can be missed.
- But it can be used as a guide to select the appropriate node for biopsy.

REFERENCES:

1. Chong V. Cervical lymphadenopathy: what radiologists need to know. *Cancer Imaging*. 2004;4(2):116.
2. Na DG, Lim HK, Byun HS, Kim HD, Ko YH, Baek JH. Differential diagnosis of cervical lymphadenopathy: usefulness of color Doppler sonography. *AJR. American journal of roentgenology*. 1997 May;168(5):1311-6.
3. Leboulleux S, Girard E, Rose M, Travagli JP, Sabbah N, Caillou B, Hartl DM, Lassau N, Baudin E, Schlumberger M. Ultrasound criteria of malignancy for cervical lymph nodes in patients followed up for differentiated thyroid cancer. *The Journal of Clinical Endocrinology & Metabolism*. 2007 Sep 1;92(9):3590-4.
4. Gupta A, Rahman K, Shahid M, Kumar A, Qaseem SD, Hassan SA, Siddiqui FA. Sonographic assessment of cervical lymphadenopathy: Role of high-resolution and color Doppler imaging. *Head & neck*. 2011 Mar;33(3):297-302.
5. Thomas A, Fischer T, Frey H, Ohlinger R, Grunwald S, Blohmer JU, Winzer KJ, Weber S, Kristiansen G, Ebert B, Kümmel S. Real-time elastography—an advanced method of ultrasound: first results in 108 patients with breast lesions. *Ultrasound in Obstetrics and Gynecology: The Official Journal of the International Society of Ultrasound in Obstetrics and Gynecology*. 2006 Sep;28(3):335-40.
6. Friedrich-Rust M, Ong MF, Herrmann E, Dries V, Samaras P, Zeuzem S, Sarrazin C. Real-time elastography for noninvasive assessment of liver fibrosis in chronic viral hepatitis. *American Journal of*

Roentgenology. 2007 Mar;188(3):758-64.

7. Asteria C, Giovanardi A, Pizzocaro A, Cozzaglio L, Morabito A, Somalvico F, Zoppo A. US-elastography in the differential diagnosis of benign and malignant thyroid nodules. *Thyroid*. 2008 May 1;18(5):523-31.
8. Thomas A, Kummel S, Gemeinhardt O, Fischer T. Real-time sonoelastography of the cervix: tissue elasticity of the normal and abnormal cervix. *Academic radiology*. 2007 Feb 1;14(2):193-200.
9. Ghafoori M, Azizian A, Pourrajabi Z, Vaseghi H. Sonographic evaluation of cervical lymphadenopathy; comparison of metastatic and reactive lymph nodes in patients with head and neck squamous cell carcinoma using gray scale and Doppler techniques. *Iranian Journal of Radiology*. 2015 Jul;12(3).
10. Alam F, Naito K, Horiguchi J, Fukuda H, Tachikake T, Ito K. Accuracy of sonographic elastography in the differential diagnosis of enlarged cervical lymph nodes: comparison with conventional B-mode sonography. *American journal of roentgenology*. 2008 Aug;191(2):604-10.
11. Ying M, Bhatia KS, Lee YP, Yuen HY, Ahuja AT. Review of ultrasonography of malignant neck nodes: greyscale, Doppler, contrast enhancement and elastography. *Cancer imaging*. 2013;13(4):658.
12. Hefeda MM, Badawy ME. Can ultrasound elastography distinguish metastatic from reactive lymph nodes in patients with primary head and neck cancers?. *The Egyptian Journal of Radiology and Nuclear Medicine*. 2014 Sep 1;45(3):715-22.
13. Ying M, Ahuja AT, Evans R, King W, Metreweli C. Cervical lymphadenopathy: sonographic differentiation between tuberculous nodes and nodal metastases from non-head and neck carcinomas. *Journal of clinical ultrasound*. 1998 Oct;26(8):383-9.
14. Ahuja A, Ying M, King W, Metreweli C. A practical approach to ultrasound of cervical lymph nodes. *The Journal of Laryngology & Otology*. 1997 Mar;111(3):245-56.