

EFFICACY OF COMBINED USAGE OF FOLEYS WITH MISOPROSTOL FOR SECOND AND EARLY THIRD TRIMESTER TERMINATION IN PREGNANCY

PRIYA¹, RAMYA K², KALA K³

¹Final year post graduate, ²Assistant Professor, ³Professor and HOD

Department of Obstetrics and Gynaecology, Akash institute of medical sciences and research centre, Devanahalli

Abstract : **Background :** Second trimester pregnancy losses constitute 10 to 15% of all pregnancy losses. Mid trimester pregnancy termination is a difficult procedure. Maternal mortality rate is 0.4/1 lakh, but in mid trimester 10.4/1 lakh, various methods including medical and mechanical have been used for induction. Misoprostol is safe, effective easily applicable non-invasive for mid trimester. In this trial the combination of intracervical foleys catheter and misoprostol was taken to reduce the dose of misoprostol and reduce the induction delivery interval.

Objective: To know the effectiveness and safety of combined intracervical foleys catheter and misoprostol use for mid trimester and early third trimester termination.

Method: We conducted a retrospective study from July 2022 - June 2023 of selective patients with gestational age between 14 weeks to 34 weeks. 14 F foleys catheter was inserted intra-cervically and instilled 30 cc sterile water. Simultaneously, misoprostol was given vaginally. Patients received misoprostol 200 µg in the second trimester and 100mcg in the early third trimester at the time of intracervical foley's placement and then 4th hourly till intracervical foley's expulsion. We primarily evaluated effectiveness and secondarily safety, complications and total dosage of misoprostol used.

Result : Out of 30 cases analysed, mean age of the group was 24years, for one patient more than three doses of misoprostol was required. Mean time of intracervical foley's expulsion to foetus expulsion is 1 hour, induction delivery interval on an average 12 hours, (minimum interval-4 hours, maximum interval -18 hours), hysterotomy was done in 1 patient, 2 patients required ICU admissions for medical conditions , 1 patient required blood transfusion, dilatation and evacuation was performed for 2 cases.

Conclusion: Combination of intracervical foleys and vaginal misoprostol is a safe and effective method of termination of pregnancy in mid-trimester and early third trimester.

Key words : Intracervical Foleys catheter, Misoprostol, Second trimester termination, Early third trimester termination, Induction to delivery interval (ID interval), D and E.

Introduction: Mid trimester termination of pregnancy has a global incidence of 10-15%^{1,2,3}. There is a gradual increase in incidence because of wide scale introduction of the prenatal screening programme⁴. and diagnosis of lethal fetal anomalies, mid trimester abortions are associated with three to five times higher risk of maternal morbidity and mortality than termination of pregnancy during first trimester⁵. Maternal mortality rate is 0.4/1 lakh abortions when done before 8 weeks but 10.4/1 lakh when it is done after 21 weeks⁶ hence, second trimester and early third trimester pregnancy termination is a challenging procedure.

Commonly used medical methods for second trimester pregnancy are, misoprostol alone, mifepristone followed by misoprostol. Mechanical methods such as introduction of intracervical foleys catheter, usage of osmotic dilators, surgical method like dilation and evacuation is of limited value after 12 weeks due to well formed fetal skeletal system, along with that complications like cervical trauma, uterine perforation are seen, hence are being replaced with medical and mechanical methods

Misoprostol usage is safe, effective, and easily available non-invasive and low-cost solution. At the same time, using

misoprostol alone as inducing agent requires higher dosage, and longer duration and side effects like pyrexia, chills and nausea at higher doses.

We used the combination of intracervical Foleys catheter and misoprostol to reduce the dose of misoprostol required and to decrease the induction to delivery interval.

Primary objective:- To know the effectiveness of combined usage of intracervical foley's catheter and Misoprostol for mid trimester and early third trimester termination.

Secondary objective : To know the safety, complications, and number of misoprostol doses used and requiring secondary procedure like D & E.

Methodology:

We conducted a retrospective study for 12 months from July 2022 to June 2023, where we enrolled selective patients with gestational age between 14 to 34 weeks. Here gestational age was calculated from the date of the first day of last menstrual period and confirmed by first trimester ultrasonography, in the obstetrics and gynecology department of Akash institute of medical sciences and research centre, Devanahalli, Bangalore rural. Sample size being 30, and informed consent was taken from all the 30 patients for their participation in the study. Clearance from the institutional ethical committee was taken before starting the study.

In this study we included early second trimester, indicative of lethal anomalies and IUFDs, late second trimester pregnancy and early third trimester pregnancy IUFDs and eclampsia patients, using a 14F foley's catheter distended with 30cc distilled water, traction applied to thigh and simultaneous usage of misoprostol vaginally. Patients received misoprostol 200mcg in the second trimester and 100mcg in the early third trimester at the time of intracervical foley's placement and continued 4th hourly till the intracervical foley's expulsion. Followed by foleys expulsion oxytocin augmentation used if required. We noted induction to intracervical foley's expulsion average 6 hours and induction to delivery interval average less than 12 hours. Patient followed up for further complications till discharge.

Results :

Total 30 participants were included in the study, of which mean age group is 24 years, between 20 to 25 years are 14 (46.6%), between 25 to 30 years are 10 (33.3%), 30 to 35 years are 6 (20%) (as depicted in table no 1) out of 30 women, 13 primigravida (43.3%) , 17 were Multigravida (56.6%) , out of 17 women,

11 women with previous LSCS (64.7%), 6 women were without previous LSCS (35.3%) (as depicted in table no 2) .

In our study out of 30 women, 10 cases were between 14 to 20 weeks (33.3%), 14 cases were 20 to 28 weeks (46.6%), 6 women were between 29 to 34 weeks (20%)(as depicted in table no 3).

Indication for termination of 2nd trimester pregnancy was majorly anomalous babies, indication of termination in early 3rd trimester being eclampsia and IUD. Total number of IUDs were 10 (33.3%), eclampsia cases were 6 (20%) and anomalous babies were 14 (46.6%)(as depicted in table no 4). Mean Induction to delivery interval was 12 hours, intracervical Foley's insertion to expulsion mean duration was 4 hours, intracervical foley's expulsion to delivery mean duration was 1 hour(as depicted in table no 5) . Complications such as number of patients requiring D and E was 2, blood transfusion was required in 1case due to pre existing anemia, ICU admissions were 2 due to pre existing medical disorders (as depicted in table no 6) . With combination usage of misoprostol with intracervical foleys, dosage of misoprostol required is drastically reduced (<300mcg).

TABLE NO 1 : Age distribution of participants

Age	No of cases
20 - 25 Y	14 (46.6%)
25 - 30 Y	10 (33.3%)
30 - 35 Y	6 (20%)

TABLE NO 2 : Obstetric score

Primigravida	13(43.3%)
Multigravida	17(56.6%)
With previous LSCS	11(36.6%)
Without previous LSCS	19(63.3%)

TABLE NO 3: Period of gestation during induction

Trimester	No. of cases
14-20 weeks	10(33.3%)
20-28weeks	14(46.6%)
29-34weeks	6(20%)

TABLE NO 4: Indications for induction

Indication	No. of cases
IUFD	10(33.3%)
Anomalous babies	14(46.6%)
Eclampsia	6(20%)

TABLE NO 5: Induction to delivery interval

ID interval	12hrs
Intracervical foleys insertion – expulsion	4hrs
Intracervical foleys expulsion- delivery	1hr

TABLE NO 6: Complications

Complications	No of cases
No. Of blood transfusions required	1
Required D& E	2
ICU Admissions for underlying medical disorder	2

TABLE NO 7: Misoprostol dosage

Misoprostol dosage	No. Of cases
100mcg	8
200mcg	15
>/= 300mcg	1

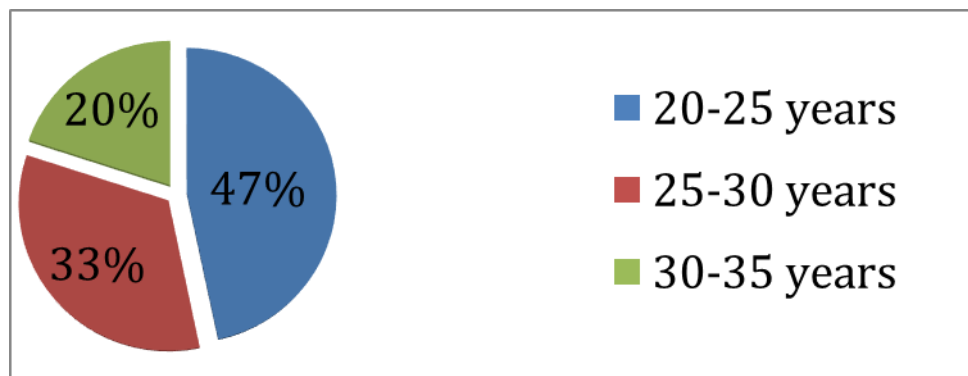


FIG 1 : Age group of participants

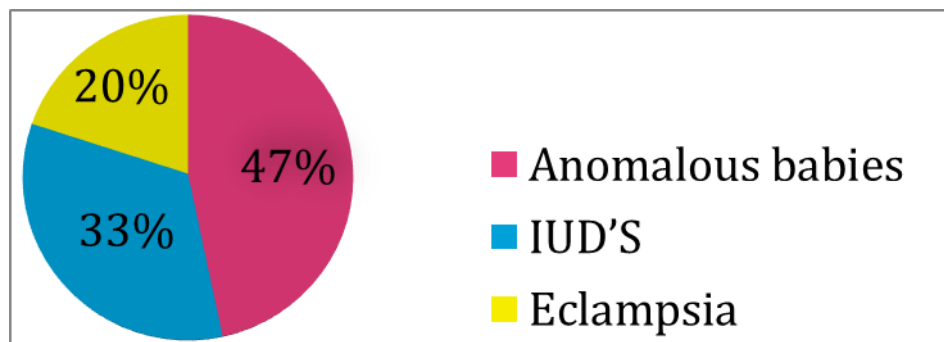


FIG 2 : Indications for termination of pregnancy

Discussion

Various agents have been used for second trimester abortions. Prostaglandins have been used to induce labor and are particularly useful where a woman's cervix is un-favourable, among which misoprostol is most popular.

Misoprostol alone as inducing agent requires higher dosage, and longer duration of Induction to delivery interval and complications like RPOCs. Side effects like Pyrexia, chills and Nausea are more seen with the high doses.

In order to shorten the induction to abortion interval and to minimize the side effects of repeated doses of misoprostol, we used intracervical foley's catheter in combination with vaginal misoprostol.

Age and parity of our study population was similar to most other studies

In our study mean induction to abortion time was 12 hours, in one of the similar studies by Bani-Irshaid et al study, they have compared misoprostol vs misoprostol with intracervical foleys catheter, average insertion-to-termination time was longer with intracervical foley's catheter that is 16.5 hours

In Gulec et al studies, due to usage of less misoprostol dosage (100 mcg) in previous LSCS cases, prolonged Induction to abortion interval (14 hours) was noted.

In our study success rate is 96.7%, 1 case was taken for hysterotomy due to deteriorating medical condition. In Swarn Kanta et al study the mean induction to abortion interval with misoprostol and intracervical foleys catheter was 8.5 ± 2.5 h, with success rate of 97% compared to misoprostol alone which was 15.75 ± 1.5 hrs with success rate of 94%.

In our study most common indication for termination is congenital anomalies (44%), followed by IUFDs (33%) whereas In swarn kant et al study, IUFD 62%, congenital anomalies 34%. In another study done by Mohamed Rezk et al, indications were IUFD constituting 58% which is more than our study, congenital anomalies 31% which is less than our study.

In our study complications like RPOC was 6%, which is comparable to other studies.

In Gulec et al study, reported complications such as uterine rupture 11% with 200 μ g misoprostol administration in patients who had 2 previous LSCS whereas our study, we did not observe any uterine ruptures, so with the study done by Mohamed Rezk et al.

In Mohamed Rezk et al observed cervical lacerations 6%, which is not observed in our study. 9 patients needed blood transfusion whereas in our study group only 1 case required blood transfusion for pre existing anemia , which was very less. Hence our study showed no noticeable morbidity or mortality with the combined usage of intra cervical foleys with misoprostol.

Conclusion

Patients who are undergoing termination in mid trimester and early 3rd trimester can effectively undergo cervical preparation with combined usage of Foleys catheter and Misoprostol.

This is an effective method with minimal dosage of misoprostol i.e <300 mcg, mean ID interval of 12 hours thus reducing the psychological burden & prolonged painful course of other procedures like Dialatation and evacuation. Careful selection of patients and effective monitoring results in less morbidity like infections, hysterotomy and scar ruptures, and no mortality.

Reference:

1. Lalit kumar S, Bygdeman M, Gemzell-Danielsson K. Midtrimester induced abortion: a review. Hum Reprod Update. 2007; 13(1): 37–52.
2. Gemzell-Danielsson K, Lalitkumar S. Second trimester medical abortion with mifepristone-misoprostol and misoprostol alone: a review of methods and management. Reprod Health Matters 2008; 16: 162-172.
3. Newmann SJ, Dalve-Endres A, Diedrich JT, et al. Cervical preparation for second trimester dilation and evacuation. Cochrane Database Syst Rev. 2010; (8): CD007310
4. Boyd PA, Tondi F, Hicks NR, Chamberlain PF. Autopsy after termination of pregnancy for fetal anomaly: retrospective cohort study. BMJ. 2004; 328: 137
5. Islam A., Abbasi A. and Sarwar I. (2005) Journal of Ayub Medical College, Abbottabad, 18(3), 35-39.

6. Ercan Ö, Köstü B, Özer A, Serin S, Bakacak M. Misoprostol versus Misoprostol and Foley catheter combination in 2nd trimester pregnancy terminations. *The Journal of Maternal-Fetal & Neonatal Medicine*. 2015 Nov 23;29(17):2810–2. doi:10.3109/14767058.2015.1105950
7. Comparison of intravaginal misoprostol alone and in combination with intracervical foley's catheter for termination of second trimester pregnancy at a tertiary care hospital Swarn Kanta¹, Pooja Sharma^{2*}, Sandeep Sharma³, Mandeep Sharma⁴ .
8. Rezk M, Abo-Elnasr M, Al-Halaby A. Combined use of intracervical Foley catheter and vaginal misoprostol for termination of second trimester pregnancy: A three-year observational study. *Clinical Obstetrics, Gynecology and Reproductive Medicine*. 2015;1(3):79–83. doi:10.15761/cogrm.1000121
9. Herabutya Y, Chanrachakul B, Punyavachira P (2001) Second trimester pregnancy termination: a comparison of 600 and 800 micrograms of intravaginal misoprostol. *J Obstet Gynaecol Res* 27: 125-128.
10. Kunwar S, Saha PK, Goel P, Huria A, Tandon R, et al. (2010) Second trimester pregnancy termination with 400 µg vaginal misoprostol: efficacy and safety. *Biosci Trends* 4: 351-354.
11. Tanha FD, Golgachi T, Niroomand N, Ghajarzadeh M, Nasr R (2013) Sublingual versus vaginal misoprostol for second trimester termination: a randomized clinical trial. *Arch Gynecol Obstet* 287: 65-69.
12. Jozwiak M, Bloemenkamp KW, Kelly AJ, Mol BW, Irion O, et al. (2012) Mechanical methods for induction of labour. *Cochrane Database Syst Rev* 3: CD001233.
13. Siddiqui S, Zuberi NF, Zafar A, Qureshi RN (2003) Increased risk of cervical canal infections with intracervical Foley catheter. *J Coll Physicians Surg Pak*13: 146-149.
14. Ghorab MN, El Helw BA. Second-trimester termination of pregnancy by extra-amniotic prostaglandin F2alpha or endocervical misoprostol. A comparative study. *Acta Obstet Gynecol Scand*1998; 77: 429–32.
15. Ashok PW, Templeton A, Wagaarachchi PT, Flett GM (2004) Midtrimester medical termination of pregnancy: a review of 1002 consecutive cases. *Contraception* 69: 51- 58.
16. Yapar EG, Senoz S, Urkutur M, et al: Second trimester pregnancy termination including fetal death: comparison of five different methods. *Eur J Obstet Gynecol Reprod Biol*. 1996; 69(2): 97–102