

Laser guided mucocele excision in lower lip: A case report

¹Dr. Rahath Firdose, ²Dr. Saniya Jamil, ³Dr. Pramod.V. Tatuskar, ⁴Dr. Shobha Prakash

Department of Periodontics College of Dental Sciences
Davangere, Karnataka -577004, India.

Abstract- Mucocele is defined as the accumulation of mucous secreted from salivary glands and their ducts in the oral cavity's subepithelial tissue. Mucoceles are painless, asymptomatic, benign swellings that have a relatively rapid onset and fluctuate in size. Mostly mucoceles are asymptomatic but sometimes can cause discomfort by interfering with speech, chewing, or swallowing. Management of mucoceles include surgical excision, marsupialisation, micro-marsupialization, cryosurgery, laser vaporization, and laser excision. The high-intensity diode laser is very helpful for excision of a mucocele in children because it is less invasive and safe. Removal of mucocele with the diode laser was effective in the case presented, resulting in bloodless operating field, minimal discomfort, minimal swelling and scarring and much less or no postsurgical pain.

Keywords: Mucocele, diode laser.

Introduction

The term "Mucocele" (from Latin terms mucus, or mucus, and coele or cavity) is used to define the accumulation of mucus secreted from mucus glands and their ducts in the oral cavity's subepithelial tissue. It may also appear in the appendix, gall bladder, paranasal sinuses, or lacrimal sac [1]. A mucocele is a mucus retention phenomenon of the major and, more commonly, the minor salivary glands. Mucocele is the most common salivary gland disorder and it is 2nd most common benign soft tissue tumor in the oral cavity. There are two types of mucocele usually seen - extravasation and retention. **Yamasoba et al.** highlight two crucial etiological factors in mucoceles: traumatism and obstruction of salivary gland ducts [3]. The incidence of mucoceles is generally high, 2.5 lesions per 1000 patients, frequently in the second decade of life and rarely among children under one of year of age. Most of the literature shows there is no difference between genders. There is no clinical difference between extravasation and retention mucoceles [2]. There is no clinical difference between extravasation and retention mucoceles. Usually mucoceles present a bluish, soft and transparent cystic swelling which frequently resolves spontaneously. The blue colour is caused by vascular congestion, and cyanosis of the tissue above and the accumulation of fluid below the tissue. Coloration can change depending on the size of the lesion, proximity to the surface and upper tissue elasticity [4]. Mucoceles are usually asymptomatic, though in some patients complain discomfort by interfering with speech, chewing, or swallowing.[2] Treatment options for mucoceles include surgical excision, marsupialisation, micromarsupialization, cryosurgery, laser vaporization, and laser excision [5].

Case report

A 12-year-old female patient presented with her parents at our department of periodontology complaining of asymptomatic swelling in the labial mucosa of her right side of lower lip. (Fig no – 1) The mother reported that it started 8 months back before and changed episodically in size and color. Patient gives a history of similar growth in the same region and excision of the growth was done 2 weeks back. They reported habit of lip biting. There was no history of any systemic disease.

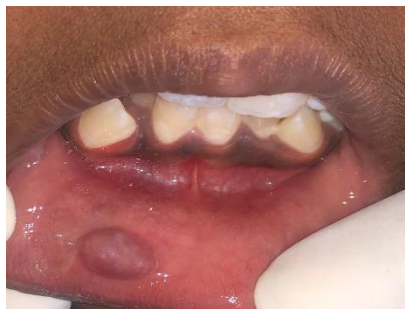

Fig 1: Asymptomatic swelling in lower lip

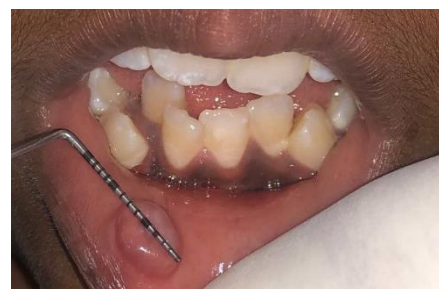

Fig 2: Local infiltration of LA at surgic

On clinical examination revealed an 6mm, round, solitary, fluctuant, sessile, palpable, non-tender, non-ulcerated swelling with no increase in temperature, was seen on the inner aspect of the lower lip. Swelling was about 2 mm below the vermilion border of the lower lip and extending inferiorly toward the lingual vestibule, measuring approximately 4-5 mm in diameter. (Fig no-2) No other oral anomalies were detected. Based on the history and clinical features a provisional diagnosis made that it can be a mucocele. But in differential diagnosis, it can be an Abscess, Mucocele, Lipoma, Fibroma, Tumours of minor salivary glands, and Hemangiomas. Management of mucocele surgical excision, marsupialization, micro marsupialization. cryosurgery. vaporization. laser excision. In this case mucocele excision was done by laser. Routine hematological examinations that including hemogram, bleeding and clotting time were found to be within normal physiological limits. Local infiltrative anesthesia was applied (2% lidocaine with epinephrine 1:80,000).

The anesthetic was not infiltrated directly into the lesion to avoid compromising the biopsy. The lip was everted with digital pressure to increase the lesion's prominence.

Removal of the lesion was performed using a diode laser at continuous mode in a contact technique with a power setting of 1.3W, wavelength 810nm, 300µm fiber. (Fig no – 3)

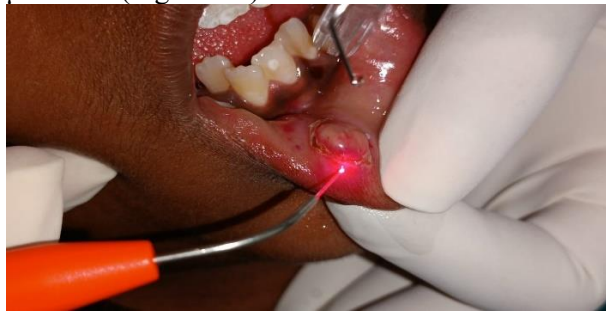

Fig 3: Diode laser machine power and wave length set for surgery

First a circular incision was made around the lesion to obtain a proper biopsy sample. (Fig no – 4) Dissection was performed to separate the lesion and associated minor salivary gland. (Fig no – 5)

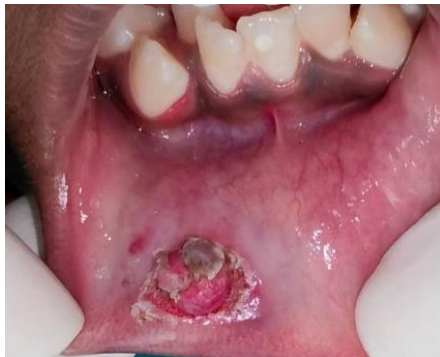

Fig 4: Circular incision done by diode laser

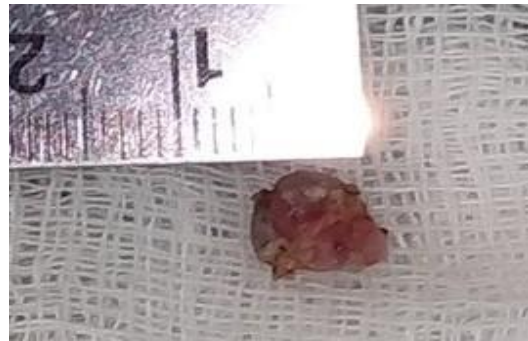

Fig 5: Separate the lesion (Exicion of the lesion)

The excised tissue was sent for biopsy at oral pathology department of (Fig no – 6).




Fig 6: Tissue send for biopsy

Post operative advice given to avoid spicy food, using Vitamin Capsule at surgical site and antiinflammatory & soothing ointment for quick healing. Post operative picture shows expected healing caused at surgical site. (Fig no – 7). After one month of post operative check up showed complete healing of surgical site. (Fig no – 8)

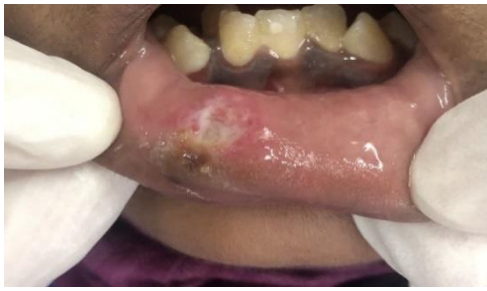

Fig 7: Follow-up after 7 days

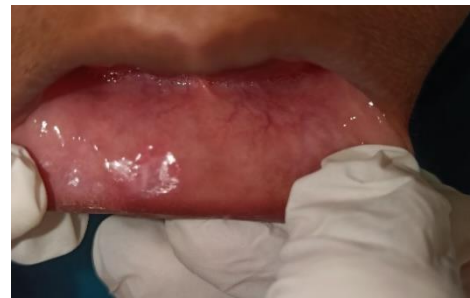

Fig 8: Follow-up after 1 month

In histopathology H & E stained section revealed overlying stratified squamous surface epithelium with underlying fibrovascular connective tissue. (Fig no – 9). The mucin pooled area surrounded by chronic inflammatory cells along with presence of foamy histiocytes is noted in the submucosal region. No malignant cells noted in the sections. Confirmed diagnosis made the mucous extravasation cyst.

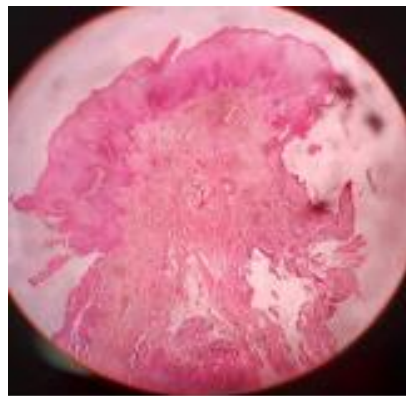


Fig 9: Tissue under microscope

Specificity, comfort, and cost over the conventional modalities, lasers are indicated for a wide variety of procedures in dental practice. There are two type of laser found hard and soft. Hard laser are Carbon dioxide (CO₂), Neodymium Yttrium Aluminum Garnet (Nd: YAG), and Er: YAG, whereas soft laser are semiconductor diode devices wave length of 810 nm to 980 nm.

In dentistry the soft laser is most commonly used [10]. Using of laser have several advantages like reduces surgical time, minimal bleeding, prompt hemostasis, no need of suture, reduces wound infection. For the high chances of recurrence, management of mucocele is a challenging task. Complete surgical removal with dissection of surrounding and contributing minor salivary gland acini proved to be successful with least recurrence. Diode lasers can be a choice on pediatric patients to remove mucoceles. Diode laser provides an effective, rapid, simple, bloodless and well-accepted procedure for treating mucocele in pediatric patients [6]. **MC Vitale et al.**, reported a case report of excision of mucocele using diode laser recommended that diode laser is an option for treating mucocele in lower lip in a 4 month baby [8]. **Besbes A et al.** 2020 reported diode laser is very helpful to treatment of mucocele as there is no need for suture, minimal trauma, scarring, post operative pain [9]. **Ramkumar S et al.** 2016, reported successful excision of mucocele with minimal trauma, and pain by diode laser [5].

CONCLUSION

Diode laser for the treatment of mucocele with a variety of beneficial effects such as minimal anaesthesia, less procedural timings, good surgical site visualization, hemostasis. Laser application makes it possible to reduce apprehension and fear in paediatric patients.

REFERENCES:

1. Case series Excision of Mucocele By Using Diode Laser: A Case Report Navya. L.V, Sabari. C, Seema.G3, Journal of Scientific Dentistry, 2016, 6(2).
2. Laller S, Saini RS, Malik M, Jain R. An Appraisal of Oral Mucous Extravasation cyst case with Mini Review. J Adv Med Dent Sci Res, 2014.
3. Yamasoba T, Tayama N, Syoji M, Fukuta M. Clinicostatistical study of lower lip mucoceles. Head & neck. 1990;12(4):316-20.
4. Ata-Ali J, Carrillo C, Bonet C, Balaguer J, Peñarrocha M, Peñarrocha M. Oral mucocele: review of the literature. J Clin Exp Dent. 2010;2(1):e18-21.

5. Case Report Excision of Mucocele Using Diode Laser in Lower Lip Subramaniam Ramkumar, Lakshmi Ramkumar, Narasimhan Malathi, and Ramalingam Suganya Case Reports in Dentistry. 2016. Article ID 1746316.
6. Case Report Treating Mucocele in Pediatric Patients Using a Diode Laser: Three Case Reports Sara M. Bagher, Ayman M. Sulimany, Martin Kaplan and Cheen Y. Loo Dent. J. 2018;6:13.
7. Laser-assisted Surgical Removal of Mucocele in a 12-Year-Old Female Patient: Preetam Shah, Priyam Rajesh Velani, Laxmi Lakade, Ajinkya A. Deshmukh Indian Journal of Oral Health and Research, 2017 July-Dec, 3(2).
8. Marina Consuelo Vitale, et al. Diode Laser-Assisted Surgical Therapy for Early Treatment of Oral Mucocele in a Newborn Patient: Case Report and Procedures Checklist; Case Report 2018. Article ID 3048429. <https://doi.org/10.1155/2018/3048429>
9. Amira Besbes, Yamina Elelmi, Faten Khanfir, Raja Belgacem, Hichem Ghedira. Recurrent Oral Mucocele Management with Diode Laser, Case Reports in Dentistry. 2020, 5, Article ID 8855759. <https://doi.org/10.1155/2020/8855759>
10. Sanjeev Kumar Verma, Sandhya Maheshwari, Raj Kumar Singh, Prabhat Kumar Chaudhari, Laser in dentistry; A innovative tool in modern dental practice; Natl J Maxillofac Surg. 2012 Jul-Dec;3(2):124-132. DOI: 10.4103/0975-5950.111342.