

COMPARITIVE STUDY BETWEEN NATAMYCIN AND NATAMYCIN WITH VORICONAZOLE IN TREATMENT OF FUNGAL CORNEAL ULCER

¹Dr.Mrudula Raj. Vanga, ²G. Jaya Sri Durga, ³G. Jyothirmayee

¹Associate Professor
Department of Pharmacy Practice
Sir C.R.R. Reddy College of Pharmaceutical Sciences
Eluru, Andhra Pradesh, INDIA.

Abstract- One of the sense organs Eye is connected to the mind and to interpret what we are seeing. View of eye depends upon the switch of mild. This light passes through the cornea to the lens. The cornea and the lens helps to awareness the light rays onto the lower back of the eye (retina). The cells inside the retina absorbs and light is converted to electro chemical impulses which are transferred alongside the optic nerve after which to the brain. The cornea consists of proteins and cells and not include blood vessels. The cornea is constituted of 5 layers: Epithelium, Bowman's layer, Stroma, Descemet's membrane, Endothelium..A corneal ulcer is an open sore located on cornea. Fungal corneal ulcer refers to an infective method of the cornea due to any of the a couple of pathological fungi capable of invading the ocular floor. In this study duration we've evaluated 96 sufferers on fungal corneal ulcer . The present examine shows efficacy between Natamycin and Natamycin with Voriconazole in fungal corneal ulcer sufferers. 96 patients with corneal ulcer and fungal elements visible on smear had been assessed eligibility at some point of the period from November 2021 to April 2022 and 16 patients were excluded. Among all of the patients, male are 50 and woman are 30 . Quantity of male patients given with single therapy are 28 and aggregate therapy are 22 range of female patients given with single drug therapy are 12 and combination therapy are 18.Overall wide variety of patient passed through surgical operation are 30. Among them single therapy taking people are 22 and combination therapy taking people are 8 . We've determined that people who are working in agriculture fields are more distinguished to fungal corneal ulcer and who take topical steroid eye drops has proven to growth size and depth of corneal ulcer. Diabetes is likewise one of the threat element in those patients because it delays the healing of ulcer. By way of looking at all of the outcomes 30% of the human beings in aggregate remedy were given healed in third visit whereas only 12.5% of people with single remedy. Only 5% of people took up to four weeks to remedy in combination therapy, while 17.5e% humans in single therapy..When compared with those who received Natamycin and Natamycin with Voriconazole – treated patients had an approximately first line improvement.

Keywords: Epithelium, electro chemical impulse , Fungal corneal ulcer , steroid eye drops, Diabetes.

INTRODUCTION:

The five senses include sight, sound, taste, hearing and touch. Sight, like the other senses is closely related to other parts of our anatomy. The eye is connected to the brain and dependent upon the brain to interpret what we see. View of eye depends upon the transfer of light. Light passes through the front of the eye (cornea) to the lens. The cornea and the lens help to focus the light rays onto the back of the eye (retina). The cells in the retina absorb and convert the light to electrochemical impulses which are transferred along the optic nerve and then to the brain.

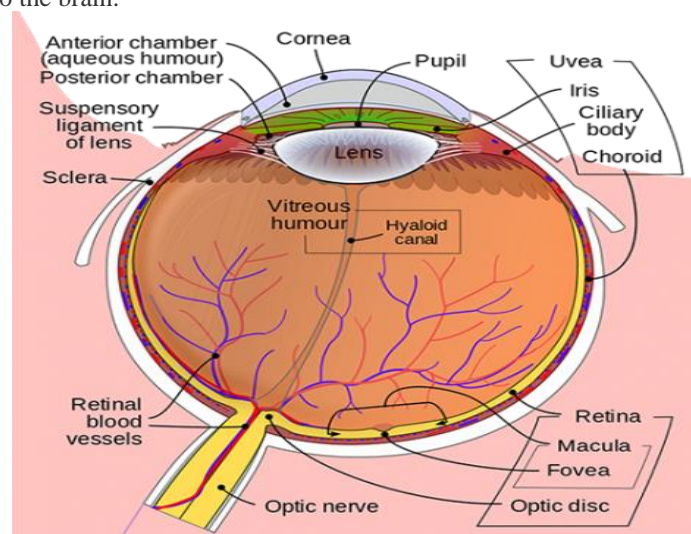


Fig No.1.1 Structure of an eye

Choroid: Layer containing blood vessels that lines the back of the eye and is located between the retina (the inner light-sensitive layer) and the sclera (the outer white eye wall). Ciliary Body which focuses the lens. Cornea which transmits and focuses light into the eye. Corrective laser surgery reshapes the cornea, changing the focus. Fovea provides the sharp vision. Iris: which helps regulate the amount of light entering the eye. Lens: Focuses light rays onto the retina. Macula, Optic Nerve, Pupil, Retina, Sclera, Vitreous Humor⁽¹⁾, Optic disc, Optic nerve, Rod cells, Cone cells⁽²⁾ are some of the functional parts of eye.

DIFFERENCE BETWEEN BACTERIAL, FUNGAL, VIRAL CORNEAL ULCER

	BACTERIAL	FUNGAL	VIRAL
Ulcer	Epithelial defect with large infiltrate and conjunctival infection	Grey or whitish stromal infiltrate with indistinct fluffy margins	Punctuate/ stellate pattern
	Anterior chamber reaction	Feathery branch like extensions	Linear branching ulcer with or without bundles
Corneal scraping	Gram stain, culture and sensitivity	10% KOH, giemsa stain stain	PCR ⁽⁷⁾

Table 1.1 Differences between bacterial, fungal and viral corneal ulcer.

FUNGAL CORNEAL ULCER:

Fungal keratitis or fungal corneal ulcer refers to an infective process of the cornea caused by any of the multiple pathological fungi capable of invading the ocular surface. It is most typically a slow, relentless disease that must be differentiated from other types of corneal conditions with similar presentation; especially its bacterial counterpart, which accounts for the majority of the microbial corneal infections.

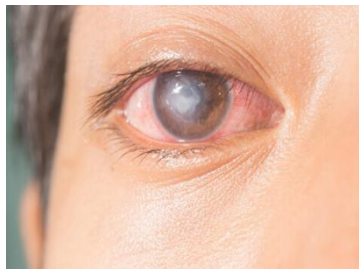


Figure 1.2 Fungal corneal ulcer

Etiology: The list covers many fungi including but not limited to yeasts of *Candida* sp., filamentous with septae such as *Aspergillus* sp., *Fusarium* sp., *Cladosporium*, sp., *Curvularia*, and non separated such as *Rhizopus*. Any agent capable of infecting humans is a potential infectious agent, especially if the host has a debilitating disease.⁽⁸⁾ Fungal keratitis has been reported to be caused by more than 70 different fungi, of which *Fusarium*, *Aspergillus* and *Candida* are responsible for 95% of cases⁽⁹⁾

Signs and symptoms: Edema and redness, Ulcer may be present, hypopyon which is mostly white fluffy in appearance leading to the destruction of the eye. The symptoms of fungal keratitis typically emerge over 5-10 days and present with a painful eye, blurred vision, and redness of eye, increased sensitivity to light and excessive tears or discharge -The symptoms are markedly less as compared to a similar bacterial ulcer. Symptoms may be noted to persist after contact lenses are removed, or following antibiotic treatment.⁽⁹⁾ Others include: Redness, Severe pain, The feeling that something is in your eyes, Tears, Pus or thick discharge from eye, Blurry vision, Pain when looking at bright lights, Swollen eyelids, A round white spot on cornea⁽⁶⁾.

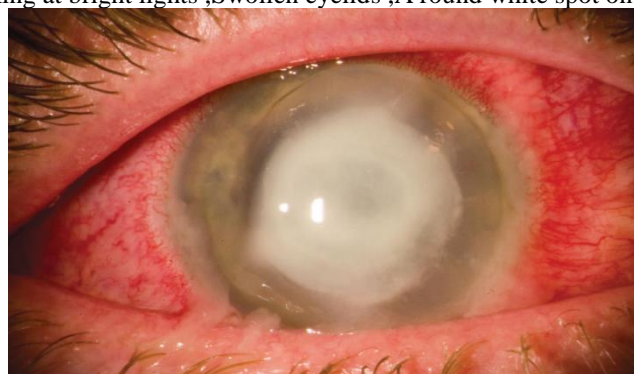

Fig 1.4 Redness in fungal corneal ulcer

Pathophysiology;

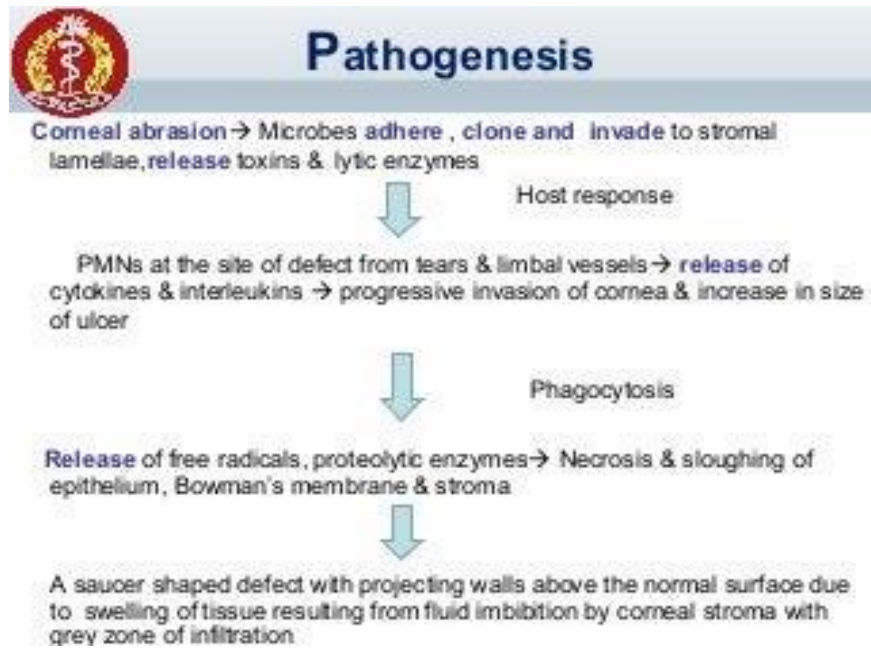


Fig 1.5 Pathophysiology of corneal ulcer.

Complications: Corneal perforation, Corneal melting, Corneal scarring Scleritis, Endophthalmitis, Panophthalmitis, Permanent blindness⁽¹¹⁾

Risk factors: Contact lens wearers, people who have or have had cold sores, chicken pox or shingles, people who use steroid eye drops, people with dry eye, people with eyelid disorders that prevent proper functioning of the eyelid, people who injure or burn their cornea⁽¹²⁾ Steroid eye drops, Disorders that cause dry eyes, Eyelid inflammation (blepharitis), Eyelashes that grow inward, Eyelids that turn inward, Conditions that affect your eyelid and keep it from closing all the way, like Bell's palsy, Chemical burns or other cornea injuries⁽⁶⁾ **Diagnosis:** Elevated edges, branching ulcers, feathery margins, rough texture, and satellite lesions are features suggestive of fungal keratitis, corneal scrapings by PCR and cultures⁽¹¹⁾

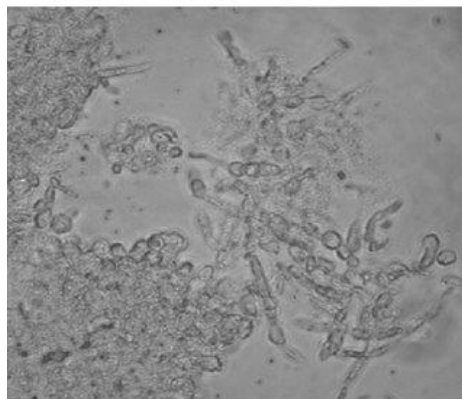


Fig 1.7 Fungal filaments in microscopic view

• **Management:** In general, management consists of medical therapy with the use of topical and/or systemic anti-fungal medications alone or in combination with surgical treatment. Topical antifungals, either commercially available or compounded from systemic preparation into eye-drops are the backbone for the management of fungal keratitis. In resistant cases, the addition of systemic antifungal have shown effectiveness. If those treatments fail, then conjunctival flaps, lamellar or penetrating keratoplasty might be needed. Medical follow up include All corneal infections should be followed daily until there is a marked improvement. Since fungal infections run a protracted course, their follow up is longer and after a few days the interval between evaluations increases according to its progress. Complete healing might take weeks and even months. The intraocular pressure should be closely monitored during the episode. It should be noted that epithelialization does not necessarily mean that the ulcer is healing. In fact it might hinder the penetration of the fungicide. Confocal microscopy might be an effective.

Surgery: Periodic debridement is commonly used in the management of fungal keratitis. The procedure removes necrotic tissue and diminishes the organism load but mostly it enhances the penetration of the drugs. It can be performed every 24 to 48 hours. If everything fails, a conjunctival flap might deter the infection. If there is no response, then a lamellar or penetrating keratoplasty could be needed. If there is a perforation, a patch graft or a therapeutic transplant should be performed. The infected cornea should

be sent for cultures and pathological evaluation. It is performed in the usual manner but it should extend about 1 to 1.5mm beyond the margins of the lesion.

Surgical follow up : Close follow up for at least 2 weeks with topical antimycotics is recommended. Systemic medication may be added as well. If the edges of the specimen are found by pathology to have organisms the use of topical and systemic antifungals should be extended.⁽⁸⁾

NATAMYCIN

Natamycin is a macrolide antifungal used to treat fungal infections of the eye.

Brand name : NATACYN

Natamycin is an anti fungal drug for topical ophthalmic administration. It is a tetraene polyene antibiotic derived from *Streptomyces natalensis*.

- It possesses in vitro activity against a variety of yeast and filamentous fungi, including *Candida*, *Aspergillus*, *Cephalosporium*, *Fusarium* and *Penicillium*.
- Although the activity against fungi is dose-related, natamycin is predominantly fungicidal. Natamycin is not effective in vitro against gram-positive or gram-negative bacteria.
- Topical administration appears to produce effective concentrations of natamycin within the corneal stroma but not in intraocular fluid.

MECHANISM OF ACTION: Like other polyene antibiotics, Natamycin inhibits fungal growth by binding to sterols. Specifically, Natamycin binds to ergosterol in the plasma membrane, preventing ergosterol-dependent fusion of vacuoles, as well as membrane fusion and fission. This differs from the mechanism of most other polyene antibiotics, which tend to work by altering fungal membrane permeability instead.⁽¹³⁾

SIDE EFFECTS: Mild eye irritation or discomfort (redness stinging or burning) ,Allergic reaction ,Change in vision ,Chest pain ,Corneal opacity ,Shortness of breath ,Eye pain ,Feeling like something is in the eye , weakness, and Tearing⁽¹⁴⁾.

VORICONAZOLE: Voriconazole is a triazole compound used to treat fungal infections.

PHARMACODYNAMICS: Voriconazole is a fungistatic triazole anti fungal used to treat infections by inhibiting fungal growth. It is known to cause hepatotoxic and photosensitivity reactions in some patients.

MECHANISM OF ACTION

Voriconazole is used to treat fungal infections caused by a variety of organisms but including *Aspergillus spp.* and *Candida spp.* Voriconazole is a triazole antifungal exhibiting fungistatic activity against fungal pathogen , binds to 14-alpha sterol demethylase, also known as CYP51, and inhibits the demethylation of lanosterol as part of the ergosterol synthesis pathway in yeast and other fungi. The lack of sufficient ergosterol disrupts fungal cell membrane function and limits fungal cell growth. With fungal growth limited, the host's immune system is able to clear the invading organism⁽¹⁵⁾.

SIDE EFFECTS: Black, tarry stools , Blistering, peeling, loosening of the skin ,Chest pain ,Chills ,Cough Diarrhea, , Difficulty seeing at night ,Fever ,Increased sensitivity of the eyes to sunlight ,Itching, rash ,Joint or muscle pain⁽¹⁶⁾

VITAMIN C: When vitamin C used is an adjunct to antibiotic therapy, systemic (oral or intravenous) vitamin C supplementation has a beneficial effect on the healing process of infected corneas and reduces the size of corneal opacity resulting from infectious keratitis⁽¹⁷⁾.

AIM AND OBJECTIVES

AIM: To compare efficacy between Natamycin and natamycin with voriconazole in treatment of fungal corneal ulcer.

OBJECTIVES:

1. To assess the response of the specific fungus to the standard treatment given to patients with fungal corneal ulcer.
2. To conduct a therapeutic exploratory clinical trial comparing clinical outcomes of treatment with topical natamycin Vs topical natamycin with topical voriconazole for fungal corneal ulcer.

PLAN OF WORK:

Literature review on current study



Protocol was designed and submitted to institutional review board/ethical committee for approval



Study was approved by IEC

Recruitment of patient is based on

<u>Inclusion criteria</u>	<u>Exclusion criteria</u>
Patients who are willing to participate in the study	Patients who do not visited hospital for regular check up
Evidence of filamentous fungi on smear	Pregnant/lactating women
Patients of all age groups	No evidence of filamentous fungi on smear

Patient demographic data was obtained from eligible patients in study



Details regarding the current therapy, their quality of life were obtained by patient interview and by observing case notes

Data processing and analysis was done by using statistical tools like

Patient therapy was monitored by using patient data collection form for present medication to obtain single and combination drug therapy to find out prescribing patterns and it was documented



Interpretation of results and documentation

- Patients who were coming to the hospital regarding the disease in outpatient department were screened based on the inclusion and exclusion criteria, subjects who met the inclusion criteria were enrolled for the study.
- Informed onset was obtained from the patient or attenders of patient.
- Details regarding the current therapy, their quality of life by using questionnaires were obtained by patient interview and by observing case notes.
- Patient therapy was monitored by using patient data collection form for present medication to obtain single and combination drug therapy to find out prescribing patterns and it was documented.

MATERIALS AND METHODS

- **STUDY SITE:** -
This study was conducted at Sankara Netra chikitsalaya, Eluru.
- **STUDY DESIGN:** -
The study was a prospective observational study.
- **SAMPLE SIZE:**
A total of 96 patients were participated in the study.
- **STUDY PERIOD:**
The study was carried out over a period of November to April.

SOURCE OF DATA AND MATERIALS:

Method of collection of data:

- Patient interview.
- Patient data collection form.

Method of collection of material

Patient case report and prescription.

STUDY CRITERIA

INCLUSION CRITERIA:

- Patients who are willing to participate in the study.
- Evidence of filamentous fungus on smear.
- Patients of all age groups.

EXCLUSION CRITERIA:

- Patients who do not visited hospital for regular sight checkup.
- Patients who are not willing to give the consent form.
- Pregnant/lactating women

Ethical Committee: An approval of ethical clearance has been obtained from Institutional Ethical Committee prior to the Initiation of study.

RESULTS:

During the six months of study period from November 2021 to April 2022 we have evaluated 80 patients with diagnosis of fungal corneal ulcer associated with eye disease in sankara netra chikitsalaya, Eluru. In this study factors like age, size of ulcer, depth of ulcer, gender, number of patients with and without diabetes, visual acuity, healing time are collected from 80 patients. They were analyzed and the following demographic details were obtained.

The study composed of n=80 fungal corneal ulcer disease patients. The various observations are made as follows.

1)Ulcer size factor of patients:

Table No. 6.1 factor- ulcer size

S.No	SIZE	COMBINATION	SINGLE
1	<2	8	18
2	2-5	16	19
3	>5	16	3

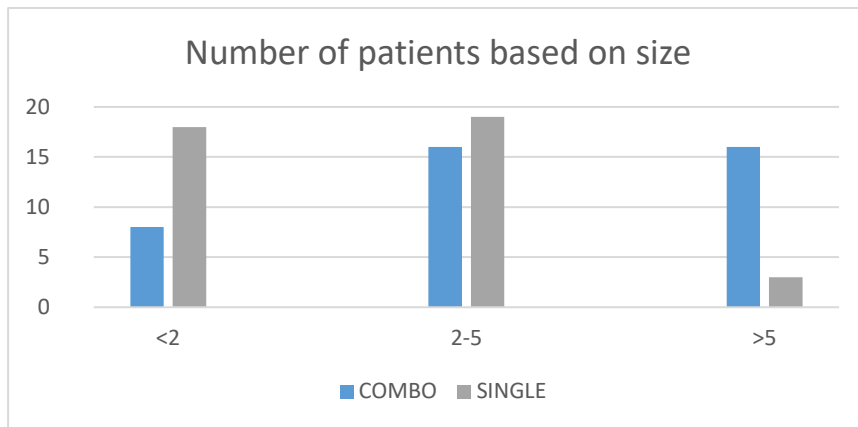


Fig 6.1 Patients based on size

Out of 80 patients with ulcer size of <2 were 26, patients with ulcer size 2-5 were 35 and patients with ulcer size of >5 were 19.

2)Factor- ulcer depth of patients:

Table No. 6.2 Factor- ulcer depth

S.NO	DEPTH	COMBINATION	SINGLE	TOTAL
1	<20	11	31	42
2	20-50	21	9	30
3	>50	8	0	8

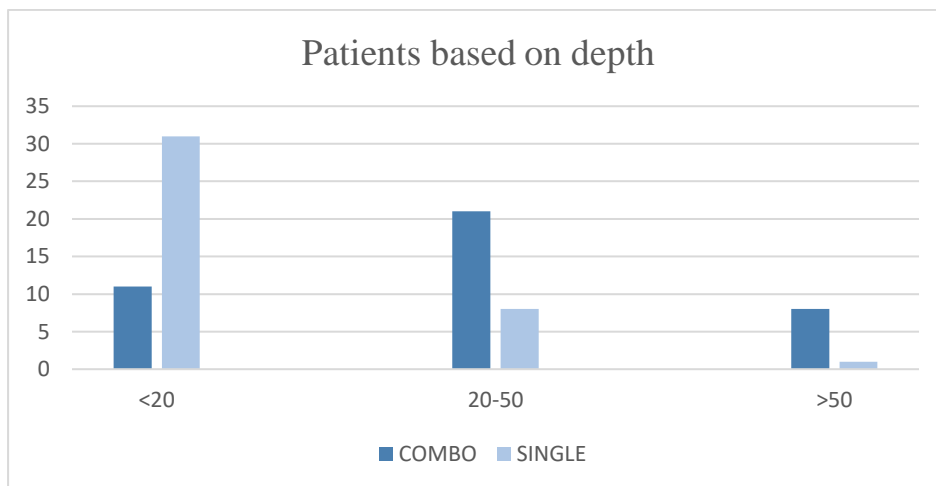


Fig 6.3 Patients based on depth

Out of 80 patients ulcer depth of <20 were 42patients, 20-50 were 30patients , >50 were 8 patients.

3)Gender:

Table No.6.3 Gender

S.NO	GENDER	COMBINATION	SINGLE	TOTAL
1	MALE	22	28	50
2	FEMALE	18	12	30

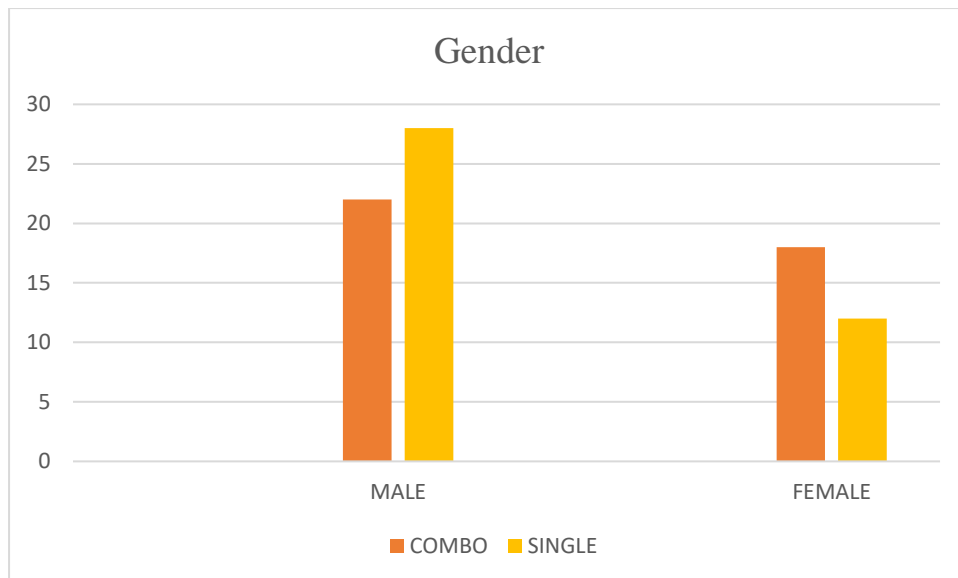


Fig 6.3 Factor - gender

Out of 80 patients males effected with fungal corneal ulcers were 50, females were 30.

4)Factor - diabetes

Table No.: 6.4 Factor- diabetes

S.No.	DIABETES	COMBINATION	SINGLE	TOTAL
1	DIABETIC	16	9	25
2	NON DIABETIC	24	31	55

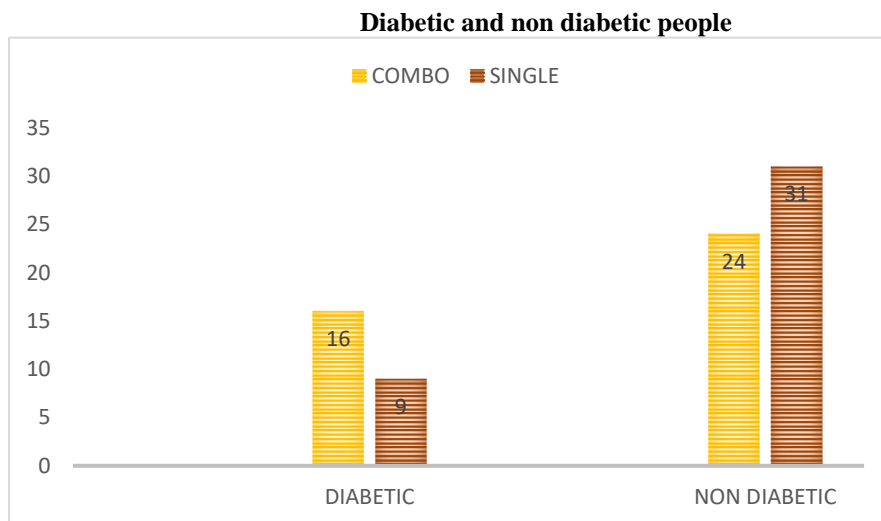


Fig 6.4 Diabetic and non diabetic people

With respect to disease state of patients were diagnosed with fungal corneal ulcer, out of 80 patients 25 patients were diabetic and in those treated with combination were 16 and with single drug were 9.

Non diabetic patients were 55 and in those treated with combination were 24 and with single drug were 31.

5)FACTOR- AGE:

Table No. 6.5 Factor- age

S.No	AGE	COMBINATION	SINGLE	TOTAL
1	15-20	1	1	2
2	21-30	4	4	8
3	31-40	11	10	21
4	41-50	13	16	29
5	51-60	9	7	16
6	>60	2	2	4

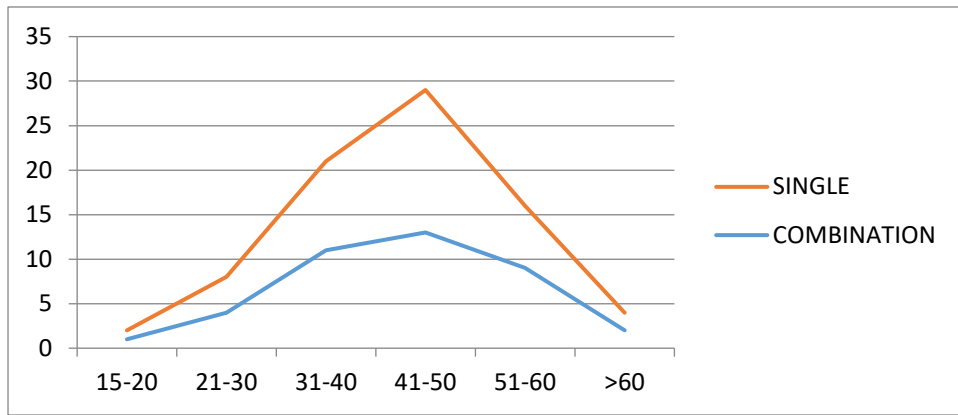


Fig 6.5 Age

- ✓ Out of 80 patients 2 were in between age of 15-20, 8 were in between age of 21-30.
- ✓ 21 patients were in between age of 31-40, 29 were in between age of 41-50.
- ✓ 16 patients were in between age of 51-60, 4 were in age of >60.

6)Factor – visual acuity:

Table No.6.6 Factor –visual acuity

S.No	VISUAL ACUITY	COMBINATION	SINGLE	TOTAL
1	VISION	20	21	41
2	HAND MOVEMENT POSITIVE	20	19	39

VISUAL ACUITY

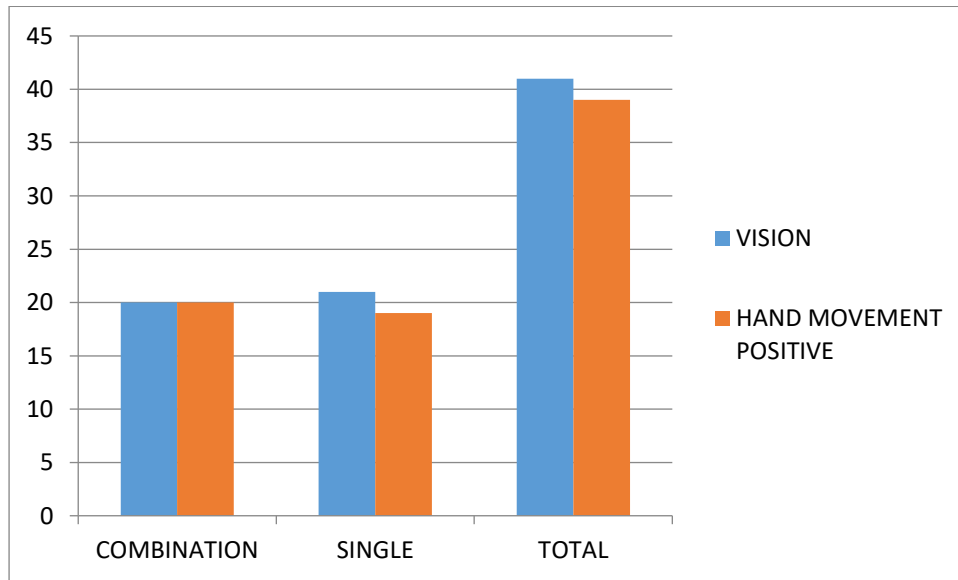


Fig 6.6 Factor – visual acuity

Out of 80 patients ,41 were with vision and 39 patients with hand movement positive.

7) Surgery:

Table No.: 6.7 Factor- Surgery

S.No	SURGERY	COMBINATION	SINGLE	TOTAL
1	UNDERWENT SURGERY	8	22	30
2	NO SURGERY	32	18	50

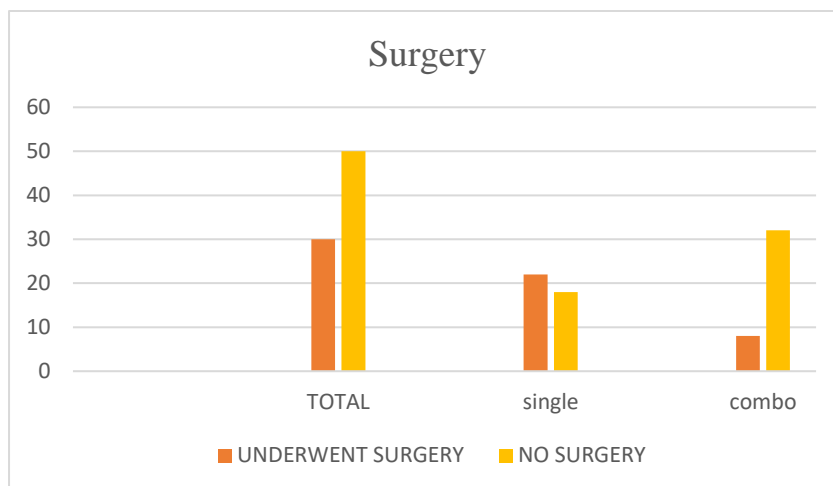


Fig 6.7 Results- number of people underwent surgery

Out of 80 patients, 22 patients underwent surgery in single therapy and 8 patients in combination therapy.

8)Drug action:

Table No. 6.8 Factor-drug action.

S.No	NO.OF WEEKS TAKEN FOR HEALING	COMBINATON	SINGLE	TOTAL
1	D1	0	0	0
2	D3	12	5	17
3	W1	10	5	15
4	W2	9	6	15
5	W3	6	15	21
6	W4	2	7	9
7	>W4	1	2	3

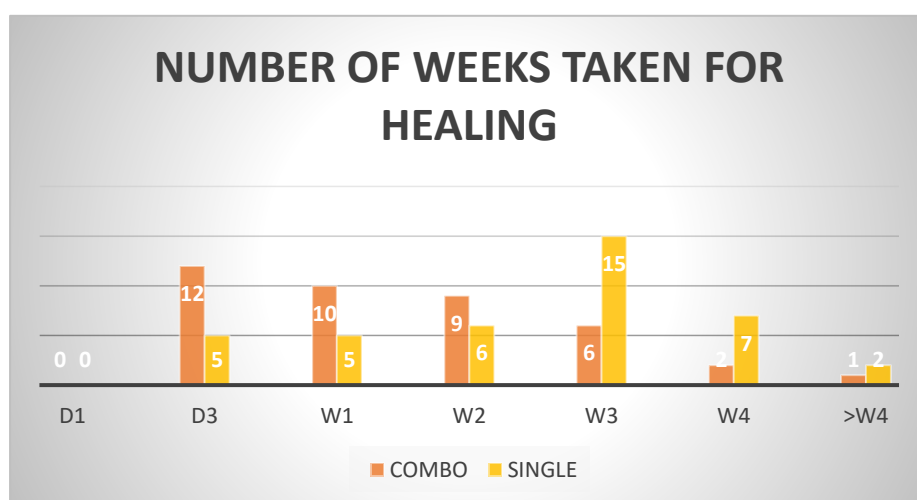


Fig 6.8 Factor- drug action

- In fungal corneal ulcer patients using combination 12 were healed in 3 days, 17 patients using single therapy were healed in 3 days
- 10 patients with combination therapy were healed in 1 week, 15 with single therapy were healed in 1 week

- 9 patients with combination therapy were healed in second week, 6 with single therapy were healed in second week.
- 6 patients with combination therapy were healed in third week, 15 with single therapy were healed in third week.
- 2 patients with combination therapy were healed in 4weeks, 7 with single therapy were healed in 4 weeks
- 1 patient with combination therapy were healed in more than four weeks,2 with single therapy were healed in more than 4 weeks.

ANOVA : SINGLE FACTOR

SUMMARY

<i>Groups</i>	<i>Count</i>	<i>Sum</i>	<i>Average</i>	<i>Variance</i>
Column 1	6	40	6.666667	19.86667
Column 2	6	40	6.666667	19.46667
Column 3	6	80	13.33333	40.66667

ANOVA

<i>Source of Variation</i>	<i>SS</i>	<i>df</i>	<i>MS</i>	<i>F</i>	<i>P-value</i>	<i>F crit</i>
Between Groups	177.7778	2	88.88889	3.333333	0.063423	2.695173
Within Groups	400	15	26.66667			
Total	577.7778	17				

DISCUSSION:

We have evaluated 96 patients for the study on fungal corneal ulcer. The present study shows efficacy between Natamycin and Natamycin with Voriconazole in fungal corneal ulcer patients. 96patients with corneal ulcer and fungal elements seen on smear were assessed eligibility during the period from November 2021 to April 2022 and 16 patients were excluded. The most common reasons for exclusion were patients who do not come to follow up on regular basis, overlying epithelial defect of <0.5mm, unwillingness to participate. It is a hospital based study all groups of patients are considered. In our study size of ulcer, depth of ulcer, number of patients who have undergone surgery, gender and age are taken into consideration. When we consider about presenting complaints of ulcer size out of 80 patients <2 patients were 26 (32.5%) , 2-5 were 35 (43.7%) and >5 were 19(23.7%). When we consider about presenting depth of ulcer 20% were 42 ,20-50 were 30 and >50% were 8.

Among all the patients male patients are 50 (62.5%) and female are 30 (37.5%). Number of male patients given with single therapy are 28 (35%) and combination therapy are 22 (27.5%). Number of female patients given with single therapy are 12 (15%) and combination therapy are 18 (22.5%). Total number of patient undergone surgery are 30 (37.5%). Among them single therapy taking people are 22 (27.5%) and combination therapy taking people are 8 (10%).

We also considered total number of weeks taken for patient for healing of ulcer as a major factor to conclude the study. Number of patients who got healed within 2 weeks when taken Natamycin are 6 (7.5%) , when taken combination are 9 (11.25%). Who got healed within 3 weeks when taken Natamycin are 15(18.75%) and when taken combination are 6 (7.5%). Who got healed within 4 weeks when taken Natamycin are 7 (8.75%) and when taken combination are 2 (2.5%). Who got healed within >4weeks when taken Natamycin are 2 (2.5%) and when taken combination are 1 (1.25%).

CONCLUSION:

Overall through this study we have observed that people who are working in agriculture fields are more prominent to fungal corneal ulcer and who take topical steroid eye drops has shown to increase size and depth of corneal ulcer. Diabetes is also one of the risk factor in these patients as it delays the healing of ulcer. By observing all the results 30% of the people in combination therapy got healed in 3rd visit whereas only 12.5% of people in single therapy. Only 5% of people took up to 4 weeks to cure in combination therapy, whereas 17.5% people in single therapy. When compared with those who received Natamycin and Natamycin with Voriconazole – treated patients had an approximately first line improvement.

PATIENT CONSENT FORM

Name of the patient:

Investigators name:

Name of the institution: C.R.REDDY PHARMACEUTICAL SCIENCES

Name of the research coordinators: 1. G. Jyothirmayee 2. G. Jaya Sri Durga

For the patient's care giver:

1. Exercising my free power of choice, hereby give my consent that myself Included as patient in the clinical study "COMPARITIVE STUDY BETWEEN NATAMYCIN AND NATAMYCIN WITH VORICONAZOLE IN FUNGAL CORNEAL ULCER, in Sankara netra chikitsalu, Eluru.

I agree to the following:

I understand that I will not be given any new study medication for participation in this study.

I have been informed to my satisfaction by the attending physician about the purpose of this study and study procedures.

I have been given a full explanation by supervising doctor of the nature, purpose, likely duration of the study and about what I will be expected to do. I have understood the information sheet given to me.

I am also aware of my right to opt myself out of the study at any time without giving any reason for doing so.

I also agree for the publication of my information.

Signature of the patient's care giver with date .

Signature of the witness* with date

I confirm that I have explained the nature and purpose of the above study.

Name of the investigators

Signature of the investigators.

G. Jyothirmayee

G. Jaya Sri Durga

COMPARITIVE STUDY BETWEEN NATAMYCIN AND NATAMYCIN WITH VORICONAZOLE IN FUNGAL CORNEAL ULCER

DATE:

PLACE:

SUBJECTIVE DATA:

Patient name:

Age/gender:

OP number:

Name of the consultant/physician:

Chief complaints:

Provisional diagnosis:

Past medical history:

Application of native medicine:

Application of steroid eye drops:

Allergies(food/drug/other):

Family history:

PERSONAL HISTORY :

Height :

weight:

BMI:

S.No	NAME OF THE PARAMETER	NORMAL VAUE	V1	V2	V3
1	Hb	M: 13.5-17.5 gm/dl F:12-15.5 gm/dl			
2	HbA1C	4-5.6%			
3	FBS	70-110 mg/dl			
4	POST PRANDIAL BLOOD GLUCOSE	<140 mg/dl			
5	RANDOM BLOOD GLUCOSE(RBS)	79-110 mg/dl			
6	VISUAL ACUITY	6/6			
7	Log MAR	0.0			
8	INFLTRATE SIZE	<2, 2-5, >5			
9	INFLITRATE DEPTH	<20, 20-50, >50			
10	CORNESL PERFORATION				
11	CORNEAL THINNING				
12	IOP	12-22 mm of hg			
13	KOH MOUNT				
14	FUNGAL CULTURE				

