

Wilms tumor in Children

¹D.K. Awasthi, ²Archana Dixit

^{1,2}Department of Chemistry

¹Sri J.N.M.PG College, Lucknow UP India

²Dayanand Girls PG Kanpur UP India

Abstract- Wilms tumor, also called nephroblastoma, is a malignant (cancerous) tumor originating in the cells of the kidney. It is the most common type of renal (kidney) cancer and accounts for about 6 percent of all childhood cancers. Wilms tumor is unrelated to adult kidney cancer. The tumor usually affects a single kidney, but approximately 5-10 percent of children with Wilms tumor have both kidneys involved. Wilms tumor occurs in children up to about age 8. About 75 percent of cases occur before age 5, and the average age of children diagnosed with Wilms tumor is 2 to 3 years old. For unknown reasons, Wilms tumor affects more black children than white children. Symptoms can vary, but many children have a swollen abdomen or large mass in the abdomen. Pain, blood in urine and unexplained fever are other signs of kidney tumors. Symptoms can vary, but many children have a swollen abdomen or large mass in the abdomen. Pain, blood in urine and unexplained fever are other signs of kidney tumors

Key words: Malignant, Blood, Pain, Kidney, tumor.

Description:

Kidney tumors are rare in children, with Wilms tumor (nephroblastoma), occurring most often. Most children with Wilms tumors can be cured, but with Wilms tumors and other rare kidney tumors, it is important to preserve as much of the child's renal function as possible. Because these cancers are so rare, children who have them should be cared for by a multidisciplinary team of pediatric specialists. Abdominal imaging with Ultrasonography, radiography and computed tomography(CT) can help detect kidney tumors. A complete blood count, liver or renal function tests and urinalysis can aid in differential diagnosis. Any child with a renal mass should be assessed for possible associated syndromes. Sometimes childhood kidney tumors do not cause signs and symptoms and the parent finds a mass in the abdomen by chance or the mass is found during a well-child health check-up. These and other signs and symptoms may be caused by kidney tumors or by other conditions. Check with your child's doctor if your child has any of the following:

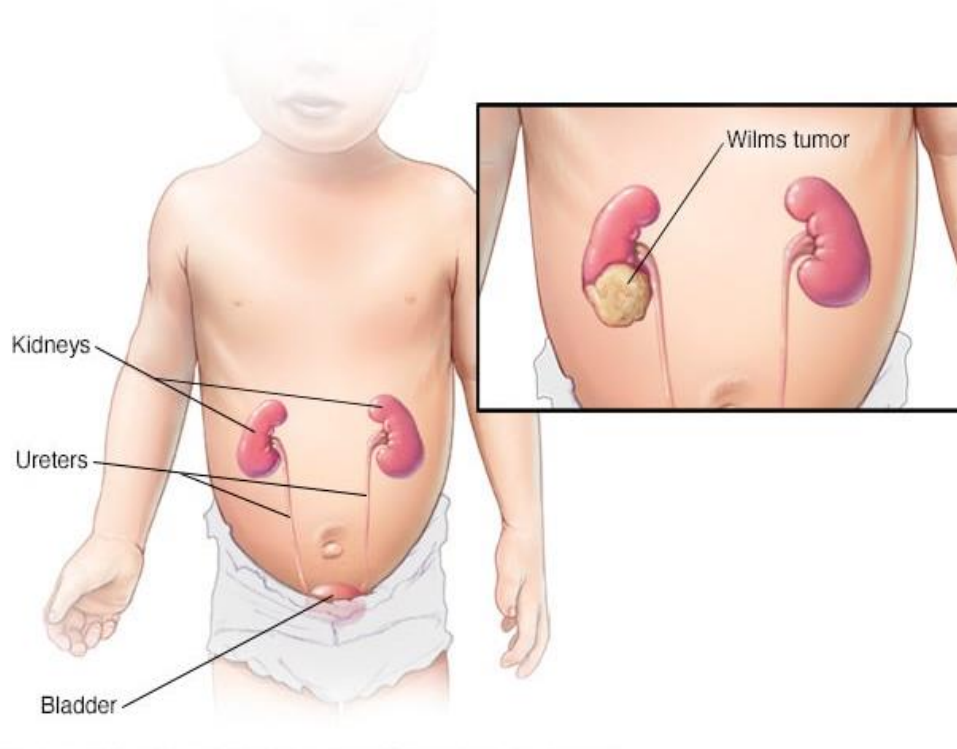


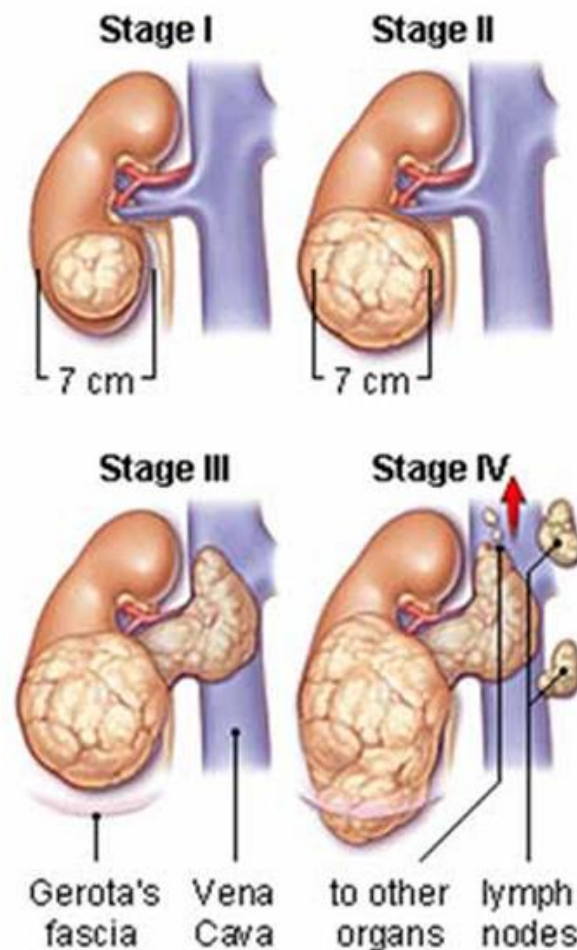
Fig-1 wilms tumor in child

- A lump, swelling, or pain in the abdomen.
- Blood in the urine.
- High blood pressure (headache, feeling very tired, chest pain, or trouble seeing or breathing).
- Hypercalcemia (loss of appetite, nausea and vomiting, weakness, or feeling very tired).

- Fever for no known reason.
- Loss of appetite.
- Weight loss for no known reason.

Wilms tumor that has spread to the lungs or liver may cause the following signs and symptoms:

- Cough.
- Blood in the sputum.



- Trouble breathing.
- Pain in the abdomen.

Stage I

The tumor was completely removed by surgery and all of the following are true:

- Cancer was found only in the kidney and did not spread to blood vessels of the kidney.
- The outer layer of the kidney did not break open.
- The tumor did not break open.
- A biopsy of the tumor was not done.
- No cancer cells are found at the edges of the area where the tumor was removed.

Stage II

Cancer has spread deeper into other parts of the kidney and to nearby blood vessels but was completely removed by surgery. No cancer cells are found at the edges of the area where the tumor was removed.

Stage III

Cancer remains in the abdomen after surgery to remove the tumor but no cancer remains in or on the blood vessel. Any 1 of the following may be true:

- Cancer has spread to lymph nodes in the abdomen or pelvis (the part of the body between the hips).
- Cancer has spread through the peritoneum (the layer of tissue that lines the abdominal cavity and covers most organs in the abdomen) or is found on the surface of the peritoneum.
- Cancer cells are found at the edges of the area where the tumor was removed.
- Cancer has spread to nearby tissues, where it cannot be completely removed by surgery.
- Cancer cells are found in the abdominal cavity (tumor cells spilled there before or during surgery).
- A biopsy of the tumor was done before surgery to remove it.
- The tumor was removed in more than 1 piece.

Stage IV

Cancer has spread through the blood to the lungs, liver, bone, or brain, or to lymph nodes outside of the abdomen and pelvis.

Stage V

Cancer cells are found in both kidneys when the disease is first diagnosed. The cancer in each kidney will be staged as I, II, III, or IV.

Recurrent

Recurrent disease means that the cancer has come back (recurred) after it has been treated. It may come back where it started or in another part of the body.

Favorable and Anaplastic Histology

In Wilms tumor, how the cancer cells look under a microscope (histology) is also very important for describing stage and determining treatment options. The cancer cells can be of favorable histology or anaplastic histology. Anaplastic means the cancer cells divide rapidly and look very different from normal cells. Anaplastic tumors may be focal (in one area) or diffuse (spread widely throughout an area).

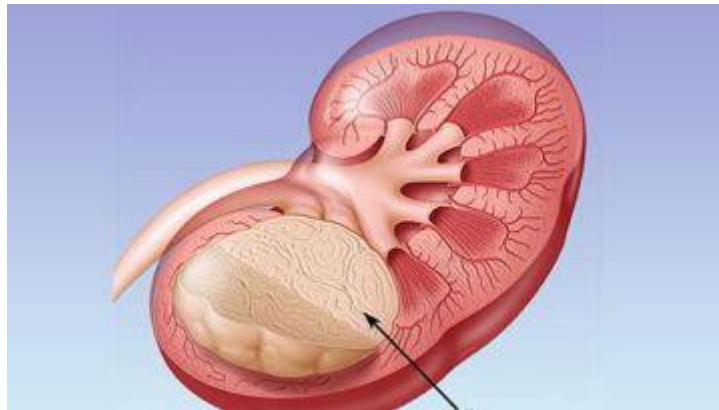


Fig -2 Wilms Tumor

Kidney tumors happen when cells in the kidneys grow out of control and form a lump (mass). The kidneys are a pair of organs near the bottom of the rib cage. Kidneys filter blood, removing waste and making pee (urine). Doctors often do not know exactly what causes these tumors to start and grow. Tumors can be cancerous (malignant) or noncancerous (benign). Kidney tumors are rare in children and teens. When a tumor grows in a child's kidney, it is likely to be cancerous. In children younger than 15 years, most kidney cancers are Wilms tumor. Usually it is diagnosed in children younger than 6 years old. The chance of having Wilms tumor is higher in children with certain genetic syndromes, such as WAGR syndrome, Frasier syndrome or Beckwith-Wiedemann syndrome. Children at higher risk should be screened regularly using ultrasound until they are 8 to 10 years old. Our Cancer Predisposition Clinic screens and cares for children born with a gene change that raises their cancer risk. If one kidney is affected (unilateral Wilms tumor), the age at diagnosis usually is 42-47 months. If both kidneys are affected (bilateral Wilms tumor), the age at diagnosis usually is 30-33 months. Most cases of Wilms tumor occur by chance (sporadic). They are the result of mutations in cells in the kidneys that usually occur after birth. In some cases, however, a genetic defect increases the risk of Wilms tumor.

Wilms tumor is characterized by:

- Abdominal swelling, often toward one side
- Fever
- Abdominal pain
- Constipation
- High blood pressure (hypertension)
- Large swollen veins across the abdomen
- Blood in the urine (hematuria)
- Fatigue
- Loss of appetite
- Weight loss
- Frequent urinary tract infections

Diagnosis **Abdominal ultrasound** This imaging test uses high-frequency sound waves and a computer to create pictures of internal organs, blood vessels and tissues. **Bone scan**, This imaging test, which is used to detect bone cancer, uses a special radioactive material that is injected into a vein. The substance collects in areas of diseased bone and is sensed by special cameras that pick up radioactivity. **Abdominal computerized tomography scan (CT)**, This imaging test uses X-rays and computer technology to produce detailed cross-sectional images (slices) of the body, including the bones, muscles, fat and organs. It can show a mass in the kidneys and whether the cancer has spread to other organs such as the lungs. **Chest x ray**, This imaging test produces images of the heart, lungs and bones. **Magnetic Resonance Imaging**, An MRI scan uses radio waves and strong magnets with computer technology. MRI shows more detailed images than CT and ultrasound and can help doctors see if the cancer has invaded one of the major blood vessels located near the kidney. **Blood and urine tests**, These laboratory tests help evaluate kidney and liver function. **Biopsy** A sample of tissue is removed and examined under a microscope; this helps confirm the diagnosis and aids in the treatment plan.

PROTON THERAPY

A more targeted form of radiation therapy, is offered at Children's Hospital of Philadelphia as a treatment option for Wilms tumor. This therapy is provided in partnership with Penn Medicine at the Roberts Proton Therapy Center. The overall cure rate for Wilms tumor is 85 percent. As with any cancer, however, prognosis and long-term survival can vary greatly from child to child. Prompt medical attention and aggressive therapy are important for the best prognosis. Continuous follow-up care is essential for a child diagnosed with Wilms tumor because side effects of radiation and chemotherapy may occur as well as second malignancy.

SURGICAL TREATMENT

Most children with Wilms tumor will require surgery as part of their treatment plan. At CHOP, your child will be treated by a multidisciplinary team including surgeons, oncologists, radiation oncologists and nurse practitioners, who work together to create a treatment plan specific to your child. You and your child will meet with the treatment team to ensure your family has an opportunity to build a trusting relationship with them. Scans are done prior to surgery to evaluate the extent of the tumor in the kidney and determine whether it has spread to other parts of the body, such as the lungs.

The affected kidney, either in whole or sometimes in part, may be surgically removed. If the whole kidney is removed, this is called a nephrectomy. In certain situations, CHOP surgeons can perform nephron sparing surgery, also known as partial nephrectomy, meaning that only part of the kidney is removed. NSS has been advocated in cases of bilateral Wilms tumor, for which the only alternative is bilateral nephrectomy, in cases of multifocal unilateral disease, or with Wilms tumor predisposition syndromes. NSS can be performed with a minimal complication rate and with no increase in the incidence of tumor recurrence and should be considered the standard modern approach to the management of selected cases of Wilms tumor.

Chemotherapy and Radiation for Wilms Tumor

Chemotherapy and sometimes radiation are used to kill remaining cancer cells.

The overall cure rate for Wilms tumor is 85%. As with any cancer, however, prognosis and long-term survival can vary greatly from child to child. Prompt medical attention and multidisciplinary therapy are important for the best prognosis. Regular follow-up care is essential for a child diagnosed with Wilms tumor to monitor for tumor recurrence and long-term side effects of radiation and chemotherapy.

Abdominal imaging with Ultrasonography, radiography and computed tomography(CT) can help detect kidney tumors. A complete blood count, liver or renal function tests and urinalysis can aid in differential diagnosis. Any child with a renal mass should be assessed for possible associated syndromes. Treatment may include:

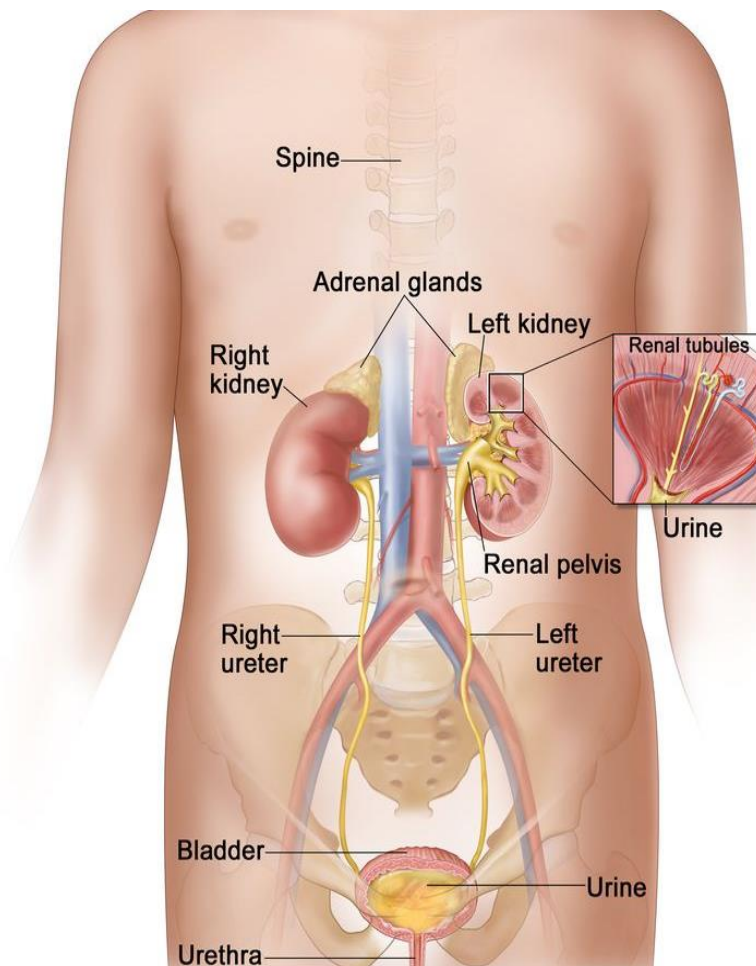
- Nephrectomy
- Radiation therapy
- Chemotherapy
- Biologic therapy as appropriate

Children with advanced disease may require high-dose chemotherapy. with a stem cell or kidney transplant.

Anything that increases the risk of getting a disease is called a risk factor. Having a risk factor does not mean that you will get cancer; not having risk factors doesn't mean that you will not get cancer. Talk to your child's doctor if you think your child may be at risk.

Wilms tumor may be part of a genetic syndrome that affects growth or development. A genetic syndrome is a set of signs and symptoms or conditions that occur together and is caused by certain changes in the genes. Certain conditions or environmental exposure can also increase a child's risk of developing Wilms tumor. The following have been linked to Wilms tumor:

- WAGRSYNDROME (Wilms tumor, aniridia, abnormal genitourinary system and mental disability).
- Denys-Dash Syndrome (abnormal genitourinary system).
- Frasier syndrome (abnormal genitourinary system).
- Beck with widemann syndrome (abnormally large growth of one or more body parts, large tongue, umbilical hernia at birth, and abnormal genitourinary system).
- A family history of Wilms tumor.
- Aniridia (part or all of the iris, the colored part of the eye, is missing).
- Isolated hemihyperplasia (abnormally large growth of one or more body parts).
- Urinary tract problems such as cryptorchidism or hypospadias.
- The child's mother being exposed to pesticides while she was pregnant



Anatomy of the female urinary system showing the kidneys, adrenal glands, ureters, bladder, and urethra. Urine is made in the renal tubules and collects in the renal pelvis of each kidney. The urine flows from the kidneys through the ureters to the bladder. The urine is stored in the bladder until it leaves the body through the urethra.

Ablation

Sometimes, heat and cold can destroy cancer cells. People who aren't candidates for surgery may benefit from cryoablation or radiofrequency ablation.

Cryoablation: During this procedure, your healthcare provider inserts a needle through your skin and into the kidney tumor. The cancer cells are then frozen with cold gas.

Radiofrequency ablation: Your healthcare provider inserts a needle through your skin and into the kidney tumor. Next, an electrical current is passed through the cancer cells to destroy them.

CONCLUSION:

The exact cause of kidney cancer is unknown, there isn't a way to prevent it altogether. However, you may be able to reduce your risk by not smoking and managing certain conditions like high blood pressure, diabetes and obesity. Your kidney cancer prognosis depends on the type and stage of cancer (whether it's just in your kidney or has spread to other places in your body). The chance of recovery also depends on your general state of health. kidney cancer is most treatable when found in its early stages. In general, if the cancer is detected early, before it breaks through the outer covering of your kidney, kidney cancer is often curable.

REFERENCES:

1. Renal cell carcinoma: ESMO Clinical Practice Guidelines for diagnosis, treatment and follow-upB Escudier and othersAnnals of Oncology, 2019. Volume 30, pages 706 to 720
2. Renal Cell carcinoma European Association of Urology website, accessed February 2020
3. Cancer and its management (7th edition)J Tobias and D HochhauserWiley-Blackwell, 2015
4. AJCC Cancer Staging Manual Eighth EditionAmerican Joint Committee on Cancer, Springer, 2017
5. Boorjian SA, Raman JD, Barocas DA. Evaluation and management of hematuria. In: Partin AW, Domochoowski RR, Kavoussi LR, Peters CA, eds. Campbell-Walsh-Wein Urology. 12th ed. Philadelphia, PA: Elsevier; 2021:chap 16.
6. Brown DD, Reidy KJ. Approach to the child with hematuria. Pediatr Clin North Am. 2019;66(1):15-30. PMID: 30454740 pubmed.ncbi.nlm.nih.gov/30454740/.
7. Elsamra SE. Evaluation of the urologic patient: history and physical examination. In: Partin AW, Domochoowski RR, Kavoussi LR, Peters CA, eds. Campbell-Walsh-Wein Urology. 12th ed. Philadelphia, PA: Elsevier; 2021:chap 1.

8. Landry DW, Bazari H. Approach to the patient with renal disease. In: Goldman L, Schafer AI, eds. *Goldman-Cecil Medicine*. 26th ed. Philadelphia, PA: Elsevier; 2020:chap 106.
9. Kelly L. Stratton, MD, FACS, Associate Professor, Department of Urology, University of Oklahoma Health Sciences Center, Oklahoma City, OK. Also reviewed by David Zieve, MD, MHA, Medical Director, Brenda Conaway, Editorial Director, and the A.D.A.M. Editorial team.
10. Motzer, Robert J.; Jonasch, Eric; Agarwal, Neeraj; Bhayani, Sam; Bro, William P.; Chang, Sam S.; Toni Choueiri; Costello, Brian A.; Derweesh, Ithaar H.; Fishman, Mayer; Gallagher, Thomas H. (2017-06-01). "Kidney Cancer, Version 2.2017, NCCN Clinical Practice Guidelines in Oncology". *Journal of the National Comprehensive Cancer Network*. **15** (6): 804–834. doi:10.6004/jnccn.2017.0100. ISSN 1540-1405. PMID 28596261.
11. Silverman, Stuart G.; Israel, Gary M.; Herts, Brian R.; Richie, Jerome P. (October 2008). "Management of the incidental renal mass". *Radiology*. **249** (1): 16–31. doi:10.1148/radiol.2491070783. ISSN 1527-1315. PMID 18796665. S2CID 23327389.
12. "Cancer | Definition of Cancer by Lexico". *Lexico Dictionaries | English*. Archived from the original on November 12, 2019. Retrieved 2019-11-12.
13. Israel, Gary M.; Bosniak, Morton A. (2005). "How I Do It: Evaluating Renal Masses". *Radiology*. **236** (2): 441–450. doi:10.1148/radiol.2362040218. ISSN 0033-8419. PMID 16040900. S2CID 1916092.
14. Silverman, Stuart G.; Pedrosa, Ivan; Ellis, James H.; Hindman, Nicole M.; Schieda, Nicola; Smith, Andrew D.; Remer, Erick M.; Shinagare, Atul B.; Curci, Nicole E.; Raman, Steven S.; Wells, Shane A. (2019-06-18). "Bosniak Classification of Cystic Renal Masses, Version 2019: An Update Proposal and Needs Assessment". *Radiology*. **292** (2): 475–488. doi:10.1148/radiol.2019182646. ISSN 0033-8419. PMC 6677285. PMID 31210616.
15. "Kidney Cancer | CDC". *www.cdc.gov*. 2019-07-09. Retrieved 2019-11-12.
16. "Renal Cell Cancer Treatment (PDQ®)–Patient Version". National Cancer Institute. 2004-02-20. Retrieved 2019-11-12.