

# Full Mouth Rehabilitation of Completely Edentulous Patient Using All On 4 Technique- A Case Report

<sup>1</sup>Swathi Reddy, <sup>2</sup>Satheesh Simha Reddy, <sup>3</sup>Santoshi kumari. V, <sup>4</sup>Riyaz Basha Shaik, <sup>5</sup>Nirban Mitra

<sup>1</sup>Post graduate, <sup>2,3,4</sup>Professors, <sup>5</sup>Reader  
1Department of Oral and Maxillofacial Prosthodontics and Implantology,  
<sup>1</sup>Malla Reddy Institute of Dental Sciences, Hyderabad, India.

**Abstract**— The All-on-Four treatment concept provides patients with a fixed prosthesis supported by 4 implants. Issues like minimal bone volume, poor bone quality, and the requirement for bone-grafting procedures before implant placement produce some challenging conditions in the completely edentulous jaw as well as in the post extraction patient. In such compromised situations All on four technique has proven to be successful. This article reviews the All-on-4 concept and its prosthodontic aspects.

**Index Terms**— All on four, Full mouth rehabilitation, Surgical Guides, Dual Scan technique

## I. INTRODUCTION

After losing a tooth, the alveolar ridge frequently experiences severe atrophy, which gets worse over time in the edentulous mandible. Complete dentures, removable implant-retained prostheses, and fixed implant-supported prostheses are a few prosthetic treatment choices for this circumstance. Implant retained or fixed implant-supported prostheses, in contrast to removable prostheses, offer a greater level of patient satisfaction. (1)

In recent years, the practice paradigm has changed to focus on delivering the most satisfying patient-centered treatment results while minimizing treatment costs and patient morbidity. The "All-on-Four" treatment concept is an effort to achieve these goals by offering edentulous patients a comparatively simple, predictable treatment option with a good quality of life outcome. (2,3)

Angled implants (tilting of implants) are a well-documented alternative for maximizing the use of pre-existing bone, with no evident clinically significant difference in success rates compared to axially placed implants.1

The "All-on-Four" concept is based on the placement of four implants (two axial and two tilted implants) in the anterior part of fully edentulous jaws to support a provisional, fixed, and immediately loaded full-arch prosthesis. Combining tilted and straight implants for supporting fixed prostheses can be considered a viable treatment modality resulting in a simpler and less time-consuming procedure, in significantly less morbidity, in decreased financial costs and a more comfortable postsurgical period for the patients (3)

## II. CASE REPORT

A 48-year-old female patient reported to the Department of Oral and Maxillofacial Prosthodontics and Implantology with the chief complaint of completely missing upper and lower teeth in the past 10 months. History revealed that patient underwent extractions of most of the teeth 10 months ago due to mobility. Past dental history revealed no bleeding abnormalities or any uneventful healing. Past medical history was also uneventful. Patient was explained about the various treatment options for rehabilitation and was motivated for implant supported fixed prosthesis. On radiographic examination, CBCT revealed atrophy in the posterior maxillae region on both the sides and adequate amount of bone in the premaxilla region and anterior to the maxillary sinus region. Adequate amount of bone was available in the mandible (Fig1). Blood investigations revealed normal bleeding time and clotting time.

All on four implant treatment plan was fabricated and explained to the patient. It included 3 phases:

- 1.) Presurgical phase
- 2.) Surgical phase
- 3.) Prosthetic phase

### PRESURGICAL PHASE:

Diagnostic impressions were made using impression compound and cast was poured using type II gypsum material. Special trays were fabricated using autopolymerising resin and border molding was done using low fusing impression compound. Secondary impressions were made using zinc oxide eugenol paste and casts were poured using type III gypsum material. Denture bases were fabricated on the retrieved casts and occlusal rims were made. Jaw relations were recorded, and jet bite material was used to seal the maxillary and mandibular occlusal rims in the centric relation recorded by the nick and notch technique.

A dual scan technique was used to fabricate a surgical guide. On the denture baseplate of the sealed occlusal rims radio-opaque markers were placed using flowable composite and a CBCT is taken for it. The same rims with the composite markers were placed intraorally and another CBCT was taken (Fig 2). A surgical guide was fabricated by overlapping these 2 CBCT files.

### SURGICAL PHASE:

Antibiotic prophylaxis (Cap.amoxicillin 1g) was administered before surgery and for 3 days postoperatively. Oral rinses were performed 30mins before the surgical procedure using 0.2% chlorhexidine. The surgery was performed under local anesthesia using

2% lignocaine. The maxillary guide was placed in position and stabilized by making osteotomy via the anchor pin holes and the anchor pins are secured in position. Similarly, mandibular surgical guide is placed and stabilized (Fig 3). For the maxillary arch, 3.75\*11 mm implants in the anterior region and the tilted implants of 4.2\*10 mm were placed using sequential drilling at 800-1000rpm. For the mandibular arch, the anterior implants of 3.75\*13 mm and tilted implants of 4.2\*13 mm were placed using sequential drilling 1000-1200 rpm (Fig 4). The primary stability was adequate with torque around 40 Ncm for all the implants. After implant placement multiunit abutments are placed with the torque of 25Ncm on the implants for a proper gingival contour to form. (Fig 5)

### PROSTHETIC PHASE

Patient is recalled after 3 months and osseointegration of the implants is evaluated radiographically. Intraoral scanning was done by attaching the scan bodies on top of the multiunit abutments and planned for screw retained DMLS prosthesis. Cobalt chromium metal framework was fabricated and tried in patient's mouth and evaluated for the vertical dimension at rest, vertical dimension at occlusion, amount of freeway space available, midline, aesthetics, and lip support. (fig:6) Interocclusal record was made in patient's mouth at the desired vertical dimension. Ceramic build up was carried out and the bisque trial was done to check if any occlusal corrections are required. After glazing the prosthesis was secured using the prosthetic screws with a temporary cement. A mutually protected occlusal scheme was followed. Patient was recalled after 24 hours and evaluated for any screw loosening or any prosthesis fit issues. Then the screws were given a final torque of around 25Ncm according to the manufacturer's instructions and the access holes are closed using the PTFE (polytetrafluoroethylene) tape and the composite material on top of it. The patient was instructed to regularly perform oral hygiene measurements including the use of interdental brush and floss. Patient was instructed to return for regular follow ups for every 3 months in the first year and then for every 6 months.

### DISCUSSION:

Edentulism, which can be caused by a variety of conditions including poor oral hygiene, dental caries, and periodontal disease, is a condition that frequently affects senior people. As a result of a final non-restorable dentition, some individuals may experience edentulism. There is evidence that the edentulous state has a detrimental effect on dental health-related quality of life. Due to a rise in the population's life expectancy and the need to create prostheses that can replace missing natural teeth and provide optimum satisfaction and better quality of life, clinicians are increasingly required to provide solutions to this population.

Conventional dentures have traditionally been used as a therapy for edentulism. The most frequent causes of patient dissatisfaction with dentures are pain, sore spots, poor denture stability, eating challenges, and an absence of or compromised retention ability. Many patients with complete dentures express dissatisfaction with their masticatory function, loss of function, decreased tongue motor control, decreased bite power, and reduced oral sensory function(3,5). When compared to conventional dentures, prostheses supported by Osseo integrated dental implants greatly improved the quality of life for edentulous patients, according to a review of the literature (5,6).

Dental prostheses are typically positioned vertically. However, issues like minimal bone volume, poor bone quality, and the requirement for bone-grafting procedures before implant placement produce some challenging conditions in the completely edentulous jaw as well as in the post extraction patient. Implants may benefit from being tilted distally in these circumstances, as has been proven. Tilting protects important anatomical structures and enables the placement of longer implants with strong cortical anchorage in ideal locations for prosthesis support (7).

The present treatment concept uses the load-bearing capacity of the maxillary bone in a favorable way. Owing to the freedom of tilting, the implants can be anchored in dense bone structures (anterior bone with higher density) and well spread anteriorly-posteriorly, giving an effective prosthetic base. By reducing the number of implants to four, each implant can be placed without coming into conflict with adjacent implants. This treatment approach, using tilting and few implants rather than inserting several implants competing for space, has demonstrated good results in a previous study with delayed loading (3,7,8).

The "All- on-Four" treatment concept is an attempt to reach these objectives by providing relatively straight forward, predictable treatment option to rehabilitate edentulous patients with a high outcome of quality of life.

Malo et al. (2011) described the protocol for the insertion of implants following standard procedures, except that under-preparation was used to achieve an insertion torque of at least 35 Ncm before final seating of the implant. The authors showed this to be typically done by full drill depth with a 2-mm twist drill followed by step drills of 2.4/2.8 mm and 3.2/3.6 mm (depending on bone density). In cases of high bone density, 3.8/4.2 mm step drills were used only in cortical bone. The implant neck was aimed to be positioned at bone level, and bi-cortical anchorage was established whenever possible (3.)

### III. CONCLUSION

Earlier the placement of dental implant in severely resorbed ridges of maxilla and mandible shows little success rate. But with the concept of All on Four the success rate is quite higher, while promising a treatment method of choice in severely compromised alveolar ridge cases.

However, nowadays the trend is to minimize the patient morbidity. In this sense, some authors have introduced the concept of flapless surgery using prefabricated and customized guides based on stereolitho-graphic casts, to enhance accuracy during surgery and safely avoid the need for critical anatomical repairs.

### REFERENCES:

- [1] Patzelt, S. B. M., Bahat, O., Reynolds, M. A., & Strub, J. R. (2013). The All-on-Four Treatment Concept: A Systematic Review. *Clinical Implant Dentistry and Related Research*, 16(6), 836–855

- [2]. Soto-Penaloza, D., Zaragoza-Alonso, R., Penarrocha-Diago, M., & Penarrocha-Diago, M. (2017). The all-on-four treatment concept: Systematic review. *Journal of Clinical and Experimental Dentistry*, 0–0.
- [3]. Malo´ P, Rangert B, Nobre M. All-on-4 immediate- function concept with Bra°nemark system implants for completely edentulous maxillae: a 1-year retrospective clinical study. *Clin Implant Dent Relat Res*. 2005;7(suppl 1):S88–S94.
- [4]. Ben Hadj Hassine M, Bucci P, Gasparro R, Di Lauro AE, Sammartino G. Safe approach in "All-on-four" technique: a case report. *Ann Stomatol (Roma)*. 2015 Feb 9;5(4):142-5. PMID: 25774250; PMCID: PMC4333602.
- [5]. Babbush, C. A., Kutsko, G. T., & Brokloff, J. (2011). The All-on-Four Immediate Function Treatment Concept With NobelActive Implants: A Retrospective Study. *Journal of Oral Implantology*, 37(4), 431–445.
- [6]. Singh, Ramandeep, et al. 'Concept of All on Four for Dental Implants: A Review'. *IP International Journal of Maxillofacial Imaging*, vol. 6, no. 4, Jan. 2021, pp. 93–96.
- [7]. Malo P, Lopez I, Nobre M. The All on Four concept. In: Babbush C, Hahn J, Krauser J, eds. *Dental Implants: The Art and Science*. 2nd ed. St Louis, Mo:Saunders Elsevier; 2010:435.
- [8]. Albrektsson T, Zarb G, Worthington P, Eriksson AR. The long-term efficacy of currently used dental implants: a review and proposed criteria of success. *Int J Oral Maxillofac Implants*. 1986;1:11–25
- [9]. Guilherme Carvalho Silva, et al. Stress patterns on implants in prostheses supported by four or six implants. A three dimensional finite element analysis. *Int J Oral Maxillofac Implants*. 2010;25:239-46.
- [10]. Krekmanov L, et al. Tilting of posterior mandibular and maxillary implants of prosthesis support. *Int J Oral maxillofacial implants*.2000;15:405-14

#### FIGURES:

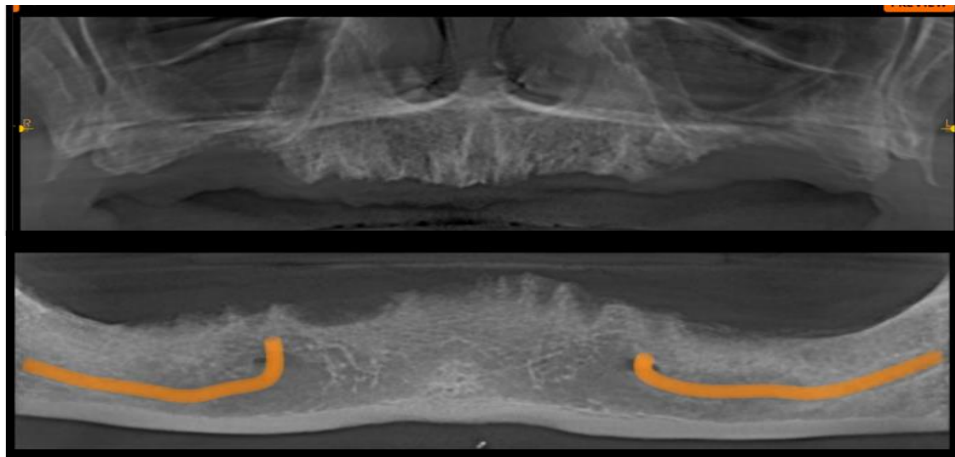


Figure 1: Radiographic image showing the amount of bone available in maxillae and mandible.

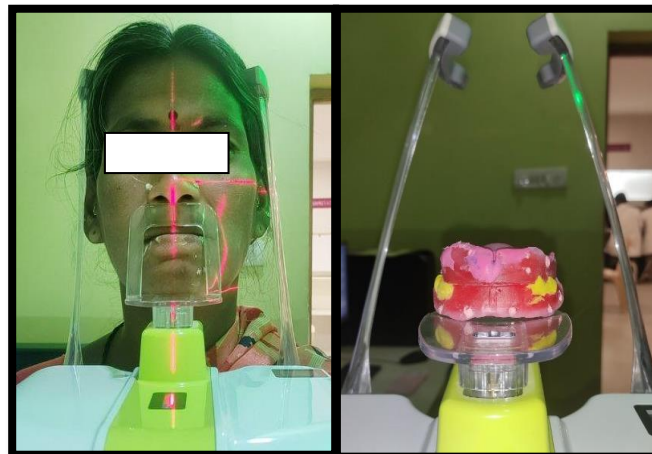


Figure 2: Intraoral and Extraoral CBCT of the occlusal rims with composite markers.

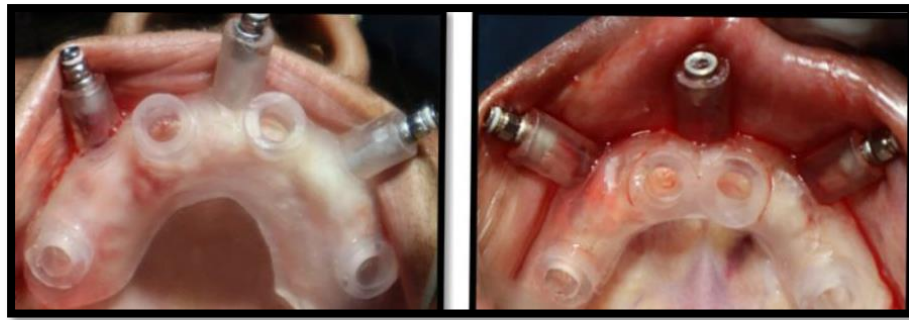

Figure 3: Surgical guides stabilized using anchor pins.

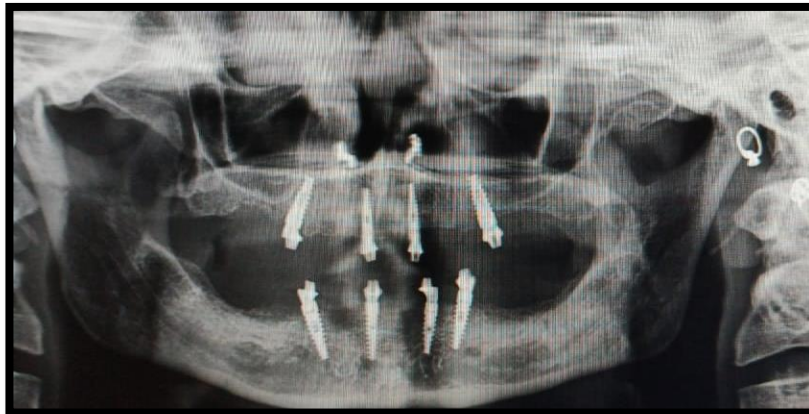

Figure 4: post-operative OPG

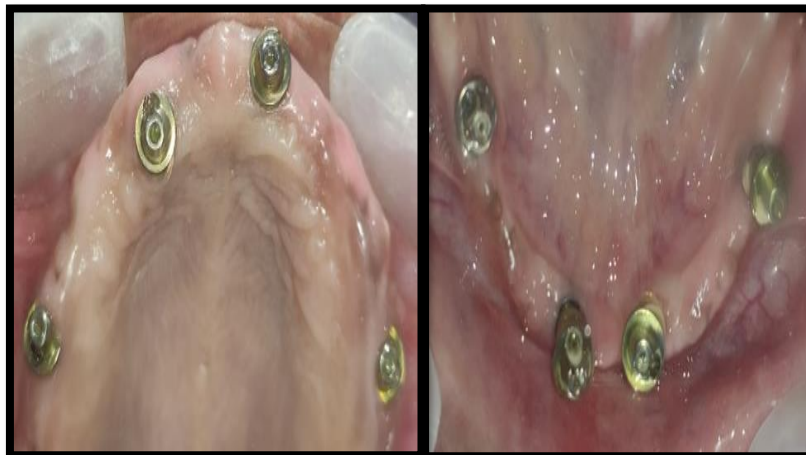


Figure 5: Multiunit abutments in maxillary and mandibular arches.

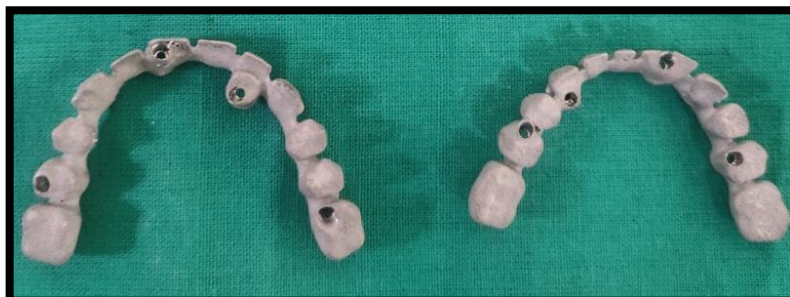

Figure 6: Maxillary and mandibular metal frameworks

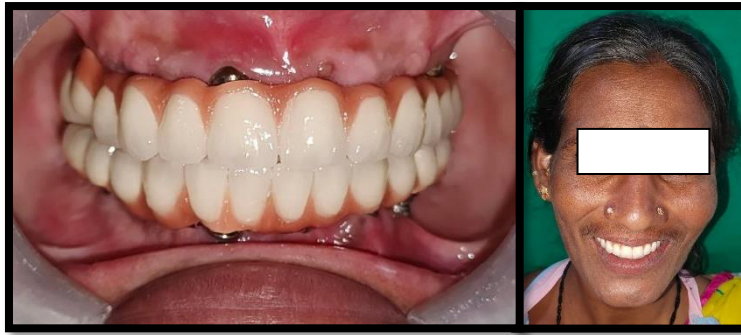

Figure 7: Intraoral and Extraoral view of the prosthesis