PROXIMAL SPLENORENAL SHUNT FOR NON-CIRRHOTIC PORTAL HYPERTENSION WITH HYPERSPLENISM - A CASE SERIES

[1]Leena.S, [2]Mohamed Marzook M, [3]Kannan, [4]Anbalagan, [5]Chandrasekar M Student,

[1,2]post graduates
department of general surgery
[3]professor and head,[4]professor, [5]Assistant professor
Department of surgical gastroenterology
saveetha medical college, Tamilnadu.
Corresponding Author: Leena S

Abstract- **A Proximal splenorenal shunt (PSRS) is a surgical procedure for the treatment of non-cirrhotic portal hypertension with hypersplenism. In this procedure, a shunt is created between the splenic vein and the renal vein, which helps to divert blood flow away from the liver and reduce portal pressure. The results of a case series involving the use of PSS for this indication would likely describe the effectiveness and safety of the procedure in a group of patients. After finishing the initial protocols, the patient is followed doppler for accessing the portal system & varices. The surgery was made and the observation of the patient are taken along with the changes of the patients are noted down.**

Keywords: Proximal splenorenal shunt, hypersplenism, noncirrhotic portal hypertension.

1.INTRODUCTION

PSRS is a widely used procedure for patients with non-cirrhotic portal hypertension (NCPH) who have upper gastrointestinal bleeding that has not responded to medical therapy. PSRS is a one-time procedure used to treat variceal bleeding, massive splenomegaly, symptomatic hypersplenism, and portal biliopathy. This can lead to a range of serious complications, including the enlargement of the spleen (hypersplenism), which can cause the spleen to trap and destroy more blood cells than it should. Symptoms of hypersplenism may include fatigue, weakness, and easy bruising.

A high hepatic venous pressure gradient (HVPG) in the absence of parenchymal dysfunction is diagnostic of a disease known as noncirrhotic portal hypertension (NCPH). This kind of portal hypertension does not include cirrhosis of the liver. [1,2] The aetiology of non-alcoholic fatty liver disease (NCPH) may be broken down into pre-hepatic, hepatic, and post-hepatic causes, all of which contribute to an increase in blood flow resistance. [1,2] Pre-hepatic non-alcoholic steatohepatitis (NCPH) is characterised by a condition known as portal vein vein thrombosis (PVT), which leads to a reduction in portal vein flow and an increase in portal vein resistance. [1–4] PVT is the second cause of portal hypertension in industrialised countries, after cirrhosis; nevertheless, it is important to differentiate between cirrhotic and noncirrhotic PVT. Cirrhotic PVT is more common. In patients with cirrhosis, obstruction of the third portal vein is related with hepatocellular carcinoma, and the blockage is caused by the invasion of a primary tumour. [3,4] Portal venous thrombosis is the aetiology of portal hypertension in roughly 5–10% of cases in western countries; however, in poor countries, the percentage of cases linked with PVT ranges from 35–40%. [5] However, PVT in a patient who does not have cirrhosis is an extremely uncommon illness. [3,4] Although portal vein occlusion is usually well tolerated and typically asymptomatic in most individuals, the cause of around one-third of patients is unknown. This is despite the fact that it is known to occur. [5] In a scenario where cirrhosis is not present, the activity of the liver is typical, and there is no indication that the parenchyma is failing to function properly. A high portal pressure may result in life-threatening complications such variceal haemorrhage, intestinal venous obstruction or ischemia, and ascites. These complications can all be avoided by maintaining a healthy portal pressure. Keeping a healthy portal pressure is the best way to prevent encountering these problems. The risk of developing gastric varices is present in people with NCPH who have early PVT; despite this, portal hypertensive gastropathy remains an extremely rare condition. Ascites is a condition that may manifest itself and has been connected to both internal bleeding and infection in the gastrointestinal system. [4] The therapy for NCPH involves reducing the pressure in the portal vein and preventing the bleeding from the varices. This is done in order to bring the condition under control. [2,6,7] The purpose of surgery in the treatment of NCPH is to lessen the amount of resistance that the portal vein experiences by devascularizing esophageal varices and creating a portosystemic shunt. This is accomplished by reducing the amount of resistance that the portal vein encounters. [6–8] Patients who have portal hypertension and develop a problem that does not respond to pharmacologic or endoscopic treatment may be good candidates for surgery. On the other hand, surgery could be required in situations when the patient has persistent bleeding or infection, limitations in their day-to-day activities, inadequate medical facilities, or the need to carry out a definitive therapy only once. [2,5,6]. Doctors diagnosed PSRS in NCPH after examining a patient who complained of dark stools as their predominant symptom. To help this patient, we performed a splenorenal shunt at the proximal end of the spleen. His recuperation after the procedure was uneventful, and he returned to full health. Involvement in regular activities and the use of medicines may help him avoid developing portal hypertension. The patient has provided their informed consent in writing for the distribution of their case information and associated images. This agreement must be deemed fully informed.

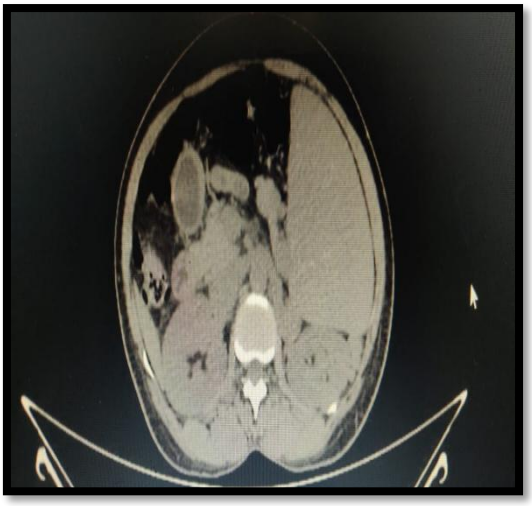

There have been reports of the illness coming from every corner on the planet, but most noticeably from countries that are considered to be impoverished. According to the consensus statement on NCPF that was produced by the Asia Pacific Association for the Study of the Liver (APASL), the disease is responsible for about 10–30% of all cases of variceal bleed in a number of different regions around the world, including India [8]. India was included in this statistic. Young boys who originate from low-income socioeconomic situations and are in their third to fourth decades are more likely to be affected by this disease [9], [10], [11], and [13]. In Japan, a disorder that is similar to NCPF is referred to as IPH, but in the West it is known as idiopathic non-cirrhotic PHT. It is more common in women and appears in the fifth decade [14], [15], [16]. In Japan, IPH is known as idiopathic pulmonary hypertension. These discrepancies in population size might be attributable to changes in living circumstances, ethnicity, average life expectancy, reporting bias, and the diagnostic criteria that were used. There are rumours of a decline in the disease's prevalence, which may have something to do with the higher cleanliness and maternity care standards that have led to a lower number of cases of umbilical sepsis and diarrheal episodes in young children.

In order to select patients for PSRS, a thorough evaluation of their medical history and current symptoms is necessary. This may include imaging studies, blood tests, and other diagnostic tests. It is important to carefully weigh the benefits and risks of the procedure before making a decision to undergo treatment.

2.CASE STUDY

An thorough clinical history, physical examination, and appropriate blood tests were performed on each patient during the first visit. All patients underwent upper GI endoscopy (UGIE) and Doppler ultrasonography (USG) to assess the portal system and varices. PSRS surgery was performed on patients on an elective or semi-elective basis. Every patient had a thoracoabdominal incision for PSRS. The utilisation of a thoracoabdominal incision allowed for improved exposure with less complicated energy source usage. 6-0 prolene was used to perform the anastomosis between the left renal vein and splenic vein. During surgery, heparin (100 units/kg) was given after the splenic vein was mobilised and before closing the left renal vein.

CASE REPORT -1

Middle aged women presented with history of recurrent episodes upper GI bleed for 3 years.patient has history of endoscopic variceal banding a year ago. on examination patient was pale ,per abdominal examination revealed a massive splenomegaly, Spleen was enlarged upto the umbilicus .Blood investigations revealed pancytopenia .

UGI SCOPY: shows grade 3 esophageal varices .Portal hypertensive gastropathy with Portal hypertensive duodenopathy.CT SCAN:features of chronic non cirrhotic portal hypertension with cavernous transformation of portal vein with reduced portal vein caliber,splenomegaly with hypersplenism. She was diagnosed with extrahepatic portal hypertension with hypersplenism and variceal bleeder. Patient treated with proximal splenorenal shunt and postoperative uneventful.

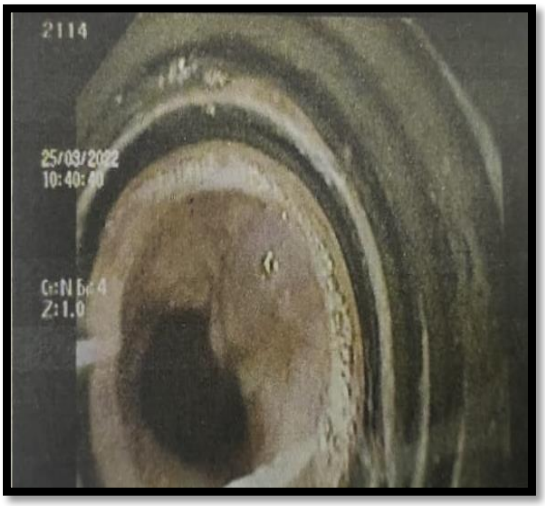

CASE REPORT -2

A 35 year old middle aged women came with complaints of hematemesis. Abdominal examination showed splenomegaly and baseline investigation showed anaemia and thrombocytopenia. Patient had history of variceal band ligation a year ago for variceal bleed. UGI scopy shows grade 3 esophageal varices and portal hypertensive gastropathy.
CT SCAN portal venous obliteration and portal cavernoma with perisplenic and perigastric collaterals and ascites. She was managed with proximal splenorenal shunt. Liver biopsy revealed portal bridging fibrosis features suggestive of chronic liver disease.postoperatively patient was managed in the intensive care unit initially and patients condition improved and was discharged . patient was followed up until one year and has no postoperative complaints.

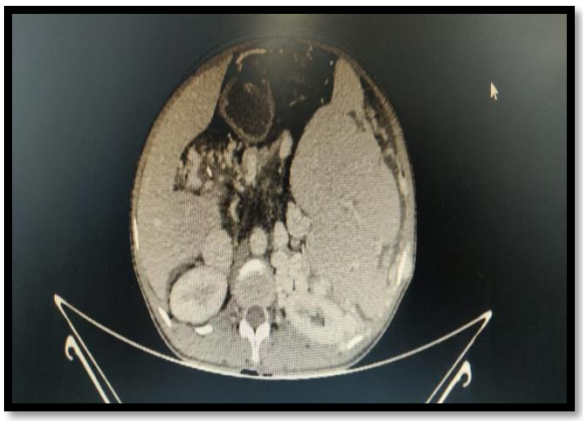

CASE REPORT -3

Adolescent girl known case of EHPVO diagnosed 5 years on endoscopic surveillance and history of variceal band ligation presented with abdominal pain. Abdominal examination showed massive splenomegaly. Complete hemogram reported bicytopenia and required multiple blood transfusion.

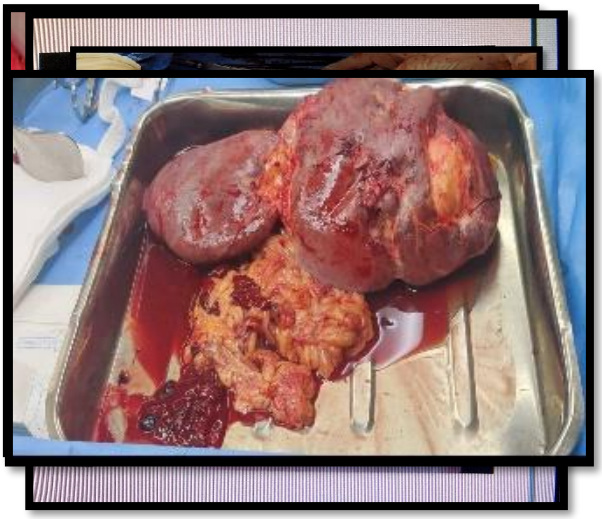

UGI scope:Grade II oesophageal varice ,Portal Hypertensive Gastropathy and Duodenopathy

CECT :Features suggestive of Extra-hepatic portal vein obstruction with massive splenomegaly, cavernous transformation of portal vein and other porto-systemic and porto-portal shunts.

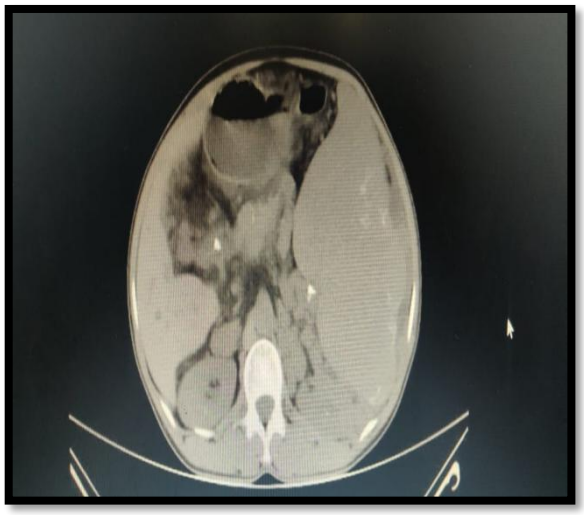

She was treated with proximal splenorenal shunt and post operative recovery was good and liver biopsy was normal parenchymal architecture.

3.DISCUSSION:

PSRS was shown to be more suitable in patients with NCPH owing to the huge splenomegaly that is associated with the condition. This massive splenomegaly causes discomfort, agony, and hypersplenism and is not entirely reversed after distal splenorenal shunt. Esophageal varices and hypersplenism were present in all three patients who received PSRS; nevertheless, none of them experienced any serious problems as a result of the procedure. This implies that PSRS is both safe and effective in avoiding stomach variceal rebleeding in patients with EHPVO or NCPF. [Citation needed] The PSRS is intended to be a one-time solution. In addition to this, it may reverse the alterations that occur as a result of hypersplenism. When one takes into account the constraints of endoscopic glue treatment The non-cirrhotic form of portal hypertension is a perplexing illness that may appear in a variety of clinical ways. The treatment for this condition involves endoscopy and surgery. Both shunt surgery and devascularization are possible surgical treatments. PSRS in patients with hypersplenism treats hypersplenism and lowers the risk of variceal bleeding in non-cirrhotic patients with portal hypertension.

A non-cirrhotic patient with portal hypertension and hypersplenism may benefit from a surgical treatment known as proximal splenorenal shunt, or PSRS for short. A disorder known as portal hypertension describes an unusually high blood pressure inside the portal vein. This vein is responsible for transporting blood from the digestive organs to the liver. This can result in a number of serious complications, such as an enlarged spleen (also known as hypersplenism), which can cause the spleen to capture and destroy a greater number of blood cells than it normally would. This can cause a variety of symptoms, including fatigue, weakness, and easy bruising.

It is necessary to execute the PSRS technique in order to establish a link between the splenic vein and the renal vein in order to successfully treat non-cirrhotic portal hypertension with hypersplenism. The symptoms of hypersplenism are alleviated as a result of this, since it helps to lower the pressure in the portal vein and decrease the size of the spleen.

The PSRS procedure is typically performed under general anesthesia and can be done either laparoscopically or through an open incision. During the procedure, the surgeon creates a shunt by connecting the splenic vein to the renal vein, allowing blood to bypass the liver and reducing the pressure in the portal vein.

In conclusion, PSRS is an effective surgical treatment option for patients with non-cirrhotic portal hypertension and hypersplenism. It helps to reduce the pressure in the portal vein and relieve the symptoms associated with the enlargement of the spleen. However, as with any surgical procedure, there are risks and benefits that must be carefully weighed before making a decision to undergo treatment.

4.CONCLUSION

The presence of both NCPH and PVT at the same time is a very unusual manifestation of the disease. During the procedure, the surgeon will make an effort to alter the circulation of the blood in the portal veins and will attempt to restrict the flow of blood as much as is humanly feasible. The techniques that are considered to be devascularization procedures and that make use of the modified Alterations made to the portal circulation were brought about by the implantation of a proximal splenorenal shunt. This shunt established a connection between the left renal vein and the splenic vein in a way that spanned the whole of the venous system.

REFERENCE:

[1] Sarin SK, Khanna R. Non-cirrhotic portal hypertension. *Clin Liver Dis*. 2014;18:451–476. doi:10.1016/j.cld.2014.01.00924679506 [Crossref], [Web of Science ®], [Google Scholar]

[2] Khanna R, Sarin SK. Non-cirrhotic portal hypertension – diagnosis and management. *J Hepatol*. 2014;60:421–441. doi:10.1016/j.jhep.2013.08.01323978714 [Crossref], [Web of Science ®], [Google Scholar]

[3] Kobilica N, Skalicky M, Milotic F, Flis V. Non-cirrhotic and non-malignant acute extrahepatic Portal Vein Thrombosis (PVT): short- and long-term results. *J Int Med Res*. 2011;39:1090–1098. doi:10.1177/147323001103900344218197 43 [Crossref], [Web of Science ®], [Google Scholar]

[4] Seijo S, Plessier A. Noncirrhotic nontumoral portal vein thrombosis. *Clinl Liver Dis*. 2014;3:118–121. doi:10.1002/cld.336 [Crossref], [Google Scholar]

[5] Wani ZA, Bhat RA, Bhadoria AS, Maiwall R. Extrahepatic portal vein obstruction and portal vein thrombosis in special situations: need for a new classification. *Saudi J Gastroenterol*. 2015;21:129–138. doi:10.4103/1319-3767.15755026021771 [Crossref], [Web of Science ®], [Google Scholar]

[6] Marti J, Gunasekaran G, Iyer K, Schwartz M. Surgical management of noncirrhotic portal hypertension. *Clinl Liver Dis*. 2015;5:112–115. doi:10.1002/cld.470 [Crossref], [Google Scholar]

[7] Mangla V, Pal S, Sahni P. Surgery for non-cirrhotic portal hypertension: current status. *Trop Gastroenterol*. 2016;37:152–155. doi:10.7869/tg.348

[8] S.K. Sarin, A. Kumar, Y.K. Chawla, S.S. Baijal, R.K. Dhiman, W. Jafri, et al. Noncirrhotic portal fibrosis/idiopathic portal hypertension: APASL recommendations for diagnosis and treatment Hepatol Int, 1 (2007), pp. 398-413

[9] C. Vakili, M.J. Farahvash, T.E. Bynum 'Endemic' idiopathic portal hypertension. Report on 32 patients with noncirrhotic portal fibrosis World J Surg, 16 (1992), pp. 118-125

[10] S.K. Sarin, S.R. Agarwal Idiopathic portal hypertension Digestion, 59 (1998), pp. 420-423

[11] R.K. Dhiman, Y. Chawla, R.K. Vasishta, *et al.* Non-cirrhotic portal fibrosis (idiopathic portal hypertension): experience with 151 patients and a review of the literature

[12] C. Pande, A. Kumar, S.K. Sarin Non-cirrhotic portal fibrosis: a clinical profile of 366 patients Am J Gastroenterol, 101 (2006), p. 191

[13] K. Madhu, B. Avinash, B. Ramakrishna, C.E. Eapen, N.K. Shyamkumar, U. Zachariah, *et al.* Idiopathic non-cirrhotic intrahepatic portal hypertension: common cause of cryptogenic intrahepatic portal hypertension in a Southern Indian tertiary hospital Indian J Gastroenterol, 28 (2009), pp. 83-87

[14] S. Hillaire, E. Bonte, M.H. Denninger, N. Casadevall, J.F. Cadranel, D. Lebrec, *et al.* Idiopathic non-cirrhotic intrahepatic portal hypertension in the West: a re-evaluation in 28 patients

[15] D. CazalsHatem, S. Hillaire, M. Rudler, A. Plessier, V. Paradis, B. Condat, *et al.* Obliterative portal venopathy: portal hypertension is not always present at diagnosis J Hepatol, 54 (2011), pp. 455-461

[16] J.N.L. Schouten, F. Nevens, B. Hansen, W. Laleman, M. van den Born, M. Komuta, *et al.* Idiopathic noncirrhotic portal hypertension is associated with poor survival: results of a long-term cohort study Aliment Pharmacol Ther, 35 (2012), pp. 1424-1433