

Appendicular Tuberculosis a Rare Entity of Extrapulmonary Tuberculosis: A Case Report

¹Atul.A.Patil , ²Subodh.P.Ugane

¹Junior Resident, ²Associate Professor
Department of General Surgery , Government medical college , Miraj , Maharashtra

ABSTRACT: Tuberculosis of the appendix is a rare form of gastrointestinal tuberculosis. Primary tuberculosis of the appendix is uncommon. Histopathological reporting of the appendectomy specimen remains the only modality available for the diagnosis at present. A 31-year-old male patient came with a complaint of intermittent episodes of right iliac fossa pain for 1 month, with increased intensity for last 3 days.. .

KEYWORDS: Tuberculosis, histopathological, appendectomy

INTRODUCTION

The burden of extrapulmonary tuberculosis is high ranging from 15-20% of all Tuberculosis cases in HIV-negative patients[1]. Abdominal tuberculosis refers to tuberculosis infection of any organ in the abdominal cavity, including the gut and peritoneum[2]. Abdominal tuberculosis cases make up about 3% of all extrapulmonary tuberculosis cases in India[3]. The most commonly affected sites in the abdomen are the GI tract distal to the duodenum (ileum, jejunum, and colon) and the peritoneum[4]. The other organs are more rarely affected. Tuberculosis of appendix is very rare even in countries where TB is endemic[5]. Prevalence of primary tubercular appendicitis varies from 0.1 to 3% of all appendectomy specimen and secondary tubercular involvement in case of diagnosed TB is 1.5 - 30 % in previous literatures[6]. There are no pathognomic signs and symptoms to prompt preoperative diagnosis of tubercular appendicitis[7].

CASE REPORT

A 31 year old male patient was admitted in surgical ward of our hospital with complaints of abdominal pain since 3 days. The patient was apparently all right 1 month back , when he experienced sudden onset lower abdominal pain , more on right side .The pain got relieved on taking medications .The patient experienced similar episode 15 days before admission which also subsided with medication .At the time of admission, the patient presented with right illiac fossa pain ,which was severe in intensity .The pain was associated with anorexia , no episodes of vomiting and fever .He had normal bowel habits .He doesn't have a significant past medical history.

On examination , at the time of the exam, the patient was averagly built well nourished .his blood pressure was 118/70 mmHg, his heart rate was 88/min, and he was completely alert and focused.No signs of pallor ,cyanosis , clubbing , icterus. With due consent ,he was examined in lying down position.

On inspection -the contour of abdomen is flat , centrally placed umbilicus , no scar over the abdomen.

On palpation -The abdomen was soft with tenderness in the right illiac fossa was present

On percussion – tympanic note was present all over the abdomen, with liver dullness in the right hypochondria.

On auscultation – normal bowel sounds were present.

INVESTIGATION

Blood tests revealed white cell count of 8000/mm³ (Neutrophils-55% lymphocytes-35%). Rest of the blood investigations were normal .Ultrasound suggestive of appendix in right illiac fossa shows signs of inflammation in form of dilated lumen with diameter 8.5 mm with probe tenderness .Sputum examination for CBNAAT- no Mycobacterial tuberculosis Chest x-ray -WNL

TREATMENT

After due written informed consent, the patient was subjected to a laparoscopic appendectomy. Intraoperative findings were excessive intraabdominal dense adhesion, along with inter-bowel adhesion. Because of which the procedure was converted to laparotomy after taking consent from the relatives, which revealed the presence of patent urachus. The patent urachus is excised. There were multiple inter-bowel flimsy adhesions along with omental adhesions too. All the adhesions were separated, and the appendix was located and found to be inflamed. The appendectomy was carried out. There was the presence of mesenteric lymphadenopathy; the largest lymph node was taken for biopsy. An omental biopsy was also taken. Appendectomy specimen along with lymph node and omental biopsy were sent for histopathology reporting. On histopathology reporting.

Omentum- acute on chronic non specific inflammation

Mesenteric lymph node -reactive lymphoid hyperplasia

Appendectomy specimen -caseating granulomatous inflammation -suggestive of tuberculosis .

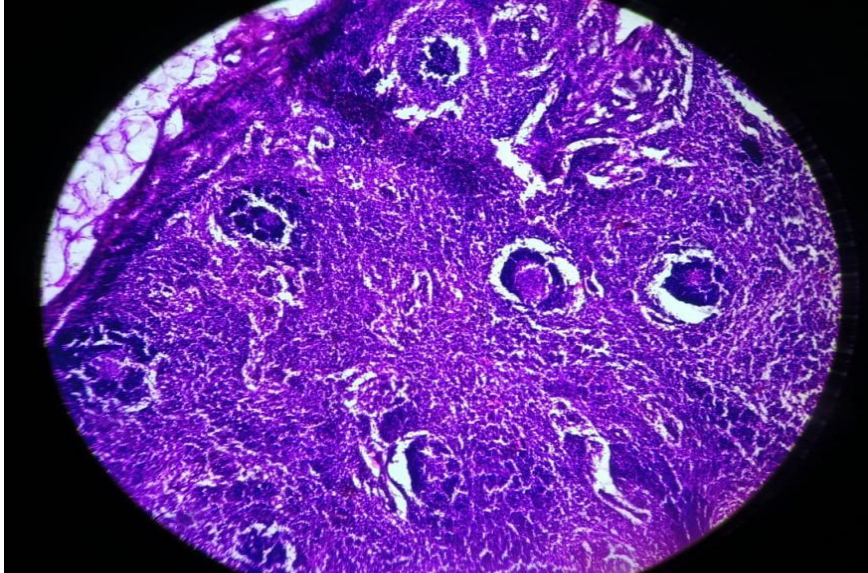


Fig-1 Photomicrograph reveals mesenteric lymph node showing reactive lymphoid hyperplasia(H and E stain, low power view

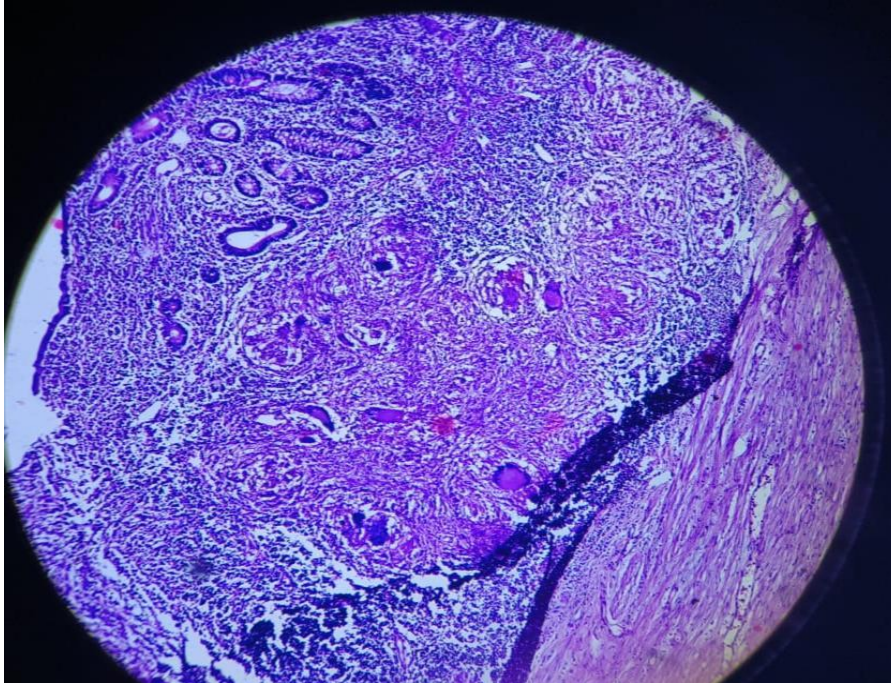


Fig2 - Photomicrograph reveals central caseous necrosis, epithelioid granulomas,and Langhans giant cells in muscular layer with chronic inflammatory cell infiltration (H and E stain, low power view).

DISCUSSION

In developing countries like India, gastrointestinal TB is common. However, primary appendicular TB is relatively rare, accounting for 0.1%–3% incidence of all appendectomies worldwide[8]. Gastrointestinal Tuberculosis presents with obstruction; and in some cases with ascites

Appendicular tuberculosis does not have any typical symptoms to confirm the diagnosis pre-operatively.

Appendicular tuberculosis is thought to be more common when it occurs in chronic form and appendicitis is secondary to tuberculosis. The most common symptoms are mild to moderate abdominal pain. Clinical diagnosis of tubercular appendicitis is difficult as no clinical feature is pathognomonic for tubercular appendicitis.. As the cases of Appendicular tuberculosis are rare a presumptive diagnosis pre operatively is too rare . Initial management of acute appendicitis even of tubercular etiology is an appendectomy. Anti tuberculosis treatment should be started early after histopathological diagnosis.

CONCLUSION

As appendicular TB presents with symptoms similar to acute appendicitis, appendectomy is first performed. Tuberculosis is diagnosed on histopathologic reports .The diagnosis is confirmed patient should be started on Anti-tuberculosis drugs.

References

1. Ngangue YR, Mbuli C, Neh A, Sham E, Koudjou A, Palmer D, Ndi NN, Qin ZZ, Creswell J, Mbassa V, Vuchas C. Diagnostic accuracy of the truant MTB plus assay and comparison with the Xpert MTB/RIF assay to detect tuberculosis among hospital outpatients in Cameroon. *Journal of Clinical Microbiology*. 2022 Aug 17;60(8):e00155-22.

2. Rodriguez-Takeuchi SY, Renjifo ME, Medina FJ. Extrapulmonary tuberculosis: pathophysiology and imaging findings. *Radiographics*. 2019 Nov;39(7):2023-37.
3. Sharma SK, Ryan H, Khaparde S, Sachdeva KS, Singh AD, Mohan A, Sarin R, Paramasivan CN, Kumar P, Nischal N, Khatiwada S. Index-TB guidelines: guidelines on extrapulmonary tuberculosis for India. *The Indian journal of medical research*. 2017 Apr;145(4):448.
4. Debi U, Ravisankar V, Prasad KK, Sinha SK, Sharma AK. Abdominal tuberculosis of the gastrointestinal tract: revisited. *World Journal of Gastroenterology: WJG*. 2014 Oct 10;20(40):14831.
5. Chong VH, Telisinghe PU, Yapp SK, Chong CF. Tuberculous appendix: a review of clinical presentations and outcomes. *Singapore medical journal*. 2011 Feb 1;52(2):90.
6. Pal S, Bose K, Chowdhury M, Sikder M. Tuberculous appendicitis: A rare case report. *CHRISMED Journal of Health and Research*. 2016 Apr 1;3(2):144
7. Ambekar S, Bhatia M. Appendicular tuberculosis: a less encountered clinical entity. *BMJ Case Reports CP*. 2021 Feb 1;14(2):e237718
8. Chandra BS, Girish TU, Thrishuli PB, Vinay HG. Primary tuberculosis of the appendix: a rare cause of a common disease. *Journal of surgical technique and case report*. 2013 Oct 10;5(1):32-4.