

Why Primary Cbd Closure Is Still an Taboo

¹Dr SHREE VENKATESAN.B, ²Dr KALAISELVI, MS DGO,
³Dr ASHIQ AHAMED.A, ⁴Dr P.THANGAMANI

¹POST-GRADUATE ,IGS ,MMC ,Chennai, ²ASSISTANT PROFESSOR ,IGS ,MMC,
³MS, ASSISTANT PROFESSOR ,IGS ,MMC ,Chennai, ⁴MS,PROFESSOR ,CHIEF OF SURGERY ,IGS ,MMC ,Chennai

ABSTRACT:

CBD exploration followed by T-tube insertion has been the primary practice in hospitals without laparoscopy expertise as it prevents future complications like obstructive jaundice(secondary to retained stone or stricture) .However over several decades various authors have shown that primary closure of CBD without T Tube proven to be beneficial when compared to that of T tube insertion and also avoids potential complication of peri-tubal leak and iatrogenic stricture formation

LEARNING OBJECTIVE:

To reiterate that primary closure of CBD can be achieved safely without T-tube insertion without significant post op complications.

INTRODUCTION:

Cholelithiasis develops in about 10–15% of patients with gallbladder stones and that of common bile duct (CBD) stones are encountered in approximately 7–15% of patients undergoing cholecystectomy.

There are two methods for extracting CBD stones either endoscopically, by endoscopic retrograde cholangiopan creatography (ERCP), or surgically, by an open or laparoscopic method.

The advancement in laparoscopic and endoscopic techniques has almost made open biliary surgery obsolete. However even now in resource poor countries due to lack of training as well as equipment, many surgeons are commonly required to perform open cholecystectomy and CBD exploration for choledocholithiasis.

Open exploration of the bile duct was the principal treatment for almost 100 years. Choledochotomy followed by T-tube drainage is a traditional surgical treatment for choledocholithiasis. Although it is true that the T-tube has been used and has proven to be a safe and effective method for postoperative biliary decompression, it is not exempt from complications, which are present in up to 10% of patients. The most frequent of these is bile leakage after removal, which is reported to occur in 1–19% of cases. Some of these complications are serious, such as bile leak, tract infection or acute renal failure from dehydration due to inadequate water ingestion or a very high outflow, particularly in elderly patients. In addition, having bile drainage in place for at least 3 weeks causes significant discomfort in patients and delays their return to work.

Primary closure of the CBD after exploration is not new. “Halstead et al”(1) first described the advantages of primary closure. There are many papers reported by different authors, which support the direct closure of the duct immediately after exploration. With the help of a choledochoscope or intra operative cholangiogram during surgery, primary closure is possible with almost certainty of removing stones

As early as 1965, “Sawyers et al”(2). documented the advantages of primary closure of the CBD and recommended that routine use of a T-tube following CBD exploration be abandoned . In the only report from the Caribbean, “Walrond et al(3)” recommended that T-tubes should not be used . In two Cochrane reviews, one each for open and laparoscopic biliary surgery, the authors were inconclusive regarding the benefits and safety of T-tubes .

However, in many places, routine use of a T-tube following CBD exploration remains standard practice. T-tubes are associated not only with prolonged hospital stay and complications such as retained stones, retained T-tube fragments, inflammatory polyps, sepsis, tube dislodgement, bile fistula, biliary stricture, bile leakage and peritonitis .Open biliary surgery, CBD exploration and drainage with primary closure of the CBD can be safe in experienced hands and is specifically useful in a limited resource setting. In our hospital, open CBD exploration is still the treatment chosen for CBD stones. In this case series, our aim was to highlight the clinical short-term results of primary closure of CBD and reiterate the fact that it is safe to do this procedure.

CASE SERIES

1.Mrs Rani,65 yr,comorbids-.T2dm,

Presented with right hypochondriac pain x 20 days

Investigations:T.billirubin-2.6,D.billirubin-1.5,ALP-545

Mrcp –cholelithiasis with choledocholithiasis of size 1.4cm at distal cbd with upstream dilatation of 1.3 cm of CBD

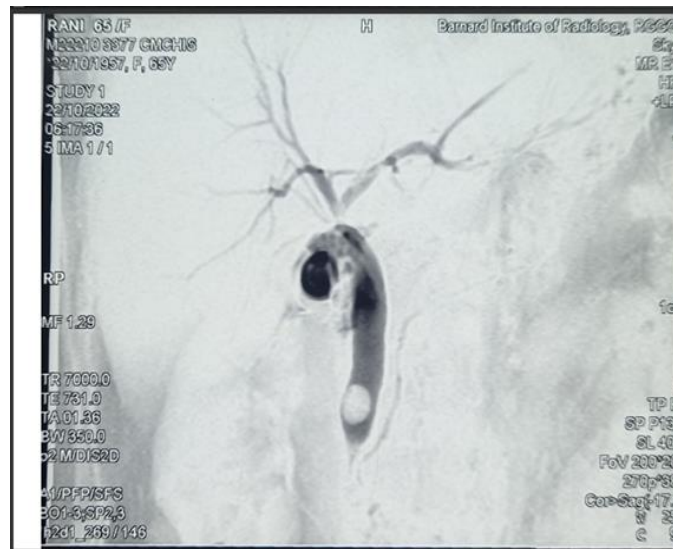

Figure 1

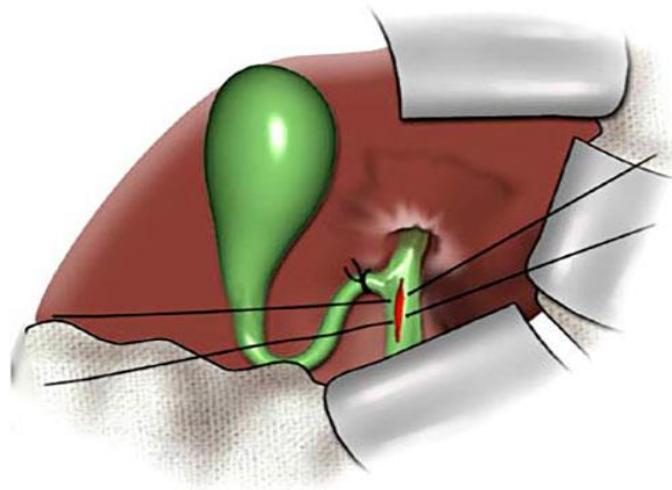


Figure 2

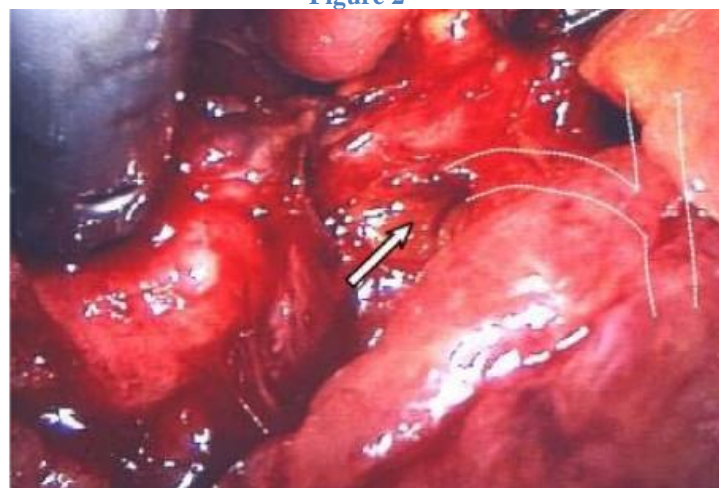

Figure 3

2. Mrs. Kalavani, 39/F
 c/o diffuse abdomen pain x 3 months, especially after meal.
 Admitted for biliary pancreatitis.
 Investigations: T. bilirubin 3.6, d. bilirubin 1.8, Alp 560
 Amylase 390, lipase 420
 MRCP: multiple gb calculi largest 6.5x7mm, multiple mid and distal cbd calculi size 4-5 mm and proximal cbd dilatation 7.3mm.

3. Mrs Tamil, 54/F

c/o abdomen pain x 10 days, radiating to back

past history: partial cholecystectomy in 2003

comorbid: t2 dm

Mrcp: cholelithiasis 1 x 0.7 cm in cystic duct and choledocholithiasis 0.7 x 0.6 cm in distal cbd with proximal cbd dilatation of 1.4 cm ERCP stenting done .

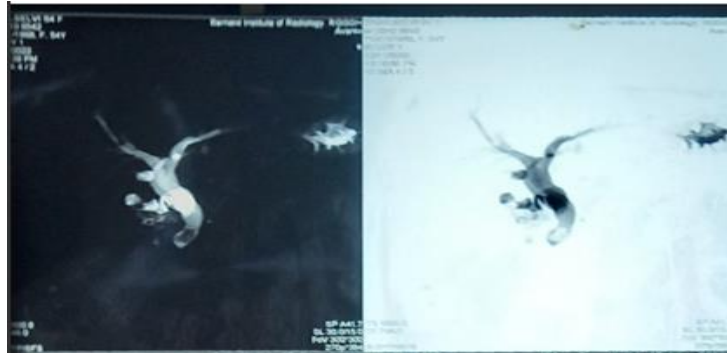

Figure 7

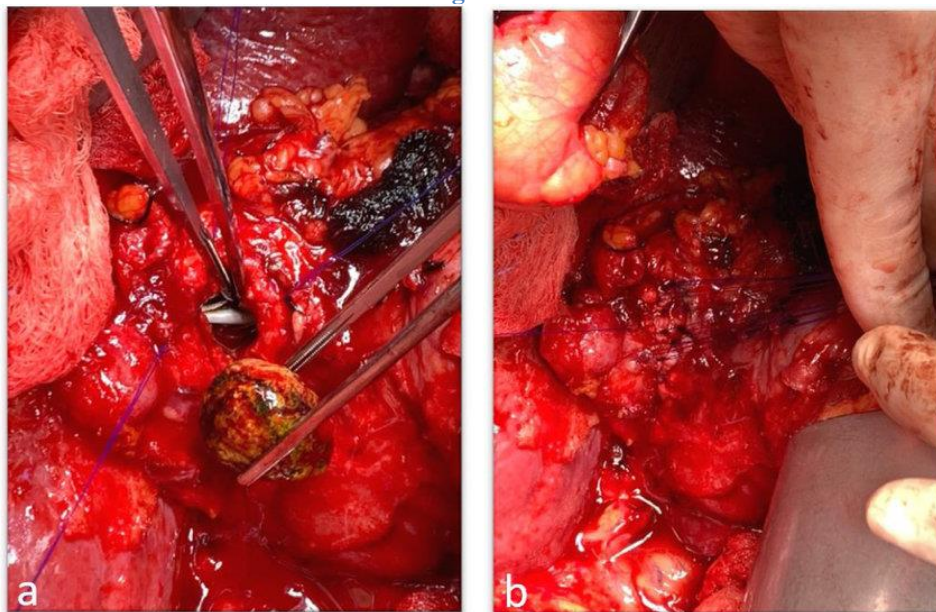

Figure 8

Intraop cbd fibrosis was present

DISCUSSION

From the 3 patients that we have encountered over the period of 6 months from jan 2022 to September 2022 ,we have encountered similar yet distinct cases that posed us unique challenge like post cholecystectomy retained cystic duct calculi ,multiple cbd calculi with cbd fibrosis ,yet primary closure as attempted after careful anterior trans choledochotomy approach.cbd calculi were flushed out carefully until no more calculi was obtained ,those which were large enough to be flushed was carefully removed with Desjardins.patency of cbd confirmed with feeding tube saline flushing .intraop cholangiogram not done in all 3 cases.post operative period was uneventful,patient recovered well and rt sub hepatic dt placed for all 3 cases were removed 6,6,7 post operative date respectively.biochemical parameters were within normal range.post op followup after 1 month was uneventful and patient satisfaction in terms pain and functionality was satisfactory.

RESULTS:

From our experience we have found that primary cbd closure is possible with on-table intra-abdominal usg,saline flushing of cbd with saline via feeding tube as an adjunct to on table cholangiogram .yet there has to be an consensus among new surgeons to forego T Tube placement whenever and wherever possible .

REFERENCE

1. Halstead WS Surgical Papers. Vol 2 Baltimore, Md Johns Hopkins University Press 1924;427- 472
2. Sawyers JL, Herrington JL, Edwards WH. Primary closure of the CBD. Am J Surg. 1965;09:107-12
 1. Walrond ER (1982) Bile duct surgery without tubes or stents. West Indian Med J 31:34-37
 2. West Indian Med J 31:34-37
 3. Walrond ER (1982) Bile duct surgery without tubes or stents. West Indian Med J 31:34-37
 4. West Indian Med J 31:34-37
3. Walrond ER (1982) Bile duct surgery without tubes or stents. West Indian Med J 31:34-37
4. Bile duct surgery without tubes or stents -E R Walrond-PMID: 7101902

5. Primary Closure Versus T-tube Drainage After Open Choledochotomy. Ambreen A.R. Shaikh A. Jamal J.N. Qureshi A.G. Dalwani M.M. Memon
[https://doi.org/10.1016/S1015-9584\(09\)60004-X](https://doi.org/10.1016/S1015-9584(09)60004-X)
6. Open common bile duct exploration without T-tube insertion—two decade experience from a limited resource setting in the Caribbean
Vijay Naraynsingh · Seetharaman Hariharan · Michael J Ramdass · Dilip Dan · Parul Shukla · Ravi Maharaj
DOI: 10.1007/s12262-010-0060-1
7. Williams JA, Treacy PJ, Sidey P, Worthley CS, Townsend NC, Russell EA. Primary duct closure versus T-tube drainage following exploration of the common bile duct. Aust N Z J Surg. 1994 Dec;64(12):823-6. doi: 10.1111/j.1445-2197.1994.tb04556.x. PMID: 7980254.