SONOGRAPHIC EVALUATION IN GALL BLADDER PATHOLOGIES

[1]DR.M. PAVAN KUMAR, [2] DR.BUSHRA FARHEEN, [3]DR.N.GIRIDHAR GOPAL

[1]Post graduate in MD Radio-diagnosis, [2] Post graduate in MD Radio-diagnosis
, [3] PROFESSOR in MD Radio-diagnosis
[1]Department of Radio-diagnosis,
[1]MAHARAJAH'S INSTITUTE OF MEDICAL SCIENCES NELLIMARLA, VIZIANAGARAM, INDIA

Abstract: Patients who have gallbladder disease may commonly present with acute right upper quadrant pain, nausea or vomiting, mid-epigastric pain, and/or jaundice. Etiologies include inflammation with or without infection, noninflammatory disorders, and benign or malignant neoplasms of the gallbladder or bile ducts. Ultrasound (US) is now accepted as the initial imaging modality of choice for the work-up of suspected gallbladder disease. The study was carried out at maharajahs institute of medical sciences, Nellimarla, Department of radio-diagnosis. 75 patients were included, by ultrasound Phillips affinity 70 HD unit with a curvilinear transducer of 1 to 5 MHz the age of the patients is between (26 - 89) years, 38 Patients (50.60%) were males and 37 patients (49.40%) were females. Range of age group of accumulation for gallstone presence was (26 - 58) years and most common in males than females. Incidence of gallstone are 38 (51%) patients, other pathologies of gallbladder were found to be acute cholecystitis 13%, polyp in 15%, tumors seen in 7% patients. Ultrasonography is a single imaging modality sufficient for evaluation of patient with suspected gallbladder pathologies which can provide information about the presence of gallstone and more over about site and cause of biliary tract obstruction. Ultrasound is highly sensitive and specific means for diagnosis of the gallbladder stones. Sensitivity and specificity of ultrasound in evaluation of gallstones high (97.7%, 95. 6%) respectively.

Index Terms: ultrasound, Cholecystitis, Gallbladder

I. INTRODUCTION

Abdominal pain can result from abnormalities in gall bladder, kidneys, [(1)] pancreas, stomach, duodenum, spleen… etc. all these conditions can be diagnosed easily via sonographic procedure. other cases cannot be properly diagnosed with ultrasound such as uncomplicated peptic [(2)] ulcer disease, acute myocardial infarction and basal pneumonitis. ultrasound is the first imaging test used for detection of gallbladder and bile duct abnormalities. this test is non-invasive, uses no dyes, and is not painful. ultrasound produces good images of the small ducts in [(3)] the liver and the higher part of the major bile duct. ultrasonography is the most helpful imaging modalities used for the diagnosis of gallstone disease. it is safe, rapid, and relatively inexpensive and involves no radiation exposure. it is the image of choice for patients with suspected biliary colic. positive findings include stones, thickening of the [(4)] gallbladder wall, pericholecystic. a common disorder is gallbladder stones and is usually asymptomatic. some patients show biliary colic, and often severe pain in the epigastrium or right upper quadrant, and sometimes between the scapula due to temporary obstruction of the cystic duct with a gallstone. in case the cystic duct obstruction persists, [(5)] the patient may develop cholecystitis. the presence of cholecystitis was best diagnosed by ultrasound images normally indicate the presence of gallstones, pericholecystic fluid and a thickened wall of gallbladder. ninety to ninety percent of all cases of acute cholecystitis are caused by obstruction of either the cystic duct or the [(6)] neck of the gallbladder by gallstones. acute cholecystitis, however, [(7)] occurs in only approximately 20% of patients who have gallstones. this means that most gallstones are asymptomatic. thus, right upper quadrant pain in a patient who has gallstones often is caused by [(8)] something other than acute cholecystitis. furthermore, studies have shown that only 20%–35% of patients presenting with right upper [(6,7)] quadrant pain are subsequently shown to have acute cholecystitis. in cases with symptomatic gallstones and a negative ultrasound [(9)]) examination, endoscopic ultrasound may be helpful. tumors occurring in gallbladder are either benign or malignant. papillomas, adenomyomas, or cholesterol polyps are associated with benign tumors. whereas malignant tumors are uncommon, cholecystectomy [(10)] for patients with polyps larger than 10 mm seems warranted. if gallbladder is not detected, scan with high resolution and frequency linear or linear array transducers is mandatory. this minimizes missing tiny [(10)] gallstones, especially in the funds of the superficial gallbladder. this measurement includes the mucosa, smooth muscle of its wall, liver capsule and any tissue between the liver and gall-bladder. the normal measurements are taken in the transverse rather than longitudinal plane to avoid any possibility of thickening due to measuring in an off-axis plane. the normal appearing wall is not [(11,12)] routinely measured. the present study was designed to see the frequency and occurrence of different types of gb pathologies and to evaluate the accuracy of ultrasonography for diagnosis of different gallbladder disorders.

II. MATERIALS AND METHOLOGY

Department at maharajahs institute of medical sciences Nellimarla. We collected data of patients subjective to US of gallbladder.75 patients referred to the ultrasound department for abdominal ultrasound either symptomatic or asymptomatic subjected to ultrasound using Phillips affinity 70 HD unit with a curvilinear transducer of 1 to 5 MHz. Data analysis performed using the tables and computerized systems.

III Hospital protocol

The patient must fast 8 hours before the exam, when patient come will lie on an exam table. Patient move his clothing away from abdomen and then apply gel to the area. The gel will help the transducer make secure contact with the body and eliminate air between

the transducer and the skin. Once the imaging is complete, the clear ultrasound gel will be wiped off skin. Any portions that are not wiped off will dry quickly. The ultrasound gel does not usually stain or discolor clothing. The exam usually takes less than 40 minutes.

IV TECHNIQUE

With the patient in the supine position, then applied gel then start scan with the probe in longitudinal plane, the probe orientates cephalic and asking patient holding breath Once the gallbladder is clearly identified, obtain longitudinal and transverse views of the gallbladder. Use the liver as an acoustic window.

RESULTS AND DISCUSSION

Out of 75 patients included in this study in which 38(50.6%) males and 37(49.4%) female patients.

GENDER	FREQUENCY(N=75)	PERCENTAGE
MALES	38	50.6%
FEMALES	37	49.4%

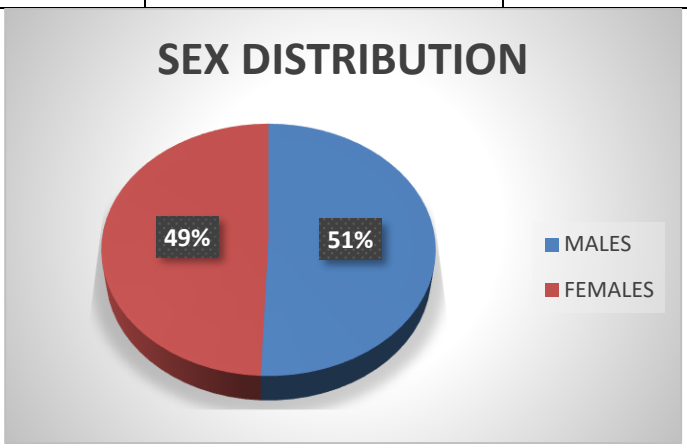

DISTRIBUTION OF SYMPTOMS AMONG PATIENTS

CLINICAL FEATURES	NO. OF PATIENTS	PERCENTAGE
Nausea	16	21.3%
Vomiting's	13	17.3%
Abdominal pain	75	100%
Jaundice	24	32%
Fever	15	20%

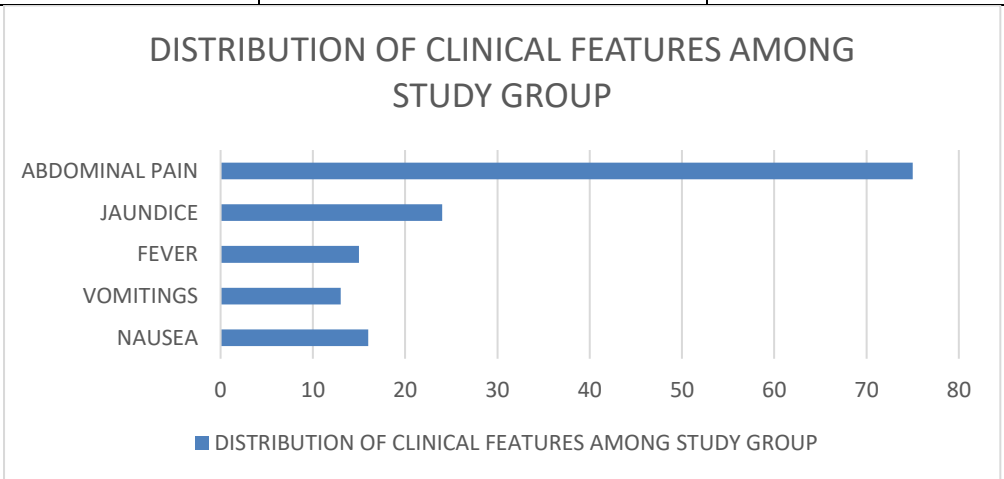

DISTRIBUTION OF GALL BLADDER PATHOLOGIES

PATHOLOGIES	FREQUENCY	PERCENTAGE
Cholelithiasis	38	51%
Acute cholecystitis	10	13%
Chronic cholecystitis	4	5%
Gall bladder polyps	11	15%
Gall bladder tumors	5	7%
Normal	7	9%

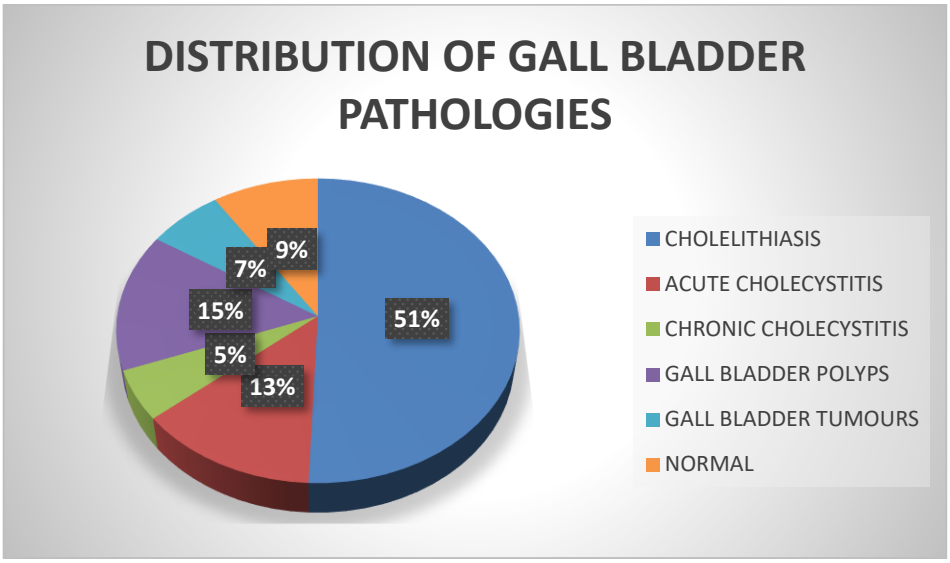

Distribution of confirmation according to type of investigation

Pathology	Positive on USG	Positive on CT scan	Positive on cholecystectomy	Confirmed cases
Cholelithiasis	38	36	36	36
Gall bladder polyps	11	9	-	9
Gall bladder tumors	5	5	5	5

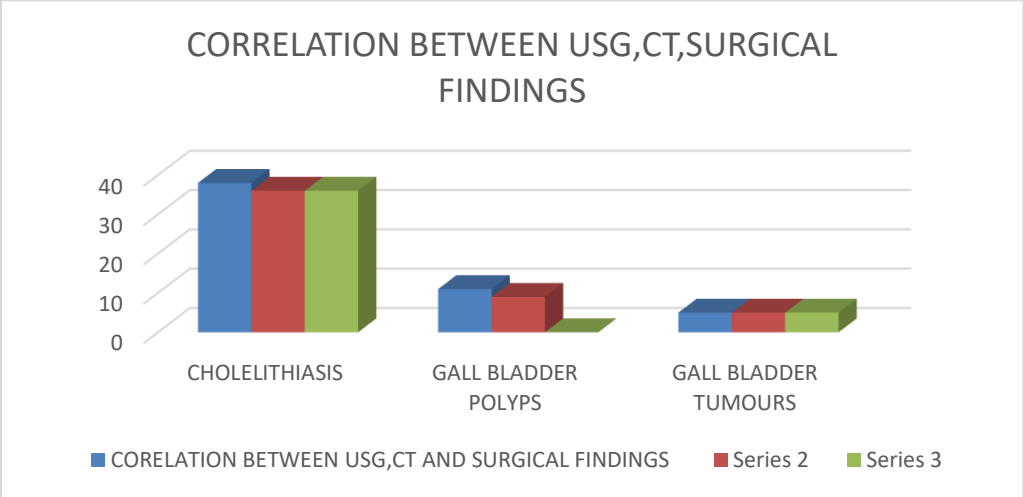

REPRESENTATIVE CASES

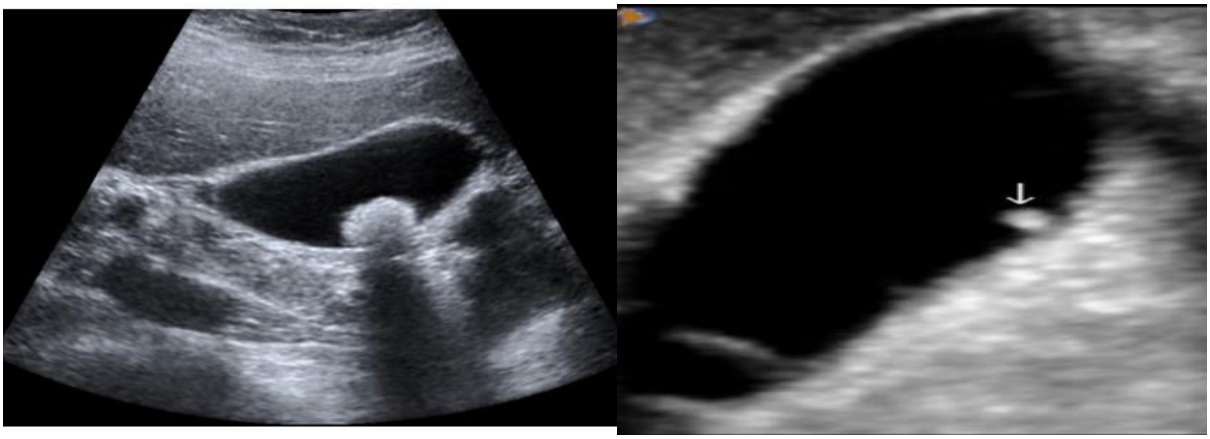

FIG 1- show thickness (cholecystitis) in wall of gallbladder with stone

FIG 2- show polyp with sludge of gallbladder

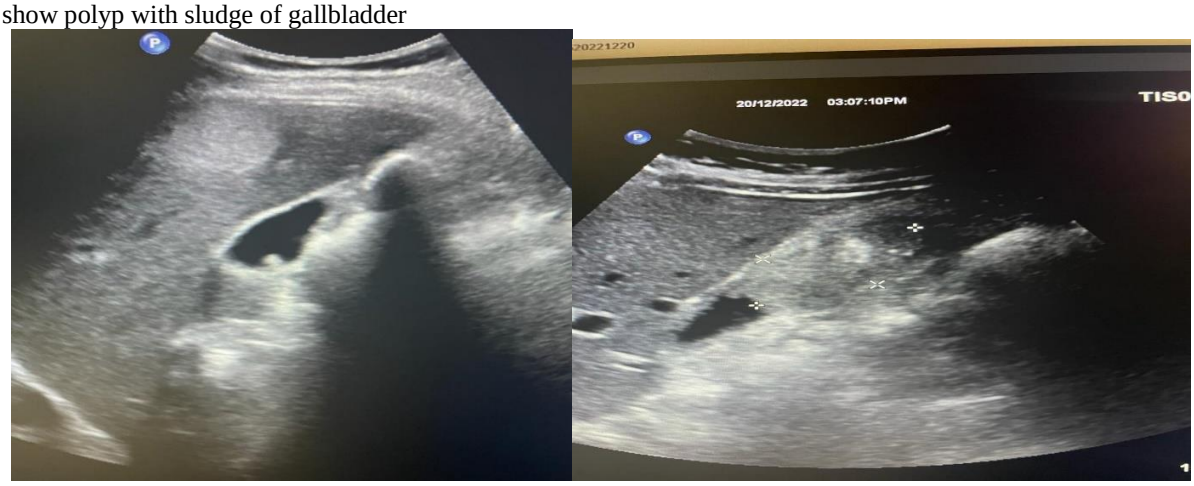

FIG 3- Showing calculus in lumen of gall bladder

FIG 4- well distended gall bladder showing well defined hyperechoic soft tissue mass lesion in lumen of gall bladder with internal vascularity- S/o Malignancy of gall bladder

Discussion

The study was carried at maharajahs institute of medical sciences, Nellimarla in the department of radio-diagnosis 75 people were taken into the study who presented with upper abdominal pain referred to USG for further evaluation in which 38 (50.60%) males and 37 (49.40%) females, ratio of males to females is 1.027:1, the mean age of the patients was 45.30years (Range 26–89 years). In the present study the patients have the following symptoms, Abdominal Pain was seen in all patients (100%), Jaundice 24 (32%), Nausea 16 (21.3%), Fever 15 (20%), Vomiting 13 (16.7%). Gallstones are diagnosed on US by the presence of gravity-dependent, mobile, echogenic foci within the gallbladder lumen that cast a posterior shadow. Gallstones have presented in 38 (51.7%) patients in this study, acute cholecystitis in 10(13%), chronic cholecystitis in 4(5%), gall bladder polyps in 11(15%), gallbladder tumor's in 5(7%) and normal is seen in 7 (9%) and most of them males. Although ultrasound has been demonstrated to have an accuracy (>95%) for the identification of gallstones, stones that are too small, (usually <1mm to cast a posterior shadow soft stones lacking strong [10] internal echoes, or gallstones impacted in the gallbladder neck or in the cystic duct that may not be as readily detectable on US examination as they silhouette with the surrounding echogenic bowel gas or [13] intraperitoneal fat. Harmonic imaging significantly improves visualization of small gallstones. Sensitivity and specificity of ultrasound in evaluation of gallstones is high respectively (97.7%,95.6%). Confirmation of gallbladder stones in this study is done by cholecystectomy and CT scan. In the study done by Janes et [14] al, 1998 range of age group of accumulation for gallstone presence was 35 - 50 years in females and more than 50 years in male that are readily visible with ultrasonography. Ultrasonography plays a key role in the diagnosis of gall bladder and biliary diseases. In acute cholecystitis, the gall bladder is distended, thick walled and tender, [14] may show calculi and pericholecystic fluid collection. Whereas, in chronic cholecystitis the gall bladder is smaller than usual, with many stones and has thick echogenic wall. In present study acute cholecystitis, a count 10 (13%) patients, acute cholecystitis more than chronic cholecystitis. Previous study is done by Laing et [15] al, 1983 They found, the gallbladder disease affects 8% of men and 17% of women in the United States resulting in over 600,000 surgeries each year. Cholecystitis, the most common emergent surgical condition of the gallbladder, is diagnosed in up to 10% of total patients and 21% of elderly patients presenting to the emergency department with acute abdominal pain. Sludge in present study constitutes with gallbladder stones and with polyp's dependent layer of non-shadowing echogenicity in the gallbladder is characteristic of sludge, which often contains stones. Gallbladder tumors are recognized with increasing frequency, as a consequence of improvements in imaging techniques and increased utilization of these studies. Approximately 5% of patients evaluated with ultrasonography for abdominal pain will have a gallbladder polyp. Cancer of the gallbladder is uncommon, though it is the fifth most common gastrointestinal (GI) malignancy, seen in 7% of people in our study.

CONCLUSION

In the study we found the Ultrasound which is non-invasive and the least expensive imaging modality that is highly sensitive and specific in the assessment of the gallbladder wall and luminal content. It can provide information about the presence of GB pathologies such as G. stone cholecystitis, differentiate between cystic and solid tumor, Gallbladder Polyps and moreover about the site and cause of biliary tract obstruction. The most commonly affected group of gallbladder pathology was between 36 to 45 years. In our study gallstones have presented in 38 (51%) patients most of them males age range 36-45years in females and 45-60 males. Ultrasonography was founded the technique of choice for diagnosing gallbladder calculi and it was the gold standard test for the demonstration of gallstones with sensitivity of 94% and a specificity of 92%. Ultrasound is painless and relatively inexpensive, and has several advantages over oral cholecystography; it doesn't need contrast material, causes no side-effects, and safe during pregnancy.

REFERENCES

1. Roger, C.S. and Nacy, S.M. (1998) Clinical Sonography. Lippincott, New York.
2. Strasberg, S.M. (2008) Acute Calculous cholecystitis. New England Journal of Medicine, 358, 2804-2811.http://dx.doi.org/10.1056/NEJMcp0800929
3. Bennett, G.L. and Blathazar, E.J. (2003) Ultrasound and CT Evaluation of Emergent Gallbladder Pathology. Radiologic Clinics of North America, 41, 1203-1216. http://dx.doi.org/10.1016/S0033-8389(03)00097-6
4. Rumack, C.M., Wilson, S.R. and Charboneau, J.W. (2005) Diagnostic Ultrasound Volume 1. 3rd Edition, Elsevier Mosby, Philadelphia.
5. Trowbridge, R.L., Rutkowski, N.K. and Shojania, K.G. (2003) Does This Patient Have Acute Cholecystitis? JAMA, 289,80-86. http://dx.doi.org/10.1001/jama.289.1.80
6. Laing FC. The gallbladder and bile ducts. In: Rumack CM, Wilson SR, Charboneau JW, editors. Diagnostic ultrasound. Vol. 1. St Louis:Mosby-Year Book; 1998. p. 175–223.
7. Gore RM, Yaghmai V, Newmark GM, et al. Imaging benign and malignant disease of the gallbladder. Radiol Clin North Am 2002;40(6): 1307–23.
8. Cooperberg PL,Gibney RG. Imaging of the gallbladder. Radiology 1987;163(3):605–13.
9. Kubota, K., Bandai, Y., Noie, T., et al. (1995) How Should Polypoid Lesions of the Gallbladder Be Treated in the Era of Laparoscopic Cholecystectomy? Surgery, 117, 481- 487. http://dx.doi.org/10.1016/S0039-6060(05)80245-4
10. Laing, F.C. (1991) The Gallbladder and Bile Ducts. In: Rumack, C.M., Wilson, S.R. and Charboneau, J.W., Eds., Diagnostic Ultrasound, Vol. 1. Mosby-Year Book, St. Louis.
11. Allen-Mersh, T.G., Motson, R.W. and Hately, W. (1985) Does It Matter Who Does Ultrasound Examination of the GB? British Medical Journal, 291, 389 390. http://dx.doi.org/10.1136/bmj.291.6492.389.
12. Huffman, J.L. and Schenker, S. (2009) Acute Acalculous Cholecystitis—A Review. Clinical Gastroenterology and Hepatology, 8, 15-22.
13. Laing FC, Jeffrey RB Jr. Choledocholithiasis and cystic duct obstruction: dif cult ultrasonographic diagnosis. Radiology 1983;146(2):475–9.
14. Janes, J.O. and Nelson, J.A. (1988) Jaundice. In: Eisenberg, R.L., Ed., Diagnostic Imaging: An Algorithmic Approach, JB Lippincott, Philadelphia.
15. Strasberg, S.M. (2008) Acute Calculous cholecystitis. New England Journal of Medicine, 358, 2804-2811. http://dx.doi.org/10.1056/NEJMcp0800929