Endoscopic ear surgery

Dr Arpit Prajapati

D.L.O
Department of E.N.T. Civil Hospital Ahmedabad, Gujarat

ABSTRACT:

Introduction:
Our philosophy is that the curves and niches of the middle ear are best visualized by the endoscope rather than straight line view of the microscope. Microscope is mainly the domain of the mastoid. We are not surgeons of the tool we are surgeons of the ear. Thus we need to combineboth for the benefit of the patient

Aims and objectives:
Is to study

1. **Endoscopic anatomy of the middle ear**
2. **Ventilation pathway of the ear**
3. **And combine the use of endoscope and microscope even in ear surgeries for the better ofthe patient**

Materials and methods:
This is a prospective analysis of 50 patients diagnosed with chronic suppurative otitis media withtympanic perforation and/or adhesive drum in our tertiary care referral center. The period of study is from January 2018 to January 2021. Fifty patients with complete clinical data were identified and included in the study.

Results:
Fifty patients were taken for the study. The mean age was 30.47 years. Thirty three patients (66%)were males and seventeen (34%) were females. There where 42 cases (84%) of CSOM with tympanic membrane perforation in which type 1 underlay tympanoplasty was done and in 4 cases (8%) of type 2 tympanoplasty was done, 2 cases (4%) of exploratory tympanotomy and in 2 cases (4%) atticotomy was done. In 38 patients (76%) tarsal cartilage was used and in rest 12(24%) fascia lata graft was used. In patients with tympanic membrane perforation 35(70%) had blocked ventilation pathway whichwas cleared. Graft uptake was seen in 46 cases (92%) and there was mean AB gap of 35.8 which was reduced to 16.06 post op.

Conclusion:
One should routinely use endoscope to see middle ear anatomy even while operating through post aural routes .Ventilation pathway are best visualized and if blockage present are cleared bythe endoscope. The future of endoscopic ear surgery lies in approach to the lateral skull base viasub cochlear tunnel with minimal morbidity.

Keywords: Endoscopic ear surgery, Endoscopic

INTRODUCTION:

Microscopic surgery has been used for surgeries of the middle ear, mastoid and lateral skull base since decades. Ohnsorge at the Würzburg ENT clinic was the first to describe intraoperative use ofan endoscope [1]. Wullstein used an “ototympanoscope” from the company Storz with a diameterof 2.7 mm intraoperatively in 1984. However, the device had to be held in both hands and could therefore only be used for a control look around the corner [2]. Nine years later, Thomassin and McKennan independently proposed a minimal invasive approach and use of the endoscope for second-look surgery after cholesteatoma surgery [3]. Both surgeons introduced the endoscope into the mastoid via a small incision within the course of the retro auricular scar. Thomassin described use of 30 and 70° endoscopes to reduce residual cholesteatoma in the tympanic sinus and the retro tympanum [2]. In the same year, Poe used the endoscopic approach to inspect the round window for perilymph tic fistulas [4] and, in 2000, described endoscopic stapedioplasty for the firsttime [5]. Tarabichi developed endoscopic ear surgery further and published two case series with 38 and 165 patients in 1997 and 1999, respectively, in whom he performed endoscopic surgery for cholesteatoma and perforations of the tympanic membrane without a microscope [6,7].

Endoscope is best for visualisation of the middle ear anatomy .All the divisions of the middle ear like epitympanum,mesotympanum,retrotympanum,hypotympanum and protympanum are seen withthe endoscope.The facial recess, sinus tympani and sub tensor recess are very well seen with the endoscope along with ventilation pathway of the ear. Endoscopic approach guarantees very detailedview and allows exploration of the round window region since microscope cannot visualise inside these cavities. The round window chamber is defined as the three dimensional space lying between the round window niche and the round window membrane and can be evaluated endoscopically along with the presence of the fustis bone and Proctor’s area concamerata.The fustis was defined asthe thick smooth bone linking the basal turn of the cochlea with the styloid prominence.The Proctor’s area concamerata was defined as an anatomical area composed by bony cells developed around the fustis bone.The subiculum was defined as a bony ridge arising from the posterior pillar towards the styloid complex posteriorly.The finiculus was

defined as a bony ridge arising from the anterior pillar and running towards the floor of the hypotympanum where the jugular dome is located, dividing the inferior retro tympanum from the hypo tympanum.
The sinus subtympanicus was defined as an anatomical space between the subiculum superiorly andthe funiculus inferiorly, developing medially and posteriorly with respect to the styloid prominence, forming a deep space into the retro tympanum below the sinus tympani. “sub cochlear canaliculus” isthe connection between the tympanic cavity (round window chamber) and the petrous apex cells lying under the cochlea and can be type A,B and C thus is the approach for lateral skull base surgery to eradicate cholesteatoma from the petrous apex[8].

In the majority of the subjects, the tensor fold and the lateral incudomalleal fold are complete, and the only ventilation pathway to the epitympanum is through the tympanic isthmus. When the isthmus is open and ET function is normal, the epitympanic compartments and the mastoid cells areventilated and the pressure level is homogeneous; this should probably guarantee normal conditions in the tympanic cavity. Otherwise, when an isthmus blockage occurs, the epitympanic is not well-ventilated, creating different conditions from the mesotympanic compartment, which receives air directly from the ET. In clinical practice it is not uncommon to find an isolated retraction pocket of the pars flaccida and/or a cholesteatoma, limited to the posterior epitympanum, with an otherwisenormal pars tensa and mesotympanum. When ET function is impaired, middle ear mucosa is usuallywidely involved by the inflammation process and the eardrum is completely retracted; however, if the ET is functioning the retraction pocket might possibly be related to a selective dysventilation process[9].Figures showing the anatomy and ventilation pathway are shown below.[1,2]

Thus keeping this in mind our philosophy is that the curves and niches of the middle ear are best visualized by the endoscope rather than straight line view of the microscope. Microscope is mainly the domain of the mastoid. We are not surgeons of the tool we are surgeons of the ear. Thus we needto combine both for the benefit of the patient

AIMS AND OBJECTIVES:

Is to study

1. Endoscopic anatomy of the middle ear
2. Ventilation pathway of the ear
3. And combine the use of endoscope and microscope even in ear surgeries for the better ofthe patient

MATERIALS AND METHODS:

Prospective study was performed for 50 patients which was conducted in our hospital over aperiod of 3 years from January 2018 to December 2021. Patient demographics, symptomatology, surgical approach and patient outcome were assessed

INCLUSION CRITERIA:

- Chronic supportive otitis media with tympanic membrane perforation
- Adhesive drum

EXCLUSION CRITERIA:

- Narrow EAC

All patients underwent a pre op PTA and other hematological investigations and were posted for endoscopic ear surgeries. Some general points were kept in mind during each surgeries which were

- Adopt a comfortable sitting position to prevent fast exhaustion
- Patients head should be in extreme lateral position and preferably under general anesthesia tassure fine movements
- Perform white balance, fine focus and anti foos solution for a perfect view
- Introduce to EAC a 0 degree 18 cm 3/4 mm endoscope and use instruments for endoscopicear surgery
- Endoscope is heated thus rapid irrigation is required
- Light source should never be greater than 50% as it causes thermal injury to the chordatympani.

Endoscopic tympanoplasty:
Keeping the above-mentioned points in mind the margin of the perforation was freshened.3-4 mmlateral to the tympanic isthmus a modified rossens incision was kept and the TM flap was elevated Anterior and posterior ventilation pathways were checked and if blocked were cleared. Ossicularstatus was checked and mobility established in Type 1 cases and then graft was kept by underlay method and TM flap was deposited back and graft stabilized using gel foams

In case if any ossicles were missing or eroded they were removed and a Tragal cartilage thus harvested was used painting the lever mechanism of the middle ear and thus establishing roundwindow reflex and type of tympanoplasty depended on ossicles present.

Endoscopic exploratory tympanotomy:
Ossicular status was checked after elevating the flap and tympanosclerosis if present around the ISjoint and round window was removed. Thus establishing ossicular mobility and round window reflex.

Endoscopic ear surgery with atticotomy :
In patients with limited epithelial lining in the attic,atticotomy was done using bone scoop andepithelial lining was removed .Cartligae reconstruction of the attic was done .

Patients were followed up at 1,4 and 12 weeks to assess graft uptake and Tuning Fork tests. PTAwas done at 3 months

OBSERVATION AND RESULTS:
Fifty patients were taken for the study. The mean age was 30.47 years. Thirty three patients (66%)were males and seventeen (34%) were females. There where 42 cases (84%) of CSOM with tympanic membrane perforation in which type 1 underlay tympanoplasty was done and in 4 cases (8%) of type 2 tympanoplasty was done, 2 cases (4%) of exploratory tympanotomy and in 2 cases (4%)atticotomy was done.In 38 patients(76%) tragal cartilage was used and in rest 12(24%) fascia lata graft was used.

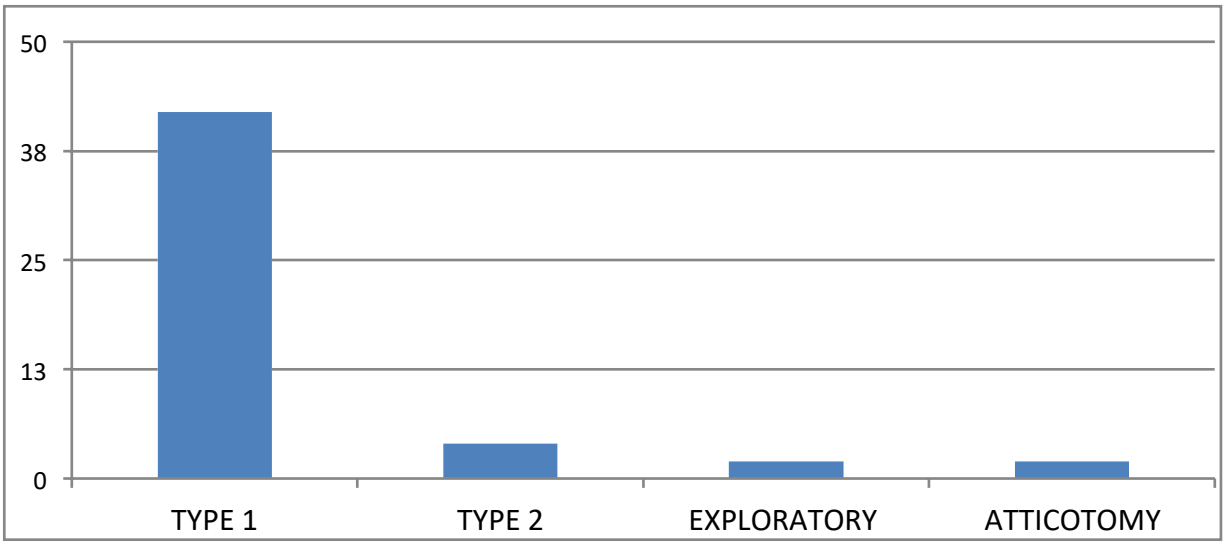

CHART 1 showing type of surgeries done

PTA	Pre Op	Post Op
Mean (db)	35.8	16.06
Median(db)	35	14.5
SD	3.14	3.45
Minimum (db)	30	10

In patients with tympanic membrane perforation 35(70%) had blocked ventilation pathway whichwas cleared. Graft uptake was

seen in 46 cases (92%) and failure was seen in 4 cases (8%) blocked ventilation pathwaypatent ventilation pathway



CHART 2 a showing patients with perforation and 2b showing procedure success

In terms of procedure success in terms of AB gap improvement in endoscopic ear surgeries themean of Pre op PTA was 35.8 and Post op PTA was 16.06.Other details are shown below in the table.

CHART 3 showing procedure success in terms of AB gap improvement in Endoscopic Earsurgeries

In comparison with microscopic ear surgeries 50 cases with same distribution done the followingresults were seen.

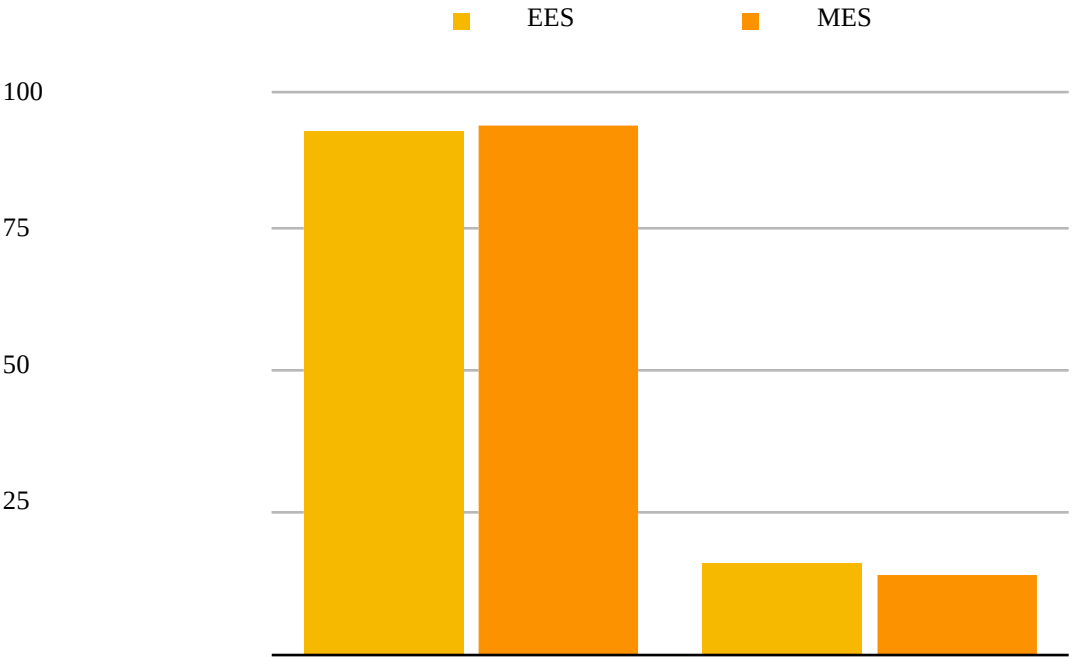

0

Graft uptake in %

AB gap (Post Op Mean)

DISCUSSION:

Endoscopic ear surgery is a revolution in the field of otolaryngology. The wider view of the endoscope gives us a very good visualization of the curves and niches of the middle ear rather than straight line view of the microscope. There were 42 cases (84%) of CSOM with tympanic membrane perforation taken in our study in which type 1 underlay tympanoplasty was done and in 4 cases (8%) of type 2 tympanoplasty was done, 2 cases (4%) of exploratory tympanotomy and in2 cases (4%)atticotomy was done which was less than taken in the study by Tarabichi M et al [6]inwhich 165 patients were taken which had 96 tympanoplasties,13 stapes surgery and 56 cholesteatoma. The procedure success was 92% in our study were as it was 88% in the above mentioned study.In terms of procedure success with mean AB gap in pre op and post op PTA the study by Sarkar et al [11] was preop 41.5+5.2 db and post op was 10.1+3.6 db which was comparable to our study in which pre op was 35.8 db and post op was 16.06 db. As comparison tomicroscopic ear surgery in our own institute the graft uptake and AB gap mean was nearly the same.

CONCLUSION OF EES:

- Wide field view is most important aspect of endoscopic ear surgery.
- Ventilation pathway is best visualized and addressed in EES.
- EES results are comparable with microscopic surgery as far as graph uptake and audiometricresults are concerned.
- More randomized trial required for EES to select definite subset of patients.
- EES proves to be an efficient tool for teaching and training.
- The future of endoscopic ear surgery lies in approach to the petrous apex via sub cochleartunnel with minimal morbidity.

REFERENCES:

1. Ohnsorge P. Intraoperative endoscopy of middle-ear and endoscopic diagnostic of middle-ear bya new endoscopic unit. Arch Otorhinolaryngol. 1977;216:511. doi: 10.1007/BF00458933.
2. Thomassin JM. Otoendoscopically guided surgery. Paris: Springer; 1994.
3. Thomassin JM, Korchia D, Doris JMD. Endoscopic-guided otosurgery in the prevention of residual cholesteatoma. Laryngoscope. 1993;103:939–943. do 10.1288/00005537-199308000-00021.
4. Poe DS, Bottrill ID. Comparison of endoscopic and surgical explorations for perilymphatic fistulas. Am J Otol. 1994;15:735–738.
5. Poe DS. Laser-assisted endoscopic stapedectomy: a prospective study. Laryngoscope. 2000;110:1–37. doi:10.1097/00005537-200005001-00001.
6. Tarabichi M. Endoscopic management of acquired cholesteatoma. Am J Otol. 1997;18:544–549.

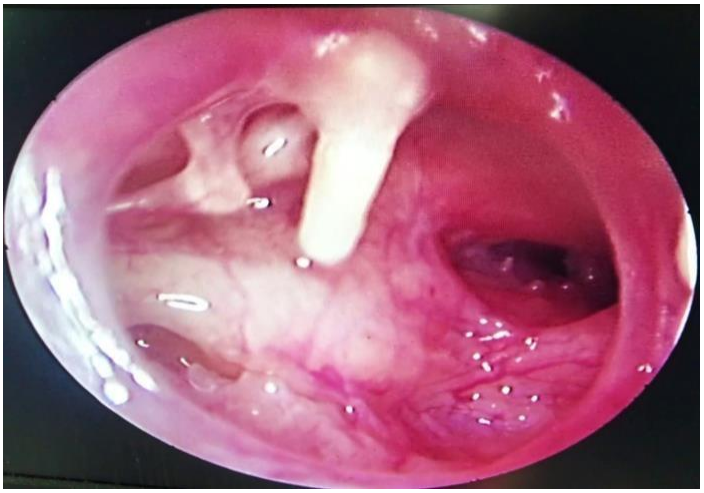

Figure 1 showing middle ear anatomy as seen through the endoscope

Figure 2 showing endoscopic holder used in EES

Figure 3 showing post op graft uptake in case of endoscopic cartilage tympanoplasty

7. Tarabichi M. Endoscopic middle ear surgery. Ann Otol Rhinol Laryngol. 1999;108:39–46. doi:10.1177/000348949910800106.
8. Marchioni, D., Alicandri-Ciufelli, M., Pothier, D.D. et al. Eur Arch Otorhinolaryngol (2015) 272: 1103. https://doi.org/10.1007/s00405-014-2923-8
9. Marchioni, D. , Alicandri-Ciufelli, M. , Molteni, G. , Artioli, F. L., Genovese, E. and Presutti, L.(2010), Selective epitympanic dysventilation syndrome. The Laryngoscope, 120: 1028-1033. doi:10.1002/lary.20841
10. Sarkar S, Banerjee S, Chakravarty S, Singh R, Bera SP. Endoscopic stapes surgery: our experience in thirty two patients. Clin Otolaryngol. 2013;38:157–180. doi: 10.1111/coa.12051.