Type of Article: Retrospective case study Tracheal Balloon Dilatation For Acquired Subglottic Stenosis : Our Institutional Experience

Dr.Kalpesh B.Patel[1], Dr. Dipak B bamanya[2]*, Dr. Oman M Prajapati[3] Dr.brijal H patel[4] , Dr. Vishal Modi[5]

[1]professor & Head Of Unit, [2]third Year Resident,[3]ms Ent Pearl Hospital, Ahmedabad,
[4]Third Year Resident, [5]Third Year Resident
[1,2,4,5]Department of Otorhinolaryngology, B.J.Medical College,Ahmedabad, Gujarat, India.

Corresponding Author :
[1]Dr. Dipak B, bamanya[2]
Department of Otorhinolaryngology,B.J.Medical college, Ahmedabad, Gujarat, India

Abstract:
Objective: To evaluate outcomes of tracheal balloon dilation for laryngeal stenosis.
Design: Retrospective analysis study.
Patients: All patients treated with laryngeal balloon dilation with acquired subglottic stenosis with normal vocal cord mobility from 2017 to 2022.
Main Outcome Measures: Stenosis severity, Measured using the Cotton and Meyer classification, andMcCafferygrading system.
Results: A total of 33 patients of acquired subglottic stenosis ranging in age from 13-67 years (18 [54.5%] with grade II stenos is, 10 [30.3%] with grade I stenosis, and 5 [15.2%] with grade III stenos is) were included. Atotal of 33 balloon dilation laryngoplasties were performed, and 29 (87.9%) were deemed successful. 15 of the 17 patients undergoing primary dilation (88%) had successful outcomes, and in the other 2 [12%], outcomes were unsuccessful and required either laryngotracheal reconstruction or tracheotomy. 16 balloon dilations were performed as a secondary procedure after recent open surgery; all of the procedures(100%) were successful, and thus surgical revision was avoided. After balloon dilatation ,among 22 tracheostomized patients, 19 patient got decannulated.
Conclusion: Balloon dilation laryngoplasty is an efficient and safe technique for the treatment of bothprimary and secondary acquired laryngotracheal stenosis.
"Minimal intervention with maximum results."

Keywords: subglottic stenosis, tracheal stenosis, balloon dilatation, laryngoplasty

INTRODUCTION

Laryngotrachealstenosis (LTS) is defined as partial or complete cicatrical narrowing of the endolarynx or trachea [1]. LTS is a recalcitrant disease with high morbidity. The complexity of the region, which contains delicate structures such as vocal cords, recurrent laryngeal nerve which coordinate the functions of respiration, deglutition, and phonation makes LTS, a difficult entity to manage[2]. Management of LTShas been a major challenge confronting head and neck surgeons for over a century. Tracheal stenosis and the surgical procedure for its optimal management has long been a subject of debate. Incidence of tracheal stenosis has been on rise due to increased incidence of trauma secondary to road traffic accidents and intubation injuries, where incidence of tracheal stenosis, post intubation has been reported up to 21%.Breathlessness on exertion which may be progressive, a brassy cough, recurrent pneumonitis, wheezing, stridor and cyanosis may all be a part of the clinical presentation. It frequently has an insidious onset and the symptoms may be mistaken or disregarded for a variety of other disorders. There are multiple causes of benign tracheal stenosis, the most common being trauma. Awareness of the possibility of tracheal stenosis is very important in the early recognition. The management is timely and appropriate surgical intervention. The surgical procedure should be minimally invasive as we are dealing here with the airway and the patients are usually compromised. In terms of minimally invasive surgery, We can use balloon dilatation we can use it as primary or secondary to diode laser ablation/co2 laser ablation/bougie dilatation/Open laryngeal surgery.

Our main objectives were to investigate some of the controversies concerning this new techniquein order to define the best indications and limitations:

1) Definition of standard operating procedure for dilatation sequences; number of sessions; periodicity and delay.

2) Evaluation of the efficacy and indications of secondary dilation treatment after open laryngeal surgery;diode laser/ CO_2 laser ablation ;.

METHODS

This is a retrospective study of case study of airway stenosis seen in our institute between 2017and 2022 were offered endoscopic treatment using this described protocol. Cases with concurrent glottic or supraglottic involvement were excluded whereas patients with subglottic and tracheal stenosis with normal vocal cord mobility were included in our study. All operations were performed by the same surgeon. Airway stenosis grade was evaluated with 70^0 telescope in the clinic and with 0^0 telescope in the operating room using the Cotton Meyer grading system**(Figure No.1)** and with computed tomography ofneck for using McCaffery grading system**(Figure No.2)**. Etiology of stenosis, number and frequency of dilations, and interval between tracheostomy and decanulation were reviewed. A successful program of dilatation was defined by absence of significant recurrent stenosis, atleast 6 months later. The minimum delay between other laryngeal surgical procedures and balloon dilatation was 15 days for diode laser ablation, 3 months for T tube insertion.

SURGICAL TECHNIQUE

A balloon dilation treatment program was defined as a series of 1 to 2 consecutive dilation proceduresover a maximum period of 18 months. Dilation technique involved an endoscopic high-pressure balloon catheter under general anesthesia with spontaneous ventilation following a standardized protocol. Direct laryngoscopy was performed using a 4 mm 0° telescope(Karl Storz) and



Figure 1 COTTON MEYER CLASSIFICATION FOR SUBGLOTTIC STENOSIS (BASED ON CIRCUMFERENCE OF LUMEN)

the balloon catheter (Metic airway balloon catheter) introduced into the laryngeal lumen through the stenosis.It was then inflated using an inflation device(HAIKU inflation device) designed to monitor and maintain the balloon pressure for 30 seconds or until the patient's oxygen saturation level dropped below 92%. Thesize and diameter of the balloon were selected according to the theoretical ideal diameter of the cricoid ring. The minimum balloon diameter was 10 mm. This procedure was performed 2 or 3 times during each session under general anesthesia and was followed by 1 to 2 minutes of topical application of cotonoid pledgets soaked with mitomycin, 1 mg/mL, if available. Follow-up endoscopy included a secondballoon dilation when necessary. All patients received 3 to 10 days of systemic steroids (deflazacort6 mg 12 hourly), proton pump inhibitors (pantoprazole, 40mg/ d), and epinephrine nebulizers. Follow-up endoscopy was performed every 2 weeks for 4 weeks, and every 4 weeks until complete healing and then every 6 months. Follow-up endoscopy was performed using a 4 mm 0° telescope (Karl Storz) connected on a camera (Karl Storz) under local anesthesia.

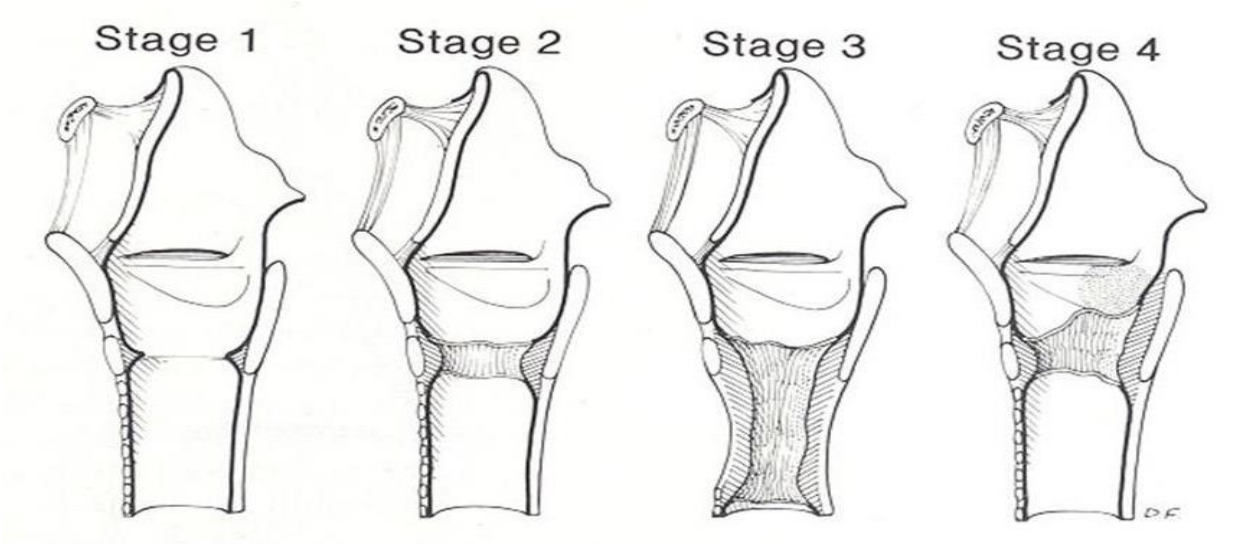

Stage	Description
I	Lesions are confined to the subglottis or trachea and < 1cm long
II	Lesions are isolated to the subglottis and > 1 cm long
III	Subglottic/tracheal lesions not involving the glottis
IV	Lesions involve the glottis

Figure 2 MC CAFFERY STAGING FOR LARYNGOTRACHEAL STENOSIS (BASED ON LENGTH OF STENOSIS)

RESULTS:(Chart No.1,2.)

Our study included 17 women and 16 men with an average age of 33.5 years (range, 13-67 years). The etiologies of airway stenosis were post intubation injury (60%),RTA (10%),strangulation(10%) , OP poisoning(10%) and acid ingestion(10%).Airway stenosis ranged from grade 1 to 3, with grade 2 identified most frequently (54.5%), followed by grade 1(30.3%) and grade 3 (15.2%). The stenotic segment involved the subglottic alone (80%), or both subglottis and trachea (20%). The length of the stenotic segment was ≤1 cm in all patients, average length being 6.2 mm (ranging from 5-10 mm). All patients had resolution of their airway symptoms after each treatment from both a subjective and an endoscopic standpoint. For the entire group, the mean number of procedures was 1.9 (range, 1-3) over an average follow-up period of 14.7 months (range 6-26 months). Repeat dilations, when needed, were performed approximately 2.9 weeks apart (range, 2 weeks to 4 weeks). 50% patients underwent diode laser ablation before balloon dilatation, and 30% underwent diode laser ablation and T tube insertion before balloon dilatation. Out of total,66% patients were tracheostomized and none were retracheostomised. Out of 22 tracheostomized patients, 85.7% were decanulated successfully, the average interval between tracheostomy and decanulation being 7.09 months(range 3-16 months). Out of the 11 non tracheostomized patients, all the patients were relieved from symptoms of laryngotrachealstenosis

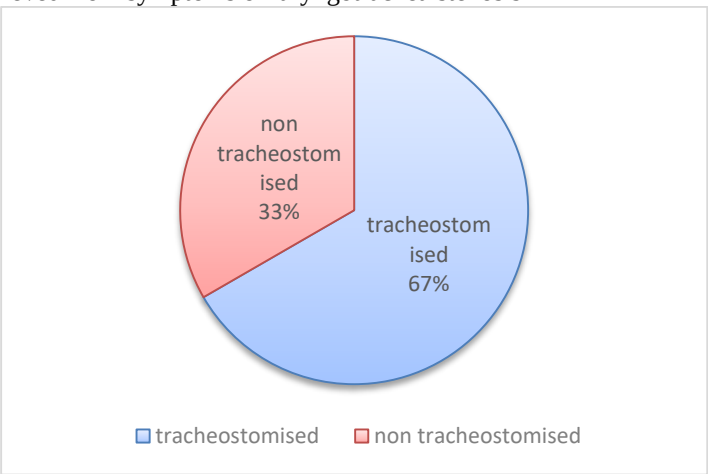

CHART 1 PRIMARY BALLOON DILATATION

CHART 2 SECONDARY BALLOON DILATATIO

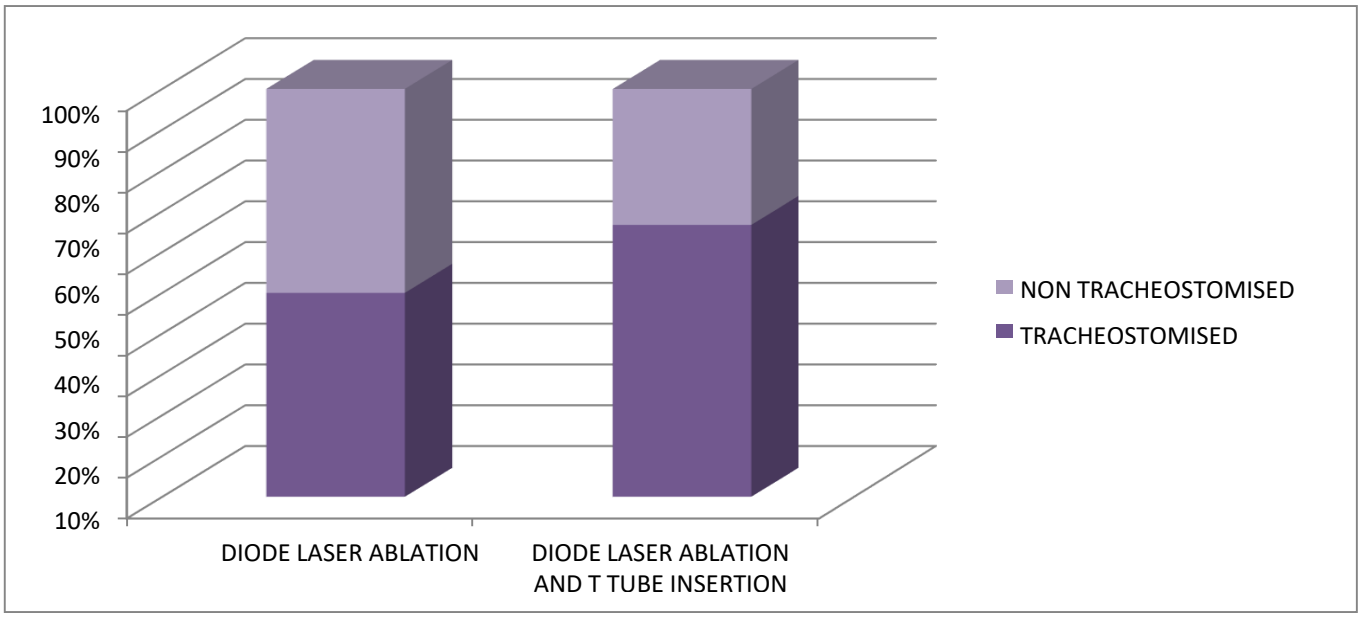

DISCUSSION

Several surgical approaches have been proposed for the treatment of subglottic stenosis. Since the early 1980s, the gold standard technique has been open laryngeal surgery combining laryngeal expansion withcricoid sections and/or cartilage grafts and various types of
stenting[3-5]. Single-stage laryngo-tracheoplasty was introduced in the 1990s and replaced tracheostomy with endotracheal intubation during the first days of postoperative healing. The overall success of these procedures is about 80% and is influenced by several factors, such as
stenosis grade, patient age and weight, and the association of GER and other co-morbidities[6-8]. Monnieret al[9]first introduced the concept of complete resection of the stenosis and reported an excellent outcomeof about 90% with partial cricotracheal resection. Before these advances, therapeutic options included prolonged tracheostomy and/or "bougienage," an often inefficient and sometimes dangerous dilation technique that was subsequently abandoned. Despite the well demonstrated efficacy of balloon dilations in vascular diseases and esophageal stenosis, many otolaryngologists are still reluctant to use these new techniques in the airway[10]. However, there are several theoretical advantages of balloon dilation when compared with rigid techniques: reduced shearing forces, radial balloon inflation, limited dilation trauma even in pinpoint stenosis, and lower complications rates. Despite continuing improvements in open surgical techniques, in co-morbidity treatments (GER), and the advances in pediatric intensive care, some patients still require several open procedures to obtain a patent and stable airway[11].Balloon dilations were progressively introduced into our practice starting in 1990 and have proved very useful in the treatment of anastomotic stenosis after esophageal atresia repair and in some cases of tracheal or bronchial stenosis[9,12,13]. Recently, new types of balloons have been introduced that are characterized by higher resistance and stability owing to their oblong shape. These balloons seem to particularly well suited for use in the laryngotracheal lumen.

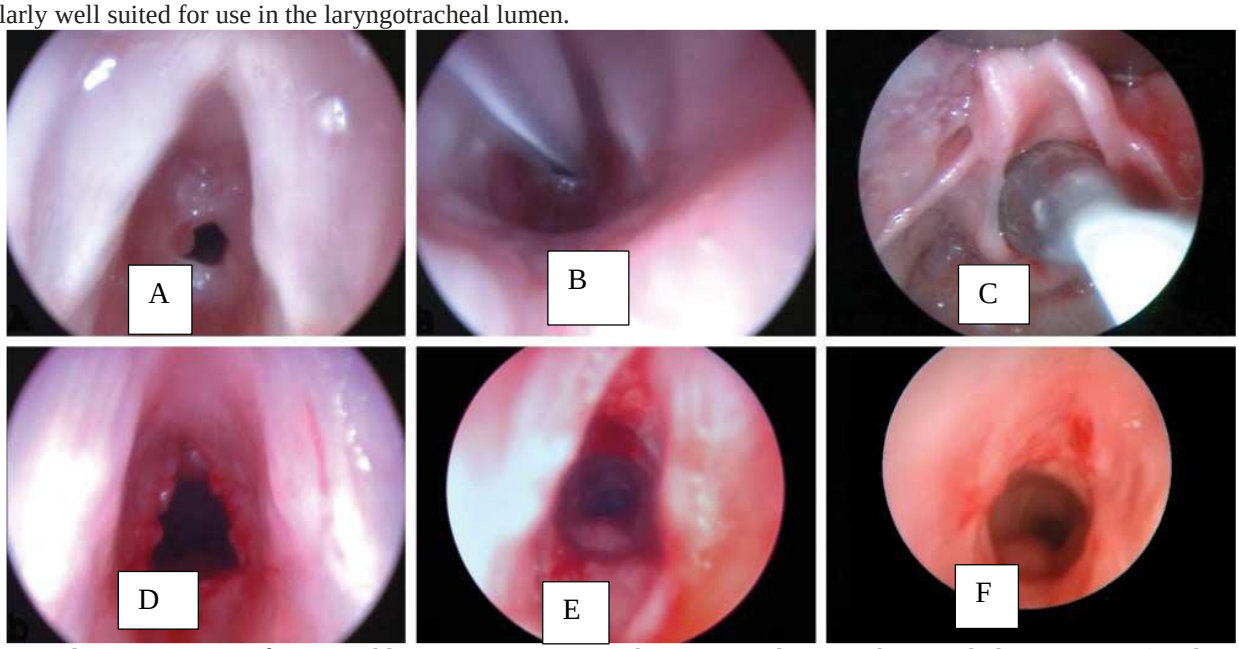

Figure 3. *Endoscopic images of a 64 yr old woman presenting with an acquired postintubationsubglotticstenosis (grade III).* ***A-E, Endoscopic images using rigid0° 4-mm telescope(Karl Storz) under general anesthesia with spontaneous ventilation. A,***

Subglotticstenosis before endoscopic dilation. ***B,*** *Introduction of a10-mm diameter deflated balloon through the stenosis.* ***C,*** *Endoscopic view of the balloon inflated through the larynx.* ***D,*** *Endoscopic appearance immediately afterthe first balloon procedure.* ***E,*** *Endoscopic appearance after the second balloon procedure.* ***F,*** *Revision rigid endoscopy under general anaesthesia after 3 month.*

We have progressively extended balloon dilation use to include laryngeal stenosis, and it has become animportant adjunct in the postoperative care of other laryngeal surgical procedures. In our series, secondary dilations succeeded in about 90% of cases, with a mean number of 2 dilation sessions, and avoided revisi on surgery. Similar results were recently reported in 10 children by Bent etal,whereas Quesnel et al obtained a success rate of only 60% in 20 children aftersecondary balloon dilations.

We have used balloon dilations as a primary technique in patients presenting with laryngotracheal stenosis.Recently Mirabirale et al reported a success rate of 83% in series of 18 patients who underwent endoscopic cricoid splint combined with balloon dilatation. this success rate is comparable with that of patient in our series who underwent primary balloon dilatation for acquired stenosis. Their study included 8 patient with congenital stenosis with a 75% success rate, although patients received up to 7 post operative dilatation. These results suggests that endoscopic cricoid splint may be not necessory for acquired stenosis but may increase success rate in congenital stenosis,

our experience with balloon dilations over the past 6 years has led to this technique becoming our first choice in acquired or low-grade congenital subglottic stenosis. Open surgery is proposed for cases in whichdilation fails or in the contexts of bilateral vocal fold immobility or severe pinpoint congenital stenosis.

The interval between 2 dilations was about average 3 week in our series. This interval was dependent oninflammatory and healing processes and regular endoscopic evaluations.

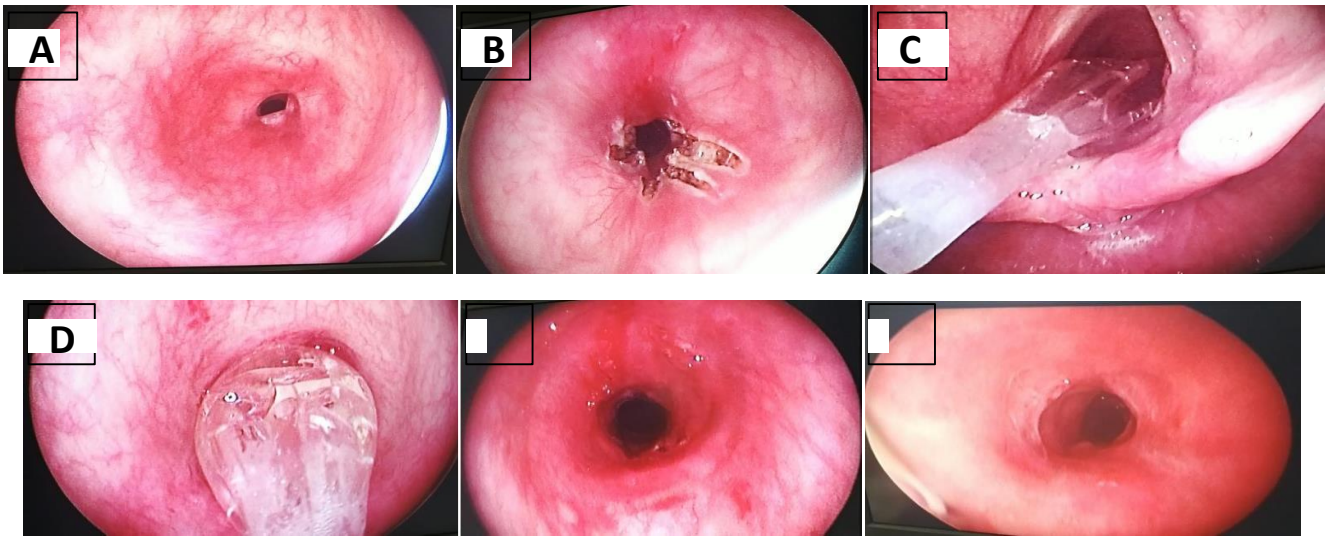

Figure 4. *Endoscopic images of a 14 yr old woman presenting with an acquired poststragulationsubglotticstenosis (grade III).* ***A-E, Endoscopic images using rigid0° 4-mm telescope (Karl Storz) under general anesthesia with spontaneous ventilation****.* ***A,****Subglotticstenosis before endoscopic dilation.* ***B,*** *Diode laser ablation .****C,*** *Introduction of a16-mm diameter deflated balloon throughthe stenosis.* ***D,*** *Endoscopic view of the balloon inflated through the larynx.* ***E,*** *Endoscopic appearance immediately afterthe first balloon procedure****. F,*** *Revision rigid endoscopy under general anaesthesia after 3 months.*

Dilation failure may be anticipated in cases in which no obvious improvement of the subglottic diameter isobtained after 2 or 3 procedures. Some authors reported patients who underwent more than 7 dilation procedures before a successful outcome[13,14,15]. Our belief is that these particular cases require cartilage grafting or resection and that an earlier decision to perform an open procedure is preferable to avoid prolonged hospitalization and a high rate of general anaesthesia.

In our study ,we excluded supraglottic stenosis, congenital subglottic stenosis patients and patients who did not come for regular follow up ,as a result we came across less number of patients for our study.

CONCLUSION

In conclusion, Our study illustrates the growing evidence that balloon dilations are safe and efficient in the treatment of subglottic stenosis and reduces the need for open laryngeal surgery. So, we can get maximum results with minimal interventions. Good indications include primary or secondary treatment ofacquired stenosis of all grades. Open surgery remains the best choice in case of after 2 to 3 dilation procedures without significant improvement.

DECLARATION

Funding : None
Conflict of interest : Non declared
Ethical approval :Not required

REFERANCE

1. Ramdev S, Ghosh P, Mukhopadhyaya S (2005) Radiological evaluation of chroniclaryngotrachealstenosis. Indian J Otolaryngol Head Neck Surg 57:108–109.
2. Marulli G, Rizzardi G, Bortolotti L, Loy M, Breda C, Hamad A-M, Sartori F, Rea F (2008)
3. Single-staged laryngotracheal resection and reconstruction for benign strictures inadults.
4. Interact CardioVascThoracSurg 7:227–230.
5. Koempel JA, Cotton RT. History of pediatric laryngotracheal reconstruction. *OtolaryngolClin North Am*. 2008;41(5):825-835, vii.
6. Narcy P, Contencin P, Fligny I, Franc¸ois M. Surgical treatment for laryngotrachealstenosis in the pediatric patient.
7. *Arch Otolaryngol Head Neck Surg*. 1990;116(9):1047-1050.
8. Drake AF, Contencin P, Narcy F, Cotton RT. Lateral cricoid cuts as an adjunctivemeasure to enlarge the stenoticsubglottic airway: an anatomic study. *Int J Pediatr*
9. *Otorhinolaryngol*. 1989;18(2):129-137.
10. Seid AB, Pransky SM, Kearns DB. One-stage laryngotracheoplasty.
11. *Arch Otolaryngol Head Neck Surg*. 1991;117(4):408-410.
12. Cotton RT, Myer CM III, O'Connor DM, Smith ME. Pediatric laryngotracheal reconstruction with cartilage grafts and endotracheal tube stenting: the singlestageapproach. *Laryngoscope*. 1995;105(8, pt 1):818-821.
13. Ndiaye I, van den Abbeele T, Franc¸ois M, Viala P, Tanon-Anoh MJ, Narcy P.Surgical management of laryngeal stenosis in children. *Ann OtolaryngolChir*
14. *Cervicofac*. 1999;116(3):143-148.
15. Monnier P, Lang F, Savary M. Partial cricotracheal resection for severe pediatricsubglotticstenosis: update of the Lausanne experience. *Ann OtolRhinolLaryngol*.
16. 1998;107(11, pt 1):961-968.
17. Bent JP, Shah MB, Nord R, Parikh SR. Balloon dilation for recurrent stenosis afterpediatric laryngotracheoplasty. *Ann OtolRhinolLaryngol*. 2010;119(9): 619-627.
18. Koempel JA, Cotton RT. History of pediatric laryngotracheal reconstruction. *OtolaryngolClin North Am*. 2008;41(5):825-835, vii.
19. Polonovski JM, Hertz Panier L, Francois M, Garel C, Hassan M, Narcy P. Balloon dilatation of tracheobronchialstenoses in children: apropos of 4 cases. *Ann Otolaryngol*
20. *ChirCervicofac*. 1991;108(7):411-416.
21. Hebra A, Powell DD, Smith CD, Othersen HB Jr. Balloon tracheoplasty in children:results of a 15-year experience. *J Pediatr Surg*. 1991;26(8):957-961.
22. Quesnel AM, Lee GS, Nuss RC, Volk MS, Jones DT, Rahbar R. Minimally invasiveendoscopic management of subglotticstenosis in children: success and failure.
23. *Int J PediatrOtorhinolaryngol*. 2011;75:652-656.
24. Mirabile L, Serio PP, Baggi RR, Couloigner VV. Endoscopic anterior cricoid split and balloon dilation in pediatric subglotticstenosis. *Int J PediatrOtorhinolaryngol*.2010;74(12):1409-1414.