FUNCTIONAL AND RADIOLOGICAL OUTCOME OFSURGICALLY CORRECTED POSTERIOR COLUMN WITH WALL ACETABULAR FRACTURES
A SHORT-TERM FOLLOW UP

[1]VIRAJ NALAM, [2]VIGNESH GADUPUDI

[1]M.S., [2]M.D.
SRI RAMACHANDRA MEDICAL COLLEGE

LIST OF ABBREVATIONS

AO - ARBEITGEMEINSCHAFT FUR OSTEOSYNTHESEFRAGEN

MDA - MERLE D AUBIGNE

HHS - HARRIS HIP SCORE

ATLS - ADVANCED TRAUMA LIFE SUPPORT

ER - EXTERNAL ROTATION

IR - INTERNAL ROTATION

CT - COMPUTED TOMOGRAPHY

THA - TOTAL HIP ARTHROPLASTY

ORIF - OPEN REDUCTION AND INTERNAL FIXATION

HO - HETEROTOPIC OSSIFICATION

PC - POSTERIOR COLUMN**PW** - POSTERIOR WALL **TV** - TRANSVERSE

AW - ANTERIOR WALL **AC** - ANTERIOR COLUMN**DC** - DOUBLE COLUMN **TS** - T SHAPE

PHTV - POSTERIOR HEMI TRANSVERSE

ABSTRACT

INTRODUCTION

Incidence of pelvic fractures is 37 per 1 lakh population per year. Among them acetabular fractures account to around 3 per lakh population. Due to high energy injuries in younger individuals polytrauma is frequently associated which affects morbidity of the patient significantly whereas older individuals present with an isolated acetabular fracture. Acetabulum being important weight bearing surface of hip joint, fixation of these fractures is extremely important to provide congruous stable painless hip joint to provide early mobilization and to avoid secondary osteoarthritis.

AIM

To study the clinical and radiological outcomes after the posterior wall with column acetabular fractures corrected bysurgical fixation.

MATERIALS AND METHODS

The purpose of this prospective clinical observation was toevaluate outcomes in patients with acetabular fracture treated surgically. We analyzed 11 displaced acetabular fractures managed surgically between 2018 - 2020 in SRMC, Chennai. Patients were followed for a period of 6months- 12 months; without any patientlost to follow- up. Outcome in these patients was evaluated usingHarris Hip Score (HHS) and Matta radiological criteria.

RESULTS

Of the total of 11 patients, 11 were followed for a mean of 1year; none were lost to follow- up postoperatively. Dislocation of the hip was recorded in 6 patients. 3 foot drops observed in my study were preoperatively associated and no iatrogenic foot drop occurred. All three cases associated with hip dislocations. Surgical

site infection occurred in two cases. No any implant failure or non- union observed in my study. The results according to the modified MERLE D' AUBIGNÉ AND POSTEL SCORING SYSTEM was
excellent in 3 patients, very good in 2 patients, good in 4 patients, fair in 1 and poor in 1. Mean HARRIS HIP SCORE at end of 3mon/6mon/12mon was 47.08/64.18/87.45

CONCLUSION

Gold standard treatment is open reduction and internal fixation in dedicated centers by experienced surgeons as soon as possible. Early intervention in case of hip dislocation is important to prevent the chondral damage. Early ORIF is necessary to provide accurate anatomic reduction and joint congruency which can prevent or delay future requirement of THA. Posterior wall and dome of acetabulum parts are most important to reconstruct as they are the weight bearing structures. Associated injuries must be addressed well to improve the overall functional scores. Poor functional results are due to increased age/delay in surgery/complex fracture/ associated transverse component fracture/inappropriate reduction/dome incongruency/polytrauma.

INTRODUCTION

Incidence of pelvic fractures is 37 per 1 lakh population per year. Among them acetabular fractures account to around 3 per lakh population [1,2]. Motor vehicle accident injuries are most common cause for acetabular fractures in young individuals whereas in older individuals trivial trauma can cause them [1,3]. This explains the reason for bimodal age distribution with first peak in 3 rd decade due to high energy fractures and second peak in 6 th decade due to low energy fractures. Due to high energy injuries in younger individuals polytrauma is frequently associated which affects morbidity of the patient significantly whereas older individuals present with an isolated acetabular fracture [3].

Dash- board injury to the flexed knee is the commonest causes for the posterior acetabular wall fractures which are usually associated with posterior hip dislocations. Neurological injury to sciatic nerve occurs in 30% of cases most of them which are partial injury commonly involvingthe peroneal component rather than tibial component. Increased risk of sciatic nerve injury in case of posterior acetabular fractures which require posterior and extensive surgical approach with retraction of sciatic nerve [4,5]. Since the advent of mandatory seat belt use, there has been significant reduction in the incidence of acetabular fractures [6].

Acetabular fractures usually occurs in polytrauma patients which causes increased morbidity in them and hence results in poor outcomes. Non operative treatment of acetabular fractures results in early hip arthritis which increases the requirement of hip replacement surgery [7,8]. Hence acetabular fractures demand early intervention and accurate surgical fixation. The best results in acetabular fracture surgery can be achieved only by experienced surgeons trained in this injuries [9,10] . Fractures of the posterior wall are the most common type of acetabular fractures accounting for approximately 25% of all acetabular fractures [4,11].

Meta-analysis done by **P.V.Giannoudis et al.**[12] in a total of 3670 fractures over the period of 40 years found that acetabular fractures occurred more commonly in young active male population(69%).

In a study done by **Pascarella et al** .[77] in 2017 about isolated posterior wall fractures ,anatomic reduction was obtained in 115(95%)cases, satisfactory in remaining 6(5%) cases. MDA score observed as excellent in 45hips(40.2%)good in 52hips(46.4%)poor in only 8hips(7.1%)They concluded that prompt reduction of hip dislocation and accurate fracture reduction are key factors in better outcome whereas associated injuries and nerve palsy have negative impact on outcomes. In study done by **Briffa et al.** 52.1% cases with isolated posterior wall fractures had excellent outcomes but only 28.57% of cases with posterior wall with transverse column fractures had excellent outcomes. T - shaped fractures combined with a fracture of the posterior wall seem to represent the worst-case scenario in many studies. The associated transverse fracture makes the reduction difficult and hence inap propriate congruency resultsin poor outcomes. Hence isolated posterior wall fractures may have good prognosis but when combined with other acetabular injuries results in poor outcomes.

Due to the close proximity of the sciatic nerve to the posterior acetabular wall and column, sciatic nerve is injured in most of the traumatic posterior dislocations. Those with a combined posterior wall fracture with traumatic dislocation of hip and sciatic nerve palsy had a statistically significant negative impact on out come according to many studies. Hence it is important to reduce and fix posterior acetabular fractures immediately for better outcomes.

The biology of the fracture (primary articular cartilage damage) has now become the limiting factor, which may require primary arthroplasty in selected cases as stated in study by **H.J.Kredal et al** . Hip dislocations occur with posterior acetabular fractures which results in subchondral impaction, intra-articular fragments and comminution which results in severe cartilage damage thus resulting in poor functional outcomes andnecessitates the hip

replacement surgery in few cases.

Acetabulum being important weight bearing surface of hip joint, fixation of these fractures are extremely important to provide congruous stable painless hip joint to provide early mobilization and to avoid secondary osteoarthritis. However due to the reasons of complex anatomy of acetabulum, complicated fracture pattern, difficulty to access fracture site and associated polytrauma adds onto difficulty in positioning the patient intra- operatively. As the posterior wall and column are most commonly involved and contribute to the major weight bearing part of the hip joint, this study conducted to analyze the short term outcome after surgical fixation of the posterior wall and column acetabular fractures.

AIM OF THE STUDY

To study the clinical and radiological outcomes after the posteriorwall with column acetabular fractures corrected by surgical fixation.

OBJECTIVES

1. To study the advantages and disadvantages of surgically correctedposterior acetabular fractures.
2. To study the occurrence of hip arthritis, sciatic nerve injury andassociated vascular injuries following surgery.

MATERIALS AND METHODS

- **STUDY DESIGN**- LONGITUDINAL STUDY
- **STUDY INSTITUTION**- SRI RAMACHANDRA INSTITUTE OFHIGHER EDUCATION AND RESEARCH, PORUR.
- **TIME OF STUDY**- MAY 2018 to AUG 2020
- **TYPE OF STUDY**- PROSPECTIVE STUDY
- **SAMPLE SIZE**- PERIOD STUDY
- **FOLLOW UP**- 6 MONTHS -1 YEAR

INCLUSION CRITERIA

- SKELETALLY MATURE ADULTS (AGE >=18 YEARS)
- ACUTE FRACTURES <= 3 WEEKS OLD
- POSTERIOR WALL ACETABULAR FRACTURES+\POSTERIOR COLUMN FRACTURES
- POSTERIOR WALL ACETABULAR FRACTURES WITHOTHER LONG BONE INJURIES
- FRACTURE DISLOCATION OF HIP JOINT INVOLVINGPOSTERIOR WALL ACETABULAR FRACTURES

EXCLUSION CRITERIA

- AGE <=18 YEARS
- FRACTURES > 3WEEKS OLD
- ASSOCIATED OTHER PELVIC INJURIES
- PATHOLOGICAL FRACTURES
- PREVIOUS HIP SURGERIES

Patients who met all these eligibility criteria he/ she was explained about the aims and objectives of this study and were included after obtaining informed written consent.

Patients and methods

We analyzed 11 displaced acetabular fractures managed surgically between 2018-2020 by the different surgeons in SRMC, Chennai. Patients

were followed for a period of 6months-12 months; without any patient lostto follow-up.

An acetabular admission protocol for all local and inter-hospitaltransfer was followed; data recorded included the mechanism of injury, classification of the fracture, associated injuries, complications and comorbidities. Standard plain radiographs, including anteroposterior pelvis, obturator oblique and iliac oblique views, as well as CT scans, were obtained to assess and classify all fractures preoperatively according to **Judet et al**.[26] (Fig 6).

- AP view-to identify acetabular injury and other associated pelvicinjuries (Fig 8 A)
- Iliac view-to assess the posterior column and anterior wall (Fig 8B)
- Obturator view-to assess anterior column and posterior wall (Fig 8C)

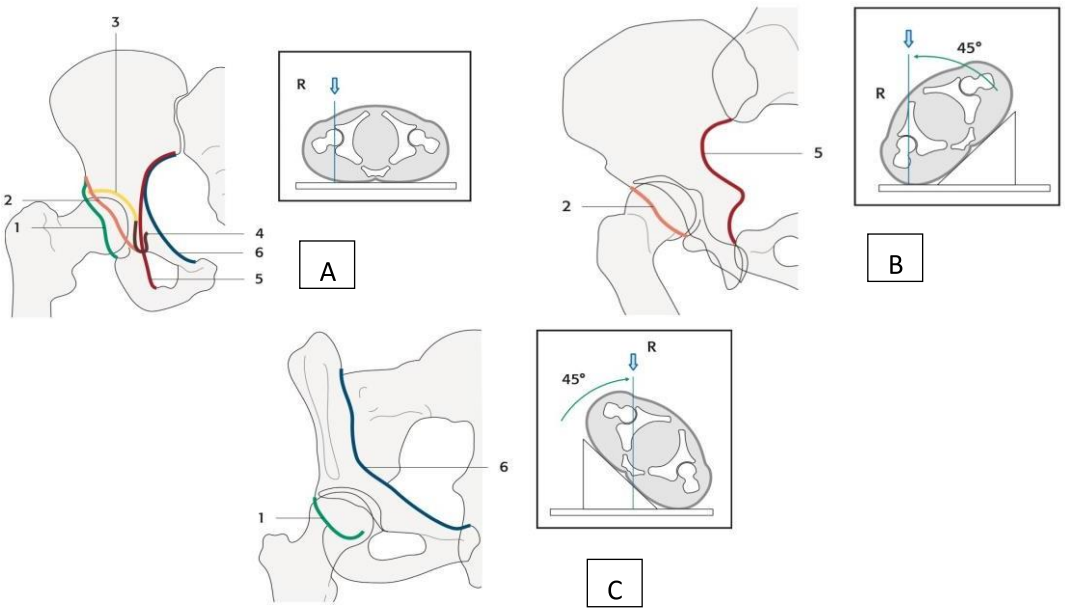

Fig 1: The six fundamental radiographic landmarks of Leutornel

1.Posterior wall	2.Anterior wall.	3.Dome.
4.Teardrop.	5.Posterior Column.	6.AnteriorColumn.

- The iliopectineal line represents the pelvic brim and is the radiological landmark for anterior column.
- The ilioischial line represents the posterior portion of quadrilateral surface and is the radiological landmark for posterior column.
- Anterior rim (lateral margin of anterior wall) is slightlyhorizontal and medial to the posterior rim(lateral margin ofposterior wall).
- Tear drop has medial and lateral limbs which represent the obturator canal and antero inferior acetabular wall respectively. Increased gap of the medial femoral surface to the tear drop is seen in hip dislocation.
- Fracture line passing through the roof of acetabulum means it involves the weight bearing portion.

CT evaluation (Fig 9):

Preoperatively CT scans done to assess

A. Articular incongruency and step-off
B. Size and number of posterior wall fragments
C. Marginal impaction
D. Intraarticular fragments
E. Rotation and displacement of columns.

Axial CT can be used for better imaging of the fracture

Pattern

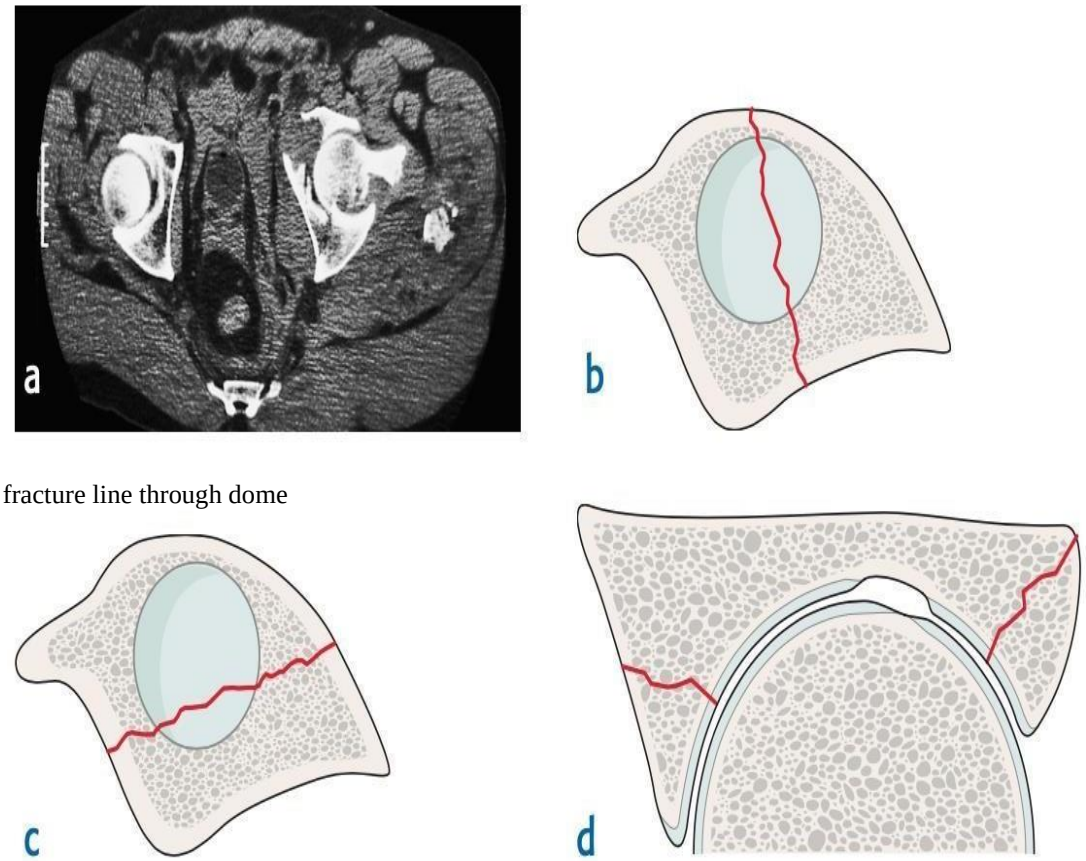

Vertical (coronal) fracture line through dome

Transverse (sagittal) fracture line

Fracture lines traversing anterior and posterior walls, as shown on CT

Fig 2: CT sections showing acetabular fracture patterns

Timing of surgery

Any associated hip dislocation was considered as emergency and taken up for immediate hip closed reduction under sedation. Skeletal traction was applied until definitive fixation is done to prevent recurrence of hip dislocation and further cartilage damage. Irreducible reductions/incarcerated intra articular fragment/ unstable posterior dislocations/ progressive sciatic nerve palsy are taken for emergency surgery.

Average time duration in our study was 3- 5 days after injury once the general condition of patient is optimized. Delay in surgery did not exceed more than 14 - 21 days beyond which would result in unsatisfactory reductions.

Factors considered in our cases to take up for surgery

1. Joint incongruency with >2mm articular step-off.
2. Posterior wall fractures involving >50% of surface.
3. If posterior wall fracture fragment <50%,then intraoperative joint stability is assessed with hip in 90 deg flexion.
4. Roof arc angle <45%- medial/anterior/ posterior roof arc (According to **MATTA**) had increased involvement of dome of the acetabulum weight bearing portion. Hence were taken up for surgery.
5. Incarcerated fragments/ marginal impaction of femoral articular surface.
6. Irreducible hip dislocation.

Operative protocol: The primary goal was anatomical reduction with stable fixation as early as possible. Intra - operatively, patients were routinely catheterized. No intra- operative nerve monitoring was used. Single surgical approach used was Kocher Langenbeck approach for all of our cases which had posterior acetabular fractures. Trochanteric and posterior wall osteotomies were not done in any of our cases.

Intra- operative fluoroscopy was used to assess reduction and ensure that the metal work did not transgress the hip joint. Both accuracy of reduction and minimal extensive approaches [6] were taken as criteria for better outcomes. None of our patients required immediate arthroplasty of the hip. In patients with a pre- operative sciatic nerve palsy, intra- operative exploration of the nerve was undertaken.

Position and approach

- All our patients were put in lateral decubitus position(Fig 3).
- Kocher-Langenbeck approach was used in all cases(Fig 4,5).

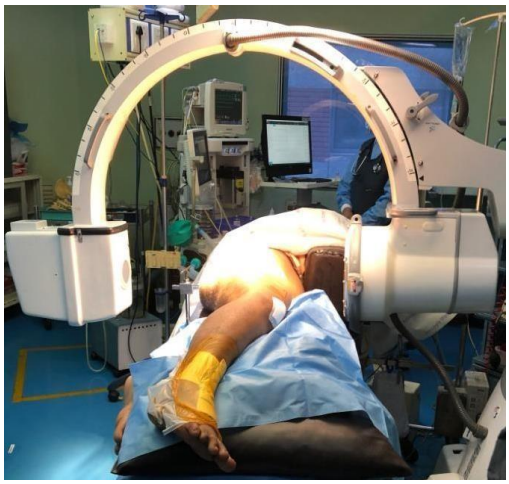

Fig 3: Lateral decubitusposition

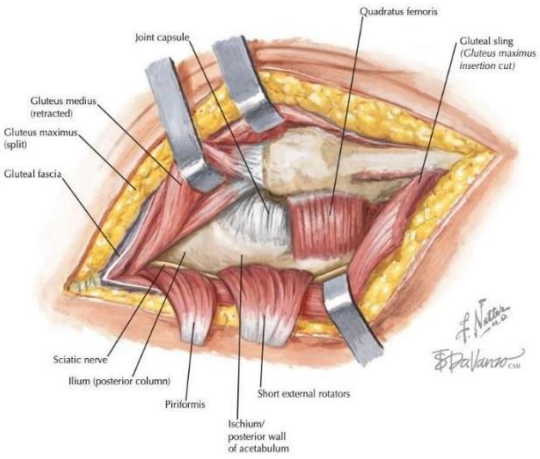

Fig 4:Kocher Langenbeckapproach

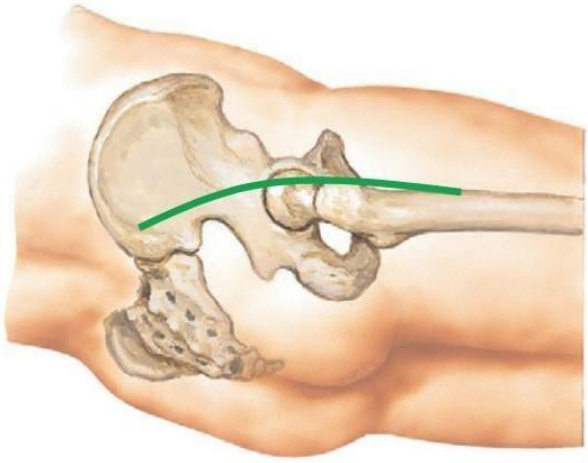

Fig 5: Skin incision for posterior acetabular surgery

Reduction technique

- Intra- operative traction was given to reduce the fracture fragments having capsular attachments (one in sciatic buttressand other in femoral head (Fig 6).
- Joint space was palpated for any intra- articular fragments which were removed / marginal impaction for which bone grafting was done.
- Ball spike was used to hold fracture fragments in place an dstabilized with kirshner wires.

- Headless compression screws were used as LAG screw toprovide compression at fracture site.

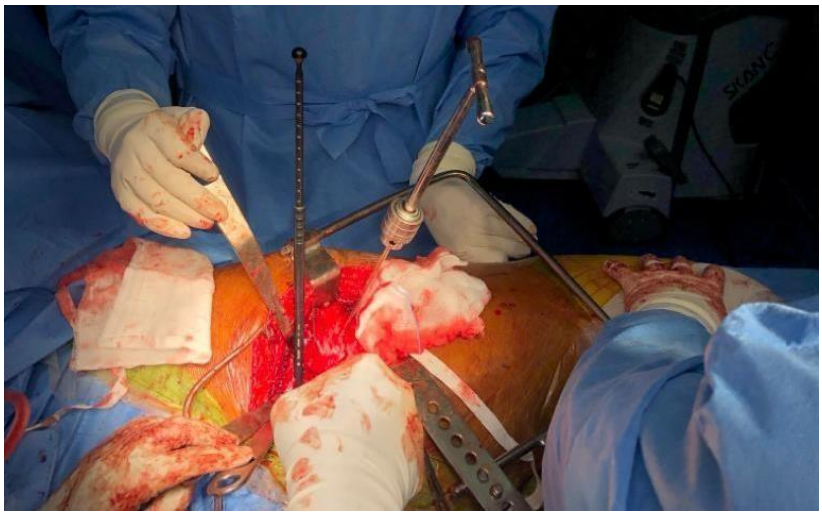

Fig 6: Intra operative traction using Steinman pin

- Recon plates were contoured to accommodate posterior acetabularsurface(Fig 14 a/ b).
- Posterior buttress plates were applied and fixation with corticalscrews above into ilium and below into ischium.
- Intraoperative fluoroscopy was used to check any screw penetrationinto joint space.



Undercountered Posterior Acetabular Buttress Plate Overcontoured (overbent) plate.

Fig 7: Acetabular Recon plates

- In case of column with wall fractures-first fixation of column wasdone followed by fixation of wall.

- In associated transverse component fracture, two cortical screws were inserted into both columns and screw- holding forceps was applied and rotational displacement was corrected. LAG screw was

then applied through the plate into anterior column for increased stability (Fig 15 a/b).

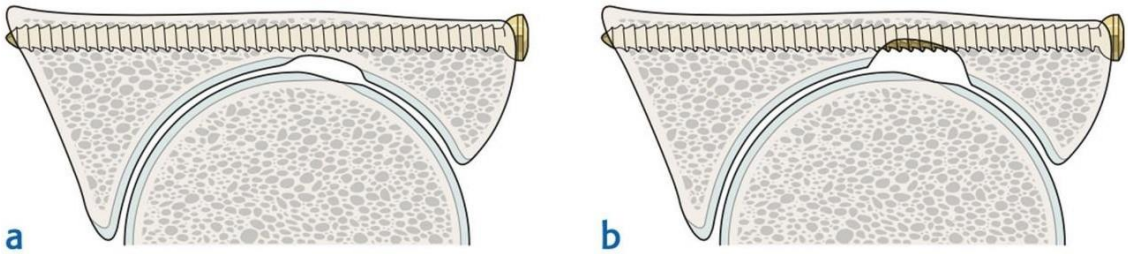

Optimal position for a lag screw. Screw penetrating into cotyloid fossa.

Fig 8: LAG screw in acetabular surgery

Assessment of reduction and fixation

- The quality of reduction was noted intra-operatively and graded by the senior surgeon as anatomical, acceptable or non-anatomical(Table 4).The reduction was categorized as anatomical when all imperfections were corrected and noted by direct visualization and/ or intra- operative imaging when the approach precluded direct visualization of the fracture. Hip movements and stability in all planes were checked. Digital palpation along quadrilateral surface through greater or lesser sciatic notch done to check adequacy of reduction.
- An acceptable reduction was where the hip was congruent. A nonanatomical reduction was noted when there was still residual subluxation of the hip and loss of parallelism of the femoral head in relation to the roof of the acetabulum.

Post-operatively, anteroposterior pelvic and Judet views were obtained to categorise the quality of the reduction into three groups: anatomical, congruent and incongruent, using Matt a's radiological principles[11]. The reduction was categorized as anatomical if all fracture gaps and steps had been removed intra- operatively, and postoperative films showed restoration of all five anatomical lines (ilioinguinal, ilio- pectineal,dome, posterior wall and anterior wall) with the head centered and parallel beneath the acetabular roof. A congruent reduction is best judged on the anteroposterior film, which is useful in assessing the hip with reference to both the congruency and anatomy of the contralateral normal joint. Patients with poor restoration of the five pelvic lines, inward sub -luxation of the hip and loss of parallelism were included

in the incongruent group.

Postoperative protocol

Post-operatively, to reduce the risk of heterotopic ossification, all patients received indomethacin 50 mg three times a day for two weeks, reducing to 25 mg three times a day for four weeks, combined with a pain management protocol [4]. Anticoagulation prophylaxis involved t headministration of low molecular weight heparin pre-, peri- and post- operatively. All patients were subsequently prescribed aspirin for three months.

In bed mobilization started as early as 24 - 48 hrs. Non weight bearing is encouraged once the general condition is optimized and continued for 2 months after surgery. Full weight bearing was started 3 months after surgery when union is confirmed radiologically.

All patients were followed up clinically and radiologically at six and 12 weeks, 6 months and one year, Functional outcome scores, the HHS (Table 1) at 3mon/6mon/1year and the modified Merle D'Aubigné andPostel score (Table 2)[54] were recorded at the final follow-up.

Table 1: HARRIS HIP SCORE

A.Pain	B.Gait/limp	C.Support	D.Distance	E.Stairs
None - 44	None-11	None-11	Unlimited-11	Normal-4
Slight Occasional-40	Slight-8	Cane for long walks-7	6 blocks-8	Normalwith banister-2
Mild Normal activity-30	Moderate-5	Cane fulltime-5	2 or 3 blocks -5	Any method-1
Moderate, activity concessions-20	Unable to walk-0	Crutch-4	Indoors only -2	Unable-0
Marked,severe concessions-10		Two canes-2	Bed andchair-0	
Totally Disabled- 0		Unable towalk-0		

G.Socks and Shoes.	H.Sitting.	I.Public Transport.	J.Deformity.	K.Range of motion
Easy -4	Any chair 1 hour- 5	Able-1	Absence of all4 deformities -4	Full -5
With difficulty-2	High chair 30 minutes3	Not able touse -0	Presence of 1 deformity -0	Partial-4
Unable-0	Unable to sit for 30 minutes-0			Limited-2

Page 1 of 1

HARRIS HIP SCORE

PATIENT ID: ☐☐☐

GENERAL INFORMATION

PATIENT INITIALS: (If there is no middle initial please use "X") ☐☐☐

VISIT DATE: ☐☐ / ☐☐☐ / ☐☐☐☐ (D D / M M M / Y Y Y Y)

OPERATIVE SIDE: (use one form per side) ○ Right ○ Left (Check One)

VISIT : ○ Pre-Op ○ 6 Weeks ○ 1 Year ○ 2 Year ○ 5 Year

I. PAIN

A. PAIN (Check One)

- ○ None, or ignores it
- ○ Slight, occasional, no compromise in activities
- ○ Mild, no effect on average activities, rarely moderate pain with unusual activity, may take aspirin
- ○ Moderate pain, tolerable but makes concessions to pain. Some limitations of ordinary activity or work. May require occasional pain medication stronger than aspirin
- ○ Marked pain, serious limitation of activities
- ○ Totally disabled, crippled, pain in bed, bedridden

II. FUNCTION / GAIT

B. LIMP (Check One)

- ○ None
- ○ Slight
- ○ Moderate
- ○ Severe or unable to walk

C. SUPPORT (Check One)

- ○ None
- ○ Cane, long walks
- ○ Cane, most of the time
- ○ One crutch
- ○ Two canes
- ○ Two crutches or walker
- ○ Unable to walk

D. DISTANCE WALKED (Check One)

- ○ Unlimited
- ○ Six blocks
- ○ Two or three blocks
- ○ Indoors only
- ○ Bed and chair only

III. FUNCTIONAL ACTIVITIES

E. STAIRS (Check One)

- ○ Normally without using a rail
- ○ Normally using a railing
- ○ In any manner
- ○ Unable to use stairs

F. SOCKS / SHOES (Check One)

- ○ With ease
- ○ With difficulty
- ○ Unable

G. SITTING (Check One)

- ○ Any chair, 1 hour
- ○ High chair, 1/2 hour
- ○ Unable to sit comfortably in any chair

H. PUBLIC TRANSPORTATION (Check One)

- ○ Able to use
- ○ Not able to use

I. DEFORMITY (Operative side only)

	Yes	No		
Fixed adduction	○	○	If yes	☐☐☐ degrees
Fixed internal rotation in extension	○	○	If yes	☐☐☐ degrees
Leg length discrepancy	○	○	If yes	☐☐.☐ mm
Pelvic flexion contracture	○	○	If yes	☐☐☐ degrees

IV. RANGE OF MOTION

Perform these measurements on the operative hip. Record 10 degrees of fixed adduction as -10 degrees of abduction and 10 degrees of adduction

Similarly, record 10 degrees of fixed rotation as -10 degrees of internal rotation and 10 degrees of external rotation

Also similarly, record 10 degrees of fixed external rotation with 10 degrees additional external rotation as -10 degrees of internal rotation and 20 degrees of external rotation

1. PERMANENT (FIXED) FLEXION ☐☐☐ degrees
2. FLEXION TO ☐☐☐ degrees
3. ABDUCTION TO ☐☐☐ degrees
4. ADDUCTION TO ☐☐☐ degrees
5. EXTERNAL ROTATION IN EXTENSION TO ☐☐☐ degrees
6. INTERNAL ROTATION IN EXTENSION TO ☐☐☐ degrees

V. COMMENTS

_____

Table 2: MERLE D AUBIGNE' AND POSTEL METHOD SCORE

Points	PAIN	MOBILITY	ABILITY TO WALK
0	Intense and permanent	Ankylosis of the hip in abnormal position.	Not able to walk.
1	Severe and disturbed sleep.	Ankylosis in normal position.	Only withcrutches.
2	Severe when walking and prevents any activity.	o Flexion <40	Only with 2 canes.
3	Severe but tolerated with limited activity.	Flexion between 40 and 60.	Limited with one cane (< 1 hr)
4	Mild pain when walking.	Flexion between 60 and 80.	Long time with cane, Limited without cane.
5	Mild pain but with normal activity.	Flexion between 80 and 90, o abduction of 15.	Without cane but slight limp.
6	No pain.	Flexion >90, abductionof 30.	Normal.

(**Excellent** 18)-(**Very Good** 17)-(**Good** 15/16)-(**Fair** 13/14)-(**Poor**-<13)

Table 3: MATTA RADIOLOGICAL CRITERIA

Displacement.	Grade of reduction.
Zero or 1mm	Anatomical.
2-3mm	Satisfactory.
>3mm	Unsatisfactory.

- The plain radiographs made after surgery were reviewed to assess reduction according to **Matta et al.**(1986) criteria(Table 3).
- **Ethical considerations**: Study was approved by the institutional human ethics committee. Informed consent was obtained from all the study participants. Confidentiality of the study participants was maintained.
- **Statistical method**: The statistical analysis was performed using the SPSS software version 19. The descriptive analysis was performed to estimate Mean, SD, and percentages. Unpaired t test was employed to compare mean values between the groups. Chi- square test was used to compare the percentage between the groups. The statistical significance was fixed at 5%.

CASE ILLUSTRATIONS

CASE 1

AGE:- 48 YEARS/M MOI:- RTA.

DIAGNOSIS:-LEFT ISOLATED ACETABULAR POSTERIOR WALL **FRACTURE. SURGERY:-** 1.LEFT HIP CLOSED REDUCTION.2.LEFT ACETABULAR RECON PLATING.

IMPLANTS USED:- 8 HOLE RECON PLATE

HIP DISLOCATION:- PRESENT.

FOOT DROP:- ABSENT.

Preop Xray

Prereduction CT images

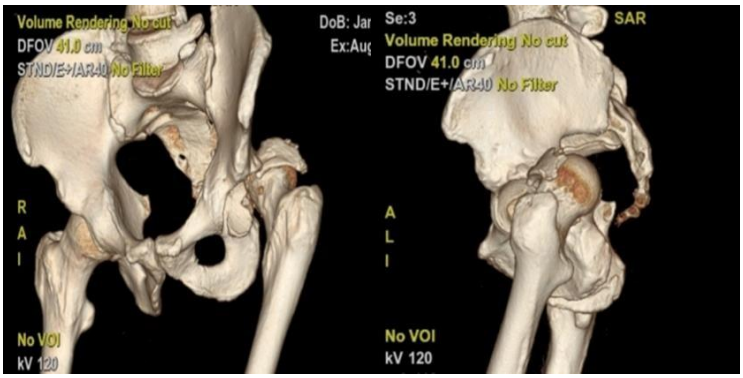

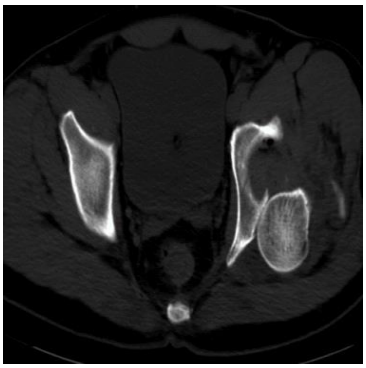

Immediate Post-OP(Matta's Criteria-Anatomical Reduction)

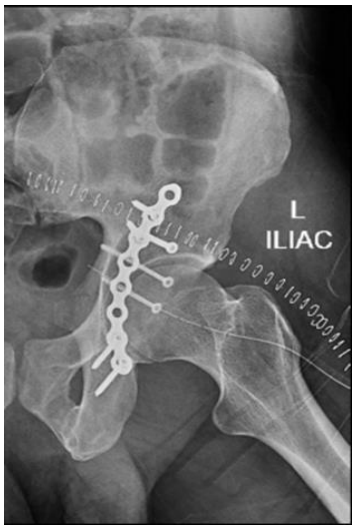

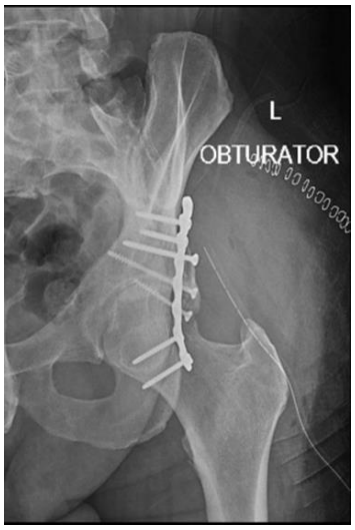

3 MONTHS FOLLOW UP

ONE YEAR FOLLOW UP

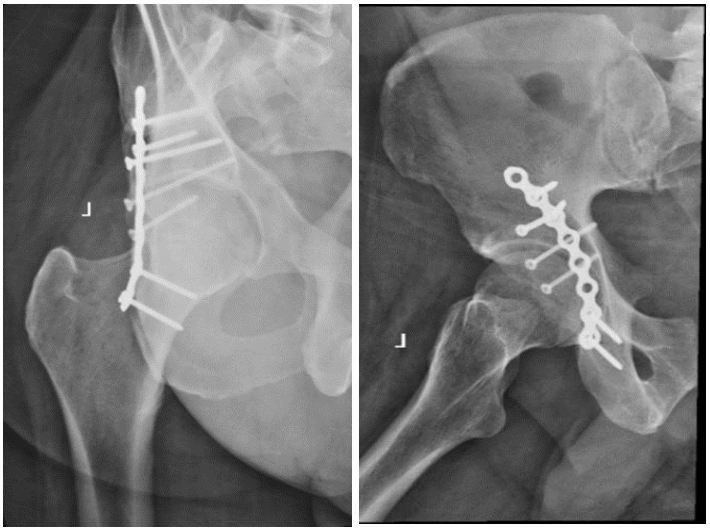

MDA-EXCELLENT.

HARRIS HIP SCORE 3 MON-56 /6 MON-70 / 1 YEAR-95

CASE 2

AGE:-30 YEARS/M

MOI:- RTA.

DIAGNOSIS:- LEFT ACETABULAR POSTERIOR COLUMN FRACTURE.

SURGERY:- LEFT ACETABULAR RECON PLATING. **IMPLANTS USED:-** 8 HOLE PELVIC RECON PLATE. **HIP DISLOCATION:-** ABSENT.

FOOT DROP:- ABSENT.

COMPLICATION:-LIMB LENGTH DISCREPENCY.

PREOP XRAY

PREOP CT

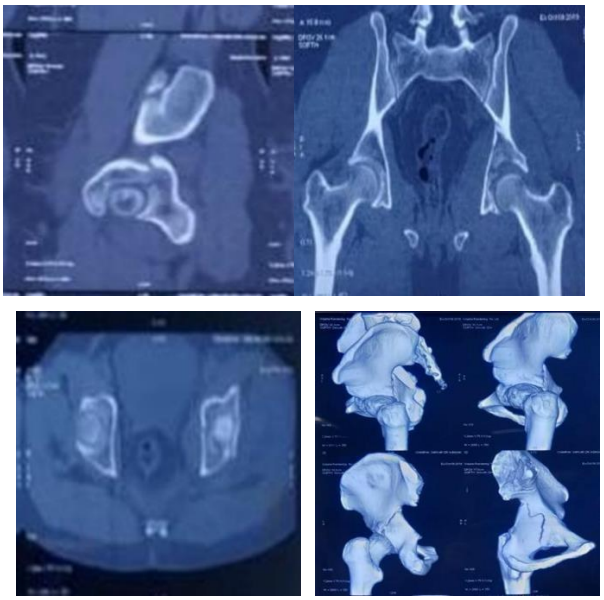

Immediate Post-OP (Matta's Criteria-Anatomical Reduction)

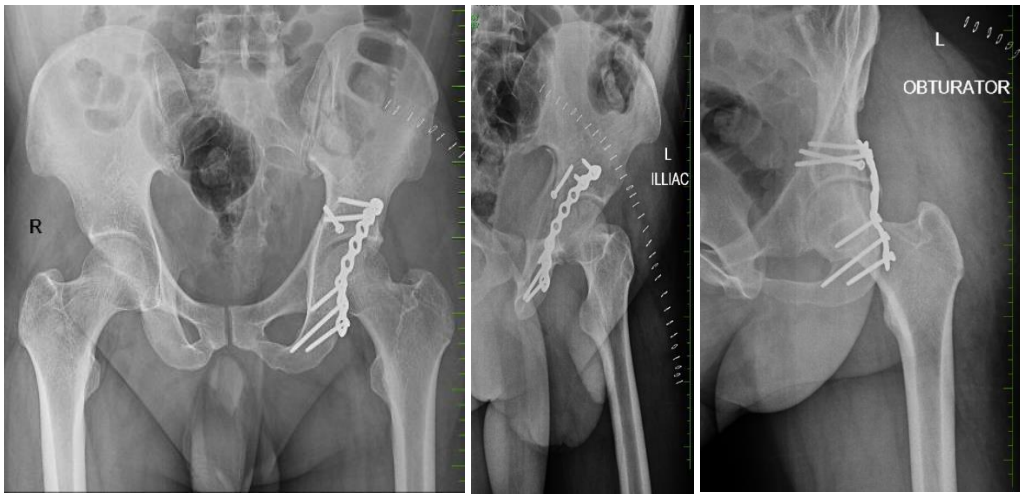

3 MONTHS FOLLOW UP

ONE YEAR FOLLOW UP

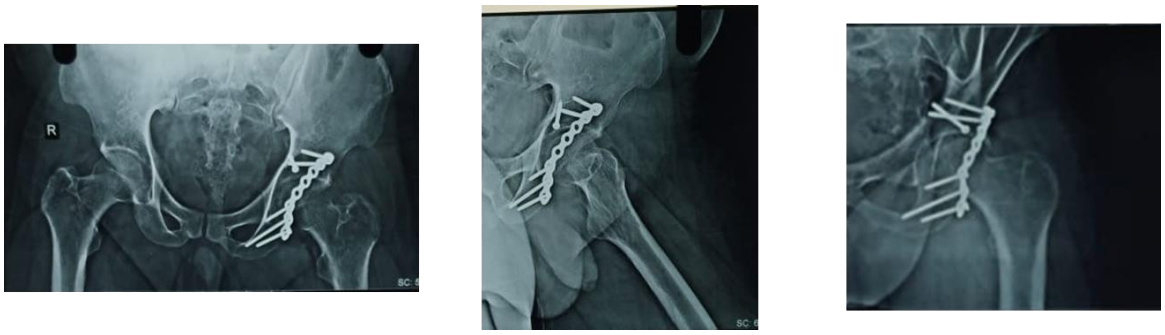

MDA-VERY GOOD.

HHS - 3 MON -55/ 6 MON -66/ 1 YEAR-88

CLINICAL PICTURES

CASE 3

AGE:- 23 YEARS/M

MOI:- RTA.

DIAGNOSIS:- RIGHT ISOLATED POSTERIOR WALL ACETABULARFRACTURE.

SURGERY:- RIGHT ACETABULAR RECON PLATING

IMPLANTS USED:- 7 HOLE RECON PLATE HIP

DISLOCATION:- ABSENT.

FOOT DROP:- ABSENT.

PREOP XRAY

PREOP CT

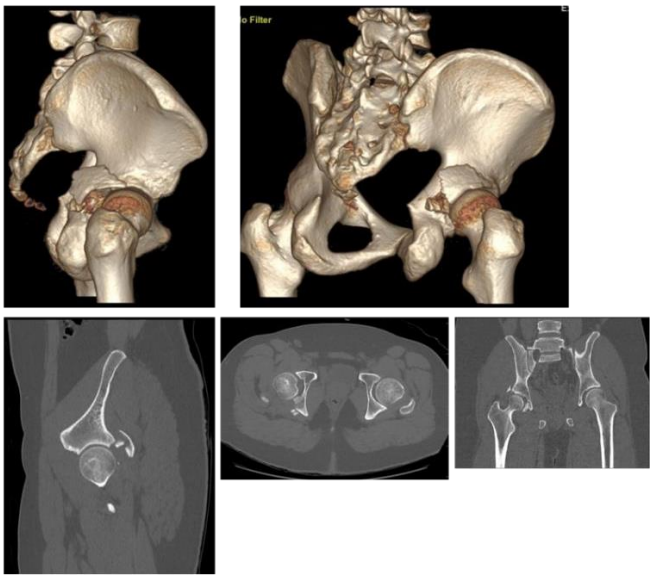

INTRA OP IMAGES

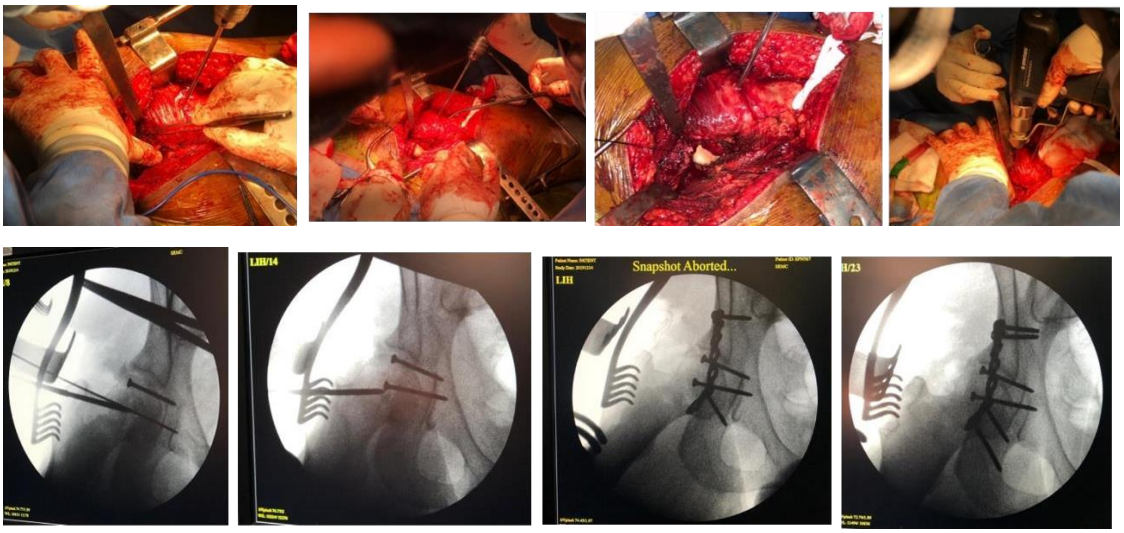

Immediate Post-Op (Matta's Criteria Anatomic Reduction)

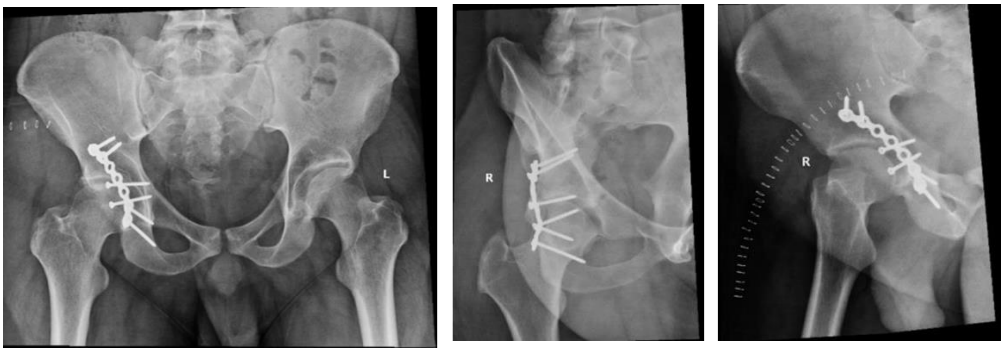

3 MONTHS FOLLOW UP

HARRIS HIP SCORE 3 MON -54/ 6 MON -68/ 1 YEAR-94MDA-EXCELLENT

CASE 4

AGE:- 24 **YEARS/MMOI:-** RTA

DIAGNOSIS:-LEFT ISOLATED POSTERIOR WALL ACETABULARFRACTURE + LEFT PATELLA FRACTURE

SURGERY:- LEFT ACETABULAR RECON PLATING.

IMPLANTS USED:- 8 HOLE RECON PLATE.

HIP DISLOCATION:-PRESENT.

FOOT DROP:- PRESENT.

ASSOCIATED INJURY:- LIVER LACERATION.

PREOP CT IMAGES

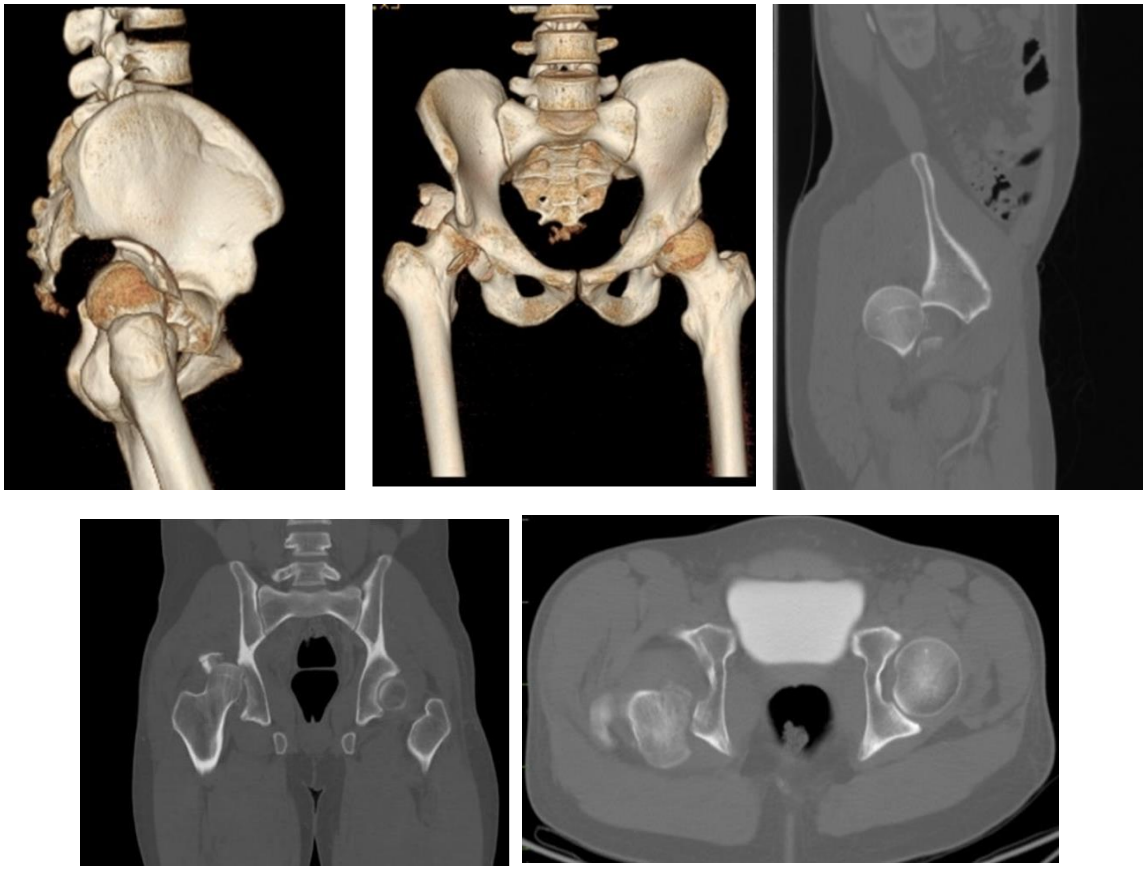

Immediate Post-Op (Matta's Criteria Anatomic Reduction)

3 MONTHS FOLLOW-UP **6 MONTHS FOLLOW-UP**

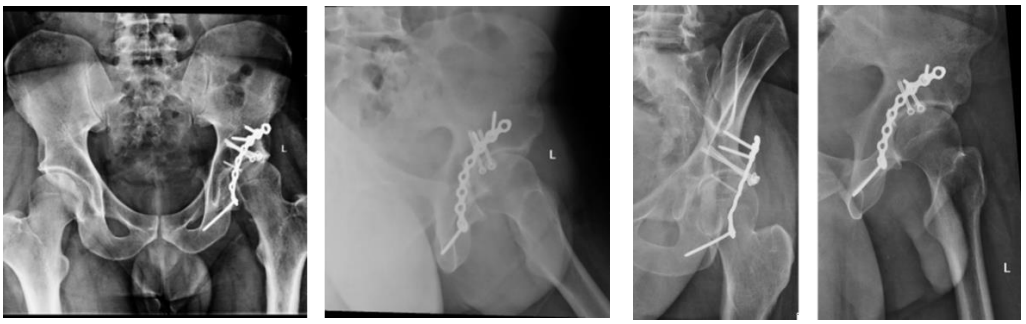

9 MONTHS FOLLOW-UP **1 YEAR FOLLOW UP**

HARRIS HIP SCORE- 3 MON -54/ 6 MON – 71/ 1 YEAR -99MDA-EXCELLENT

CLINICALPICTURES

CASE 5

AGE:- 19 YEARS/M

MOI:- RTA

DIAGNOSIS:-LEFT ACETABULAR POSTERIOR WALL WITHCOLUMN FRACTURE AND TRANSVERSE + LEFT
TIBIA FRACTURE + LEFT FEMUR FRACTURE.

SURGERY:-LEFT FEMUR RETROGRADE NAILING + LEFT ACETABULUM RECON PLATING.

IMPLANTS USED:-10 HOLE PELVIS J-PLATE

HIP DISLOCATION:- ABSENT

FOOT DROP:- ABSENT

COMPLICATIONS:- FEMUR NON UNION

PRE OP XRAY

PREOP CT IMAGES

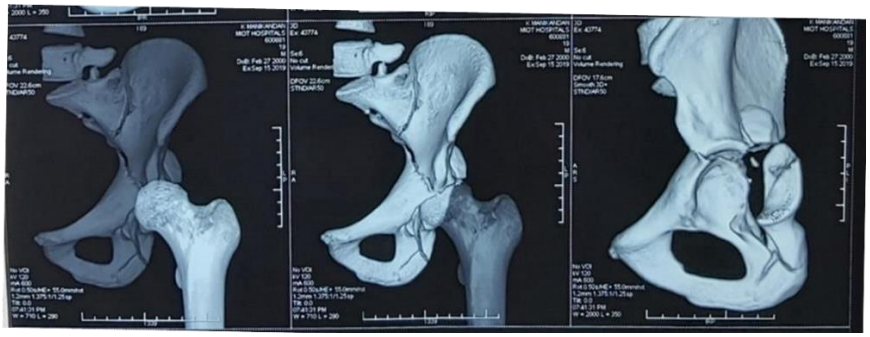

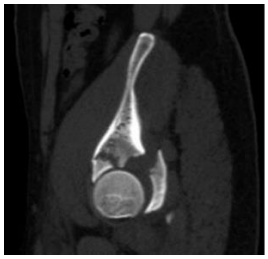

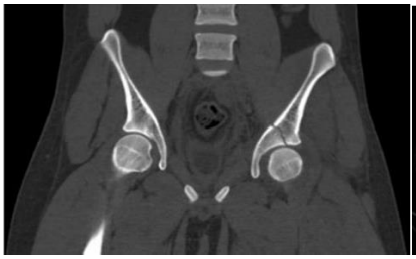

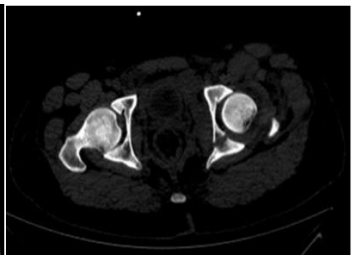

IMMEDIATE POST OP MATTA' S CRITERIA- ANATOMICREDUCTION

IPSILATERAL FEMUR NAILING

3 MONTHS POST-OP

6 MONTHS POST-OP

1 YEAR POST-OP

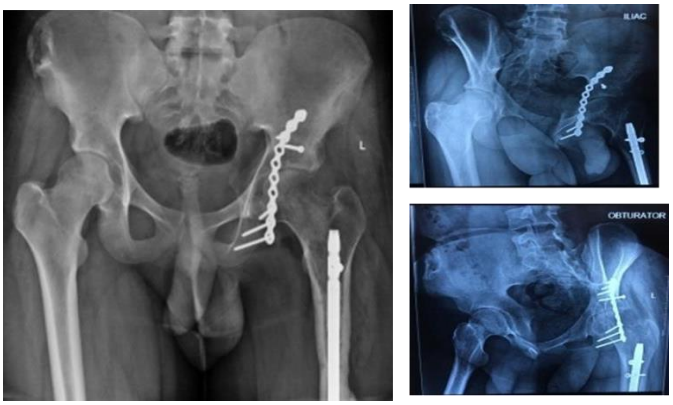

HHS - 3 MON -50/ 6 MON -62/ 1 YEAR -80MDA - FAIR

CLINICAL PICTURES

CASE 6
AGE:- 52 YEARS/F
MOI:- RTA.
DIAGNOSIS:- LEFT ACETABULAR POSTERIOR WALL WITH TRANSVERSE FRACTURE + LEFT DISTAL RADIUS FRACTURE.
SURGERY:- LEFT ACETABULAR RECON PLATING.
IMPLANTS USED:- 8 HOLE RECON PLATE + HEADLESS COMPRESSION SCREWS.
HIP DISLOCATION:-PRESENT.
FOOT DROP:- ABSENT.
COMPLICATIONS:-DISUSE OSTEOPENIA.
PREOP XRAY

PREOP CT IMAGES

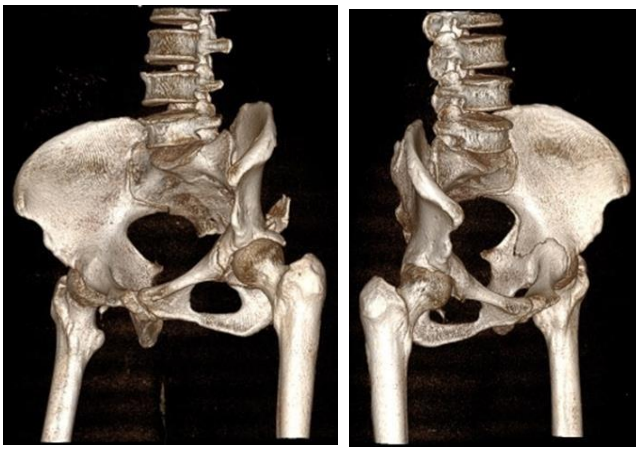

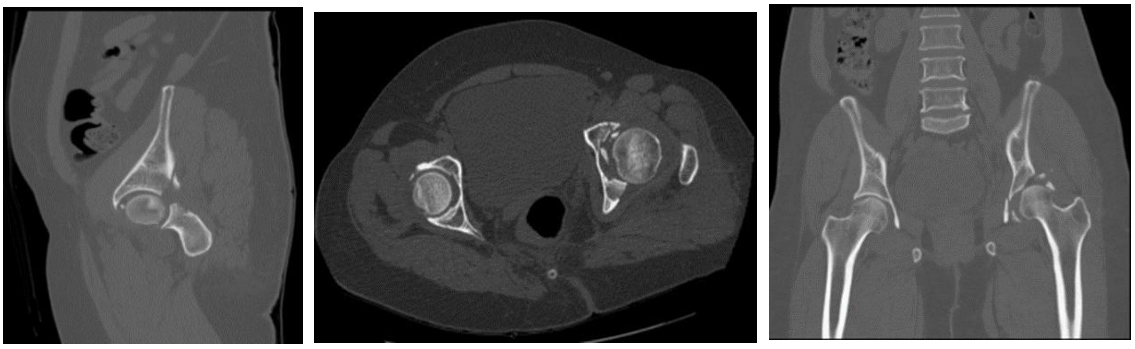

INTRA OP IMAGES

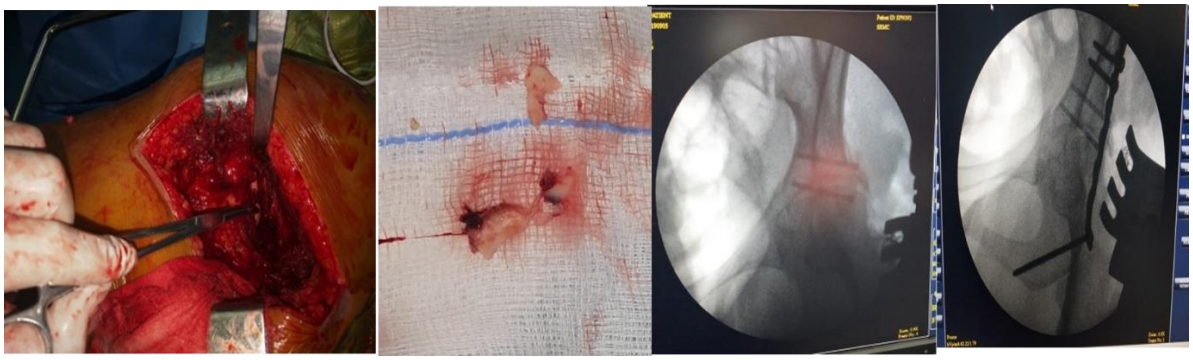

Immediate Post OP Matta's Criteria-Unsatisfactoryreduction

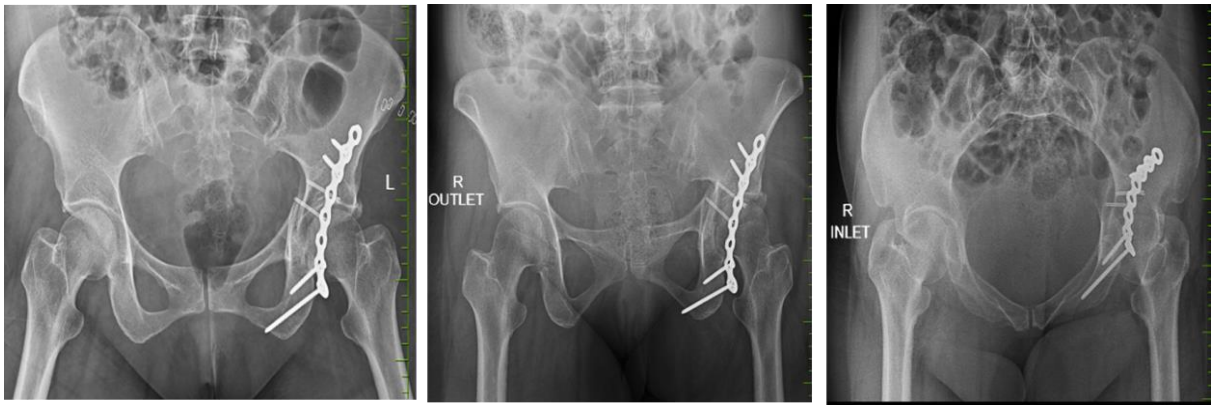

6 MONTHS POST-OP

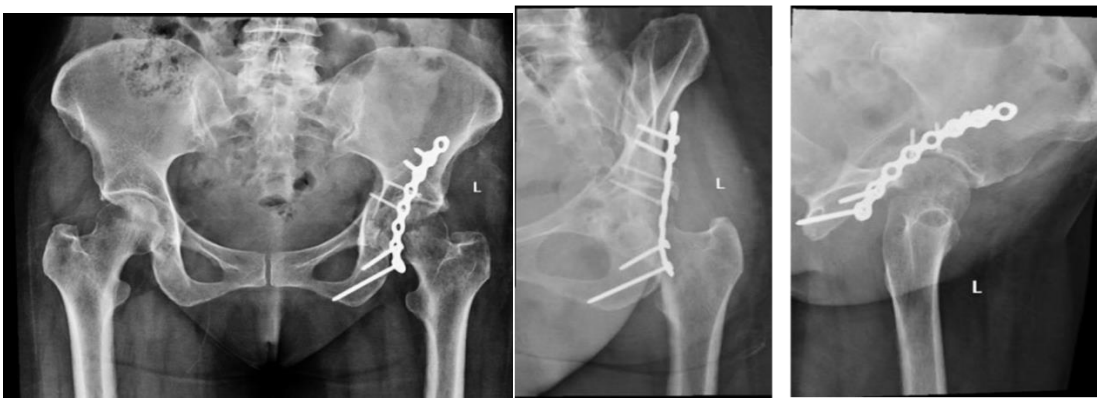

1 YEAR POST-OP

MDA- GOOD.

HHS 3 MON.-28 / 6 MON.-52 / 1 YEAR-74

CLINICAL PICTURES

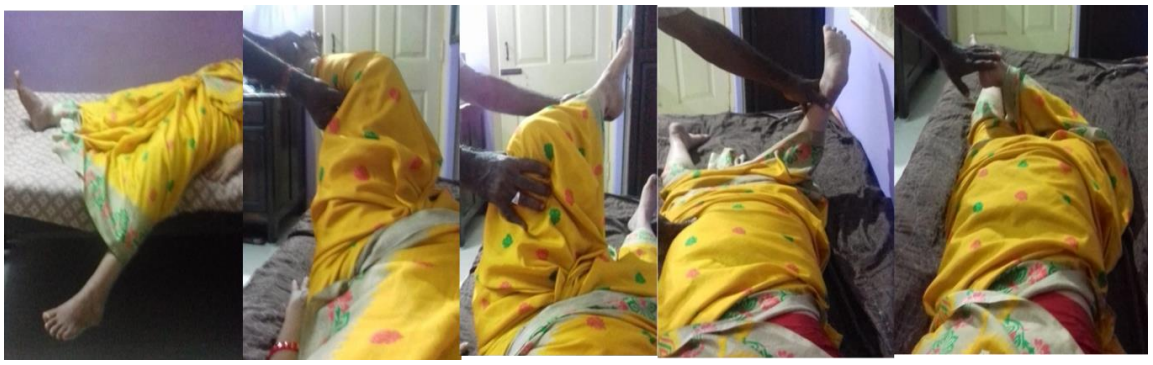

CASE 7

AGE:- 44 YEARS/M. MOI:- RTA.

DIAGNOSIS:- RIGHT COMMINUTED POSTERIOR WALL + TRANSVERSE ACETABULAR FRACTURE + RIGHT PATELLA FRACTURE + RIGHT PROXIMAL TIBIA FRACTURE.

SURGERY:- RIGHT ACETABULAR RECON PLATING + RIGHT PATELLA PLATING + RIGHT PROXIMAL TIBIA PLATING.

IMPLANTS USED:- 6 HOLE AND 8 HOLE RECON PLATES. HIP

DISLOCATION:-ABSENT.

FOOT DROP:- ABSENT.

COMPLICATIONS:- SURGICAL SITE INFECTION.

PRE OP XRAY

PREOP CT IMAGES

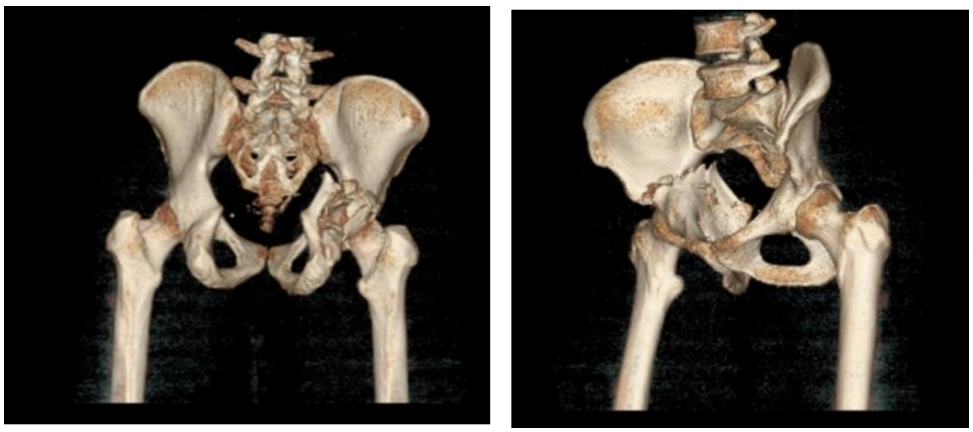

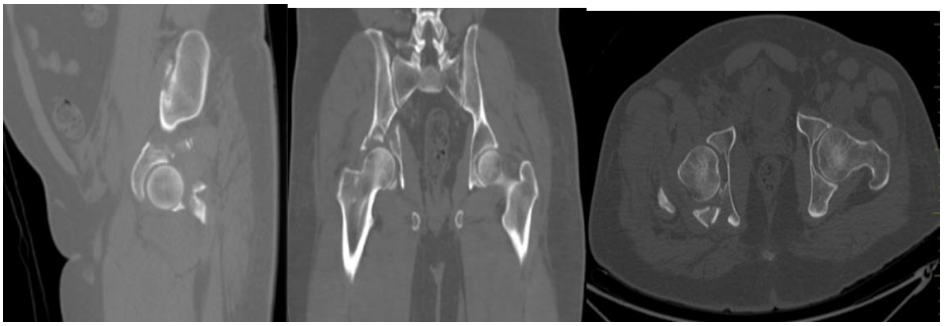

Immediate Post-OP Matta's Criteria-Satisfactory

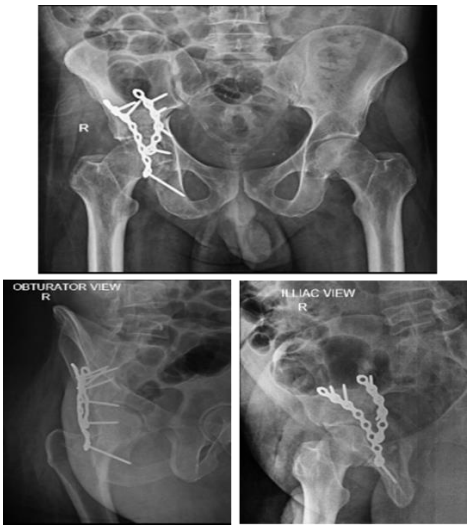

3 MONTHS POST-OP

6 MONTHS POST-OP

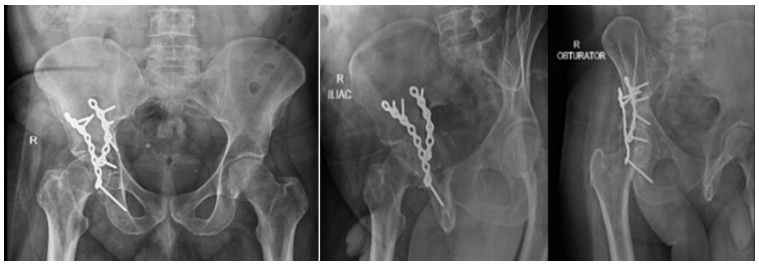

1 YEAR FOLLOWUP

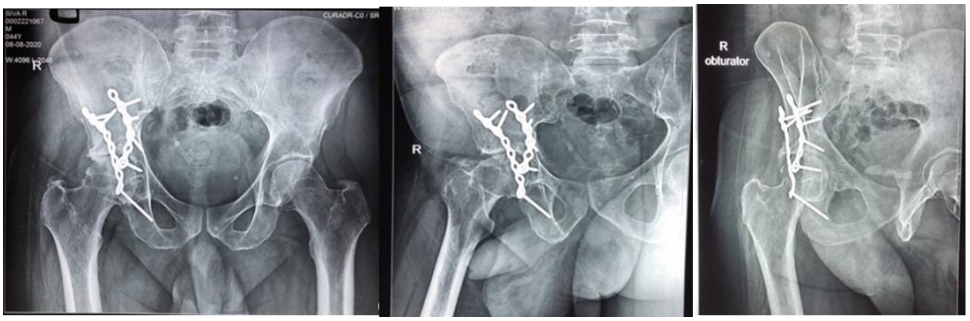

HHS-3 MON-50 / 6 MON-67 / 1 YEAR-93MDA- VERY GOOD

CLINICAL PICTURES

CASE 8
AGE:- 33 YEARS/M MOI:- RTA.
DIAGNOSIS:- RIGHT POSTERIOR WALL WITH COLUMN ACETABULAR FRACTURE + RIGHT DISTAL FEMUR FRACTURE.
SURGERY:- RIGHT ACETABULAR RECON PLATING.
IMPLANTS USED:- 10 HOLE RECON PLATE + HEADLESS COMPRESSION SCREWS.
HIP DISLOCATION:-PRESENT.
FOOT DROP:- ABSENT.
COMPLICATIONS:-KNEE STIFFNESS

PREOP XRAY

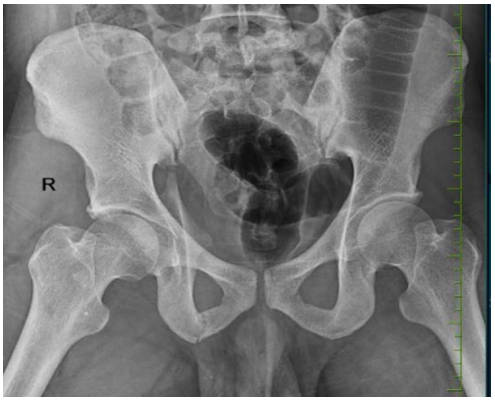

PREOP CT IMAGES

IMMEDIATE POST-OP

3 MONTHS POST-OP

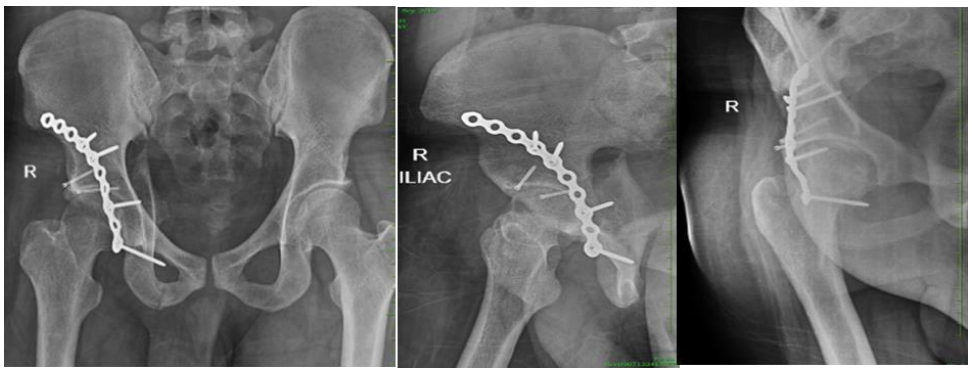

6 MONTHS FOLLOW-UP

1 YEAR FOLLOW UP

MDA-POOR

HARRIS HIP SCORE- 3 MON-49 / 6 MON-58 / 1 YEAR-69

CLINICAL PICTURES

OBSERVATION AND RESULTS

- In our study we observed cases in a prospective manner, all of which were primarily underwent acetabular surgery in Sri Ramachandra hospital, Chennai by different surgeons from May-2018 upto Aug-2020 who all satisfied our inclusion and exclusion criteria for the follow up period of our study. This included a total of 11 cases, none of which were lost to follow up nor reported any deaths.

AGE DISTRIBUTION VS FREQUENCY

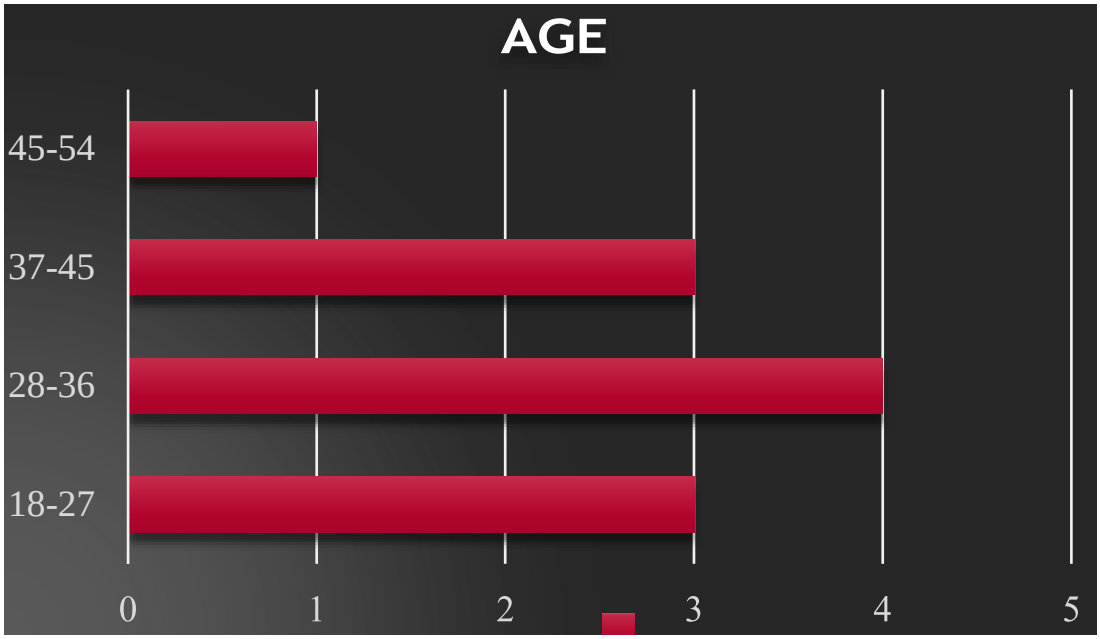

Fig 16: Bar chart of age wise distribution of patients (N=11)

In our study a total of 11 acetabular surgeries were included. 3 cases between age group 18 - 27Y,4 cases in age group 28 -36Y,3 cases in age group 37- 45Y and 2 cases in age group 46 - 54Y(Fig 16). The maximum number of patients were from middle age group with youngest age being 19 years and oldest age being 52 years with a mean age of 34.3 years. Follow up period was from 6-12months.

SIDE OF INJURY

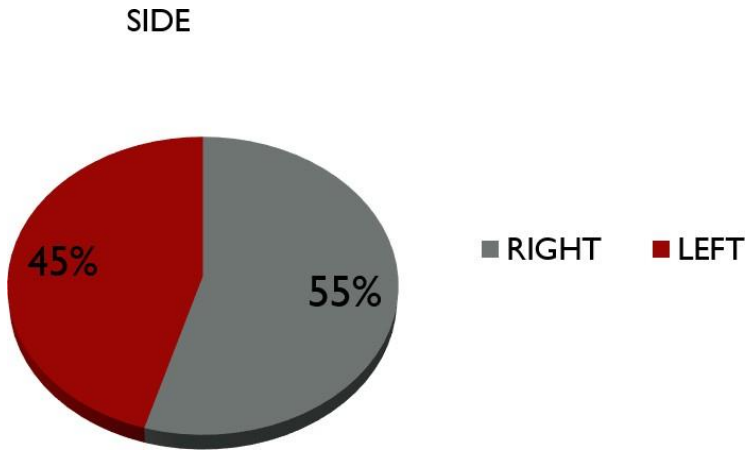

Fig17: Pie chart of side distribution (n=11)

In our study, 5 acetabular surgeries were performed on left side and6 on right side(Fig 17)

GENDER DISTRIBUTION

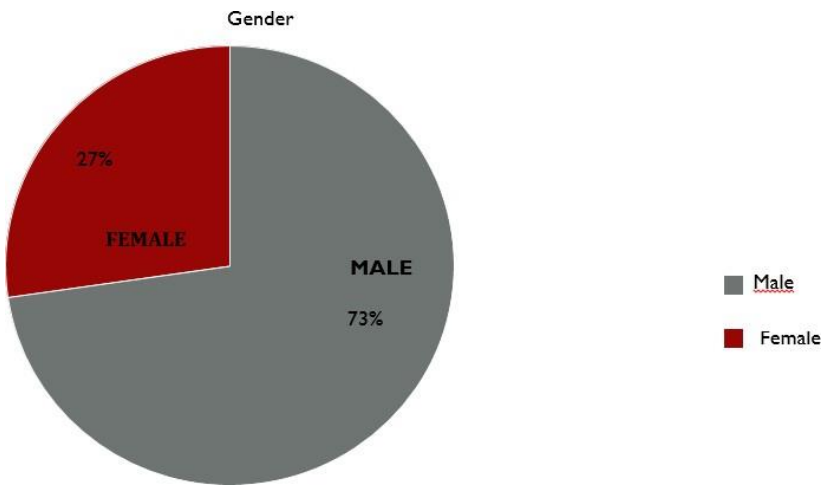

Fig18: Pie chart of gender distribution (N=11)

In our study of 11 cases, 8(73%) were males and 3(27%) were females.Themean age is 34.3 years.

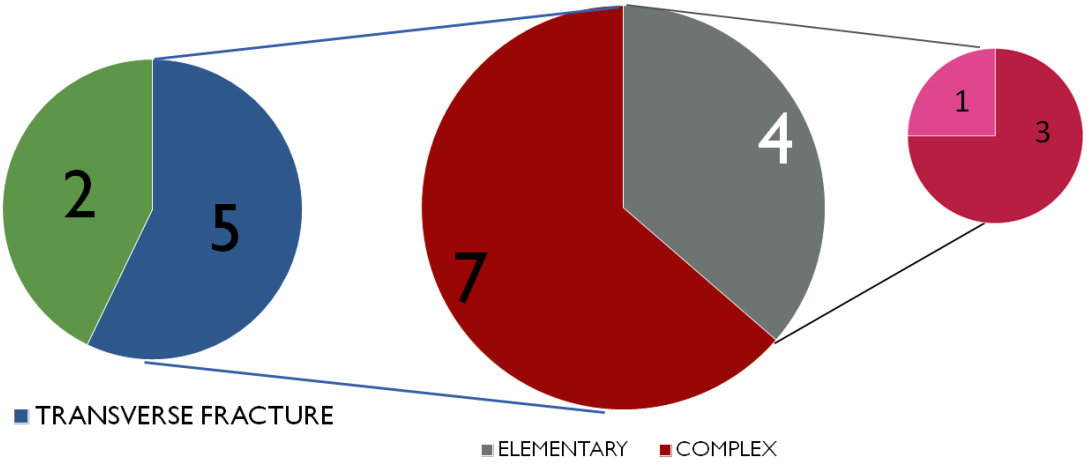

Fig19: Pie chart for distribution of fracture pattern (N=11)

Out of the 11 acetabular fractures, 7(63.6%) were complex pattern(out of which 5 had transverse fracture component) and 4(36.4%) were elementary pattern(out of which 1 was isolated posterior column and 3 were isolated posterior wall fractures)(Fig 19). 6 of them had associated dislocation out of which 3 also had preoperative foot drop.

		N	%
JUDET CLASSIFICATION	Posterior Column	1	9.1
	Posterior Wall	3	27.3
	Posterior Wall+ Column	2	18.2
	Posterior Wall+ Transverse	5	45.5
	Total	11	100.0

Table 5: showing fracture pattern distribution in our study

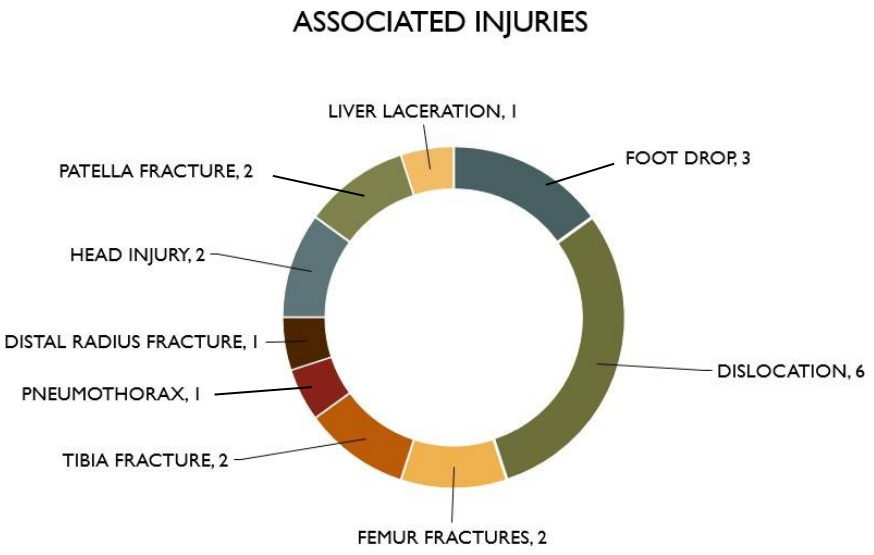

Fig 20: Associated injuries observed in our study

The associated injuries observed in our study other than acetabular fractures observed in 7/ 11(63.6%) of cases which included ipsilateral limb injuries in 4 cases (36.4%) like femur, patella and tibia fractures. Others included head injury, pneumothorax, liver laceration, bladder injury (Fig 20).

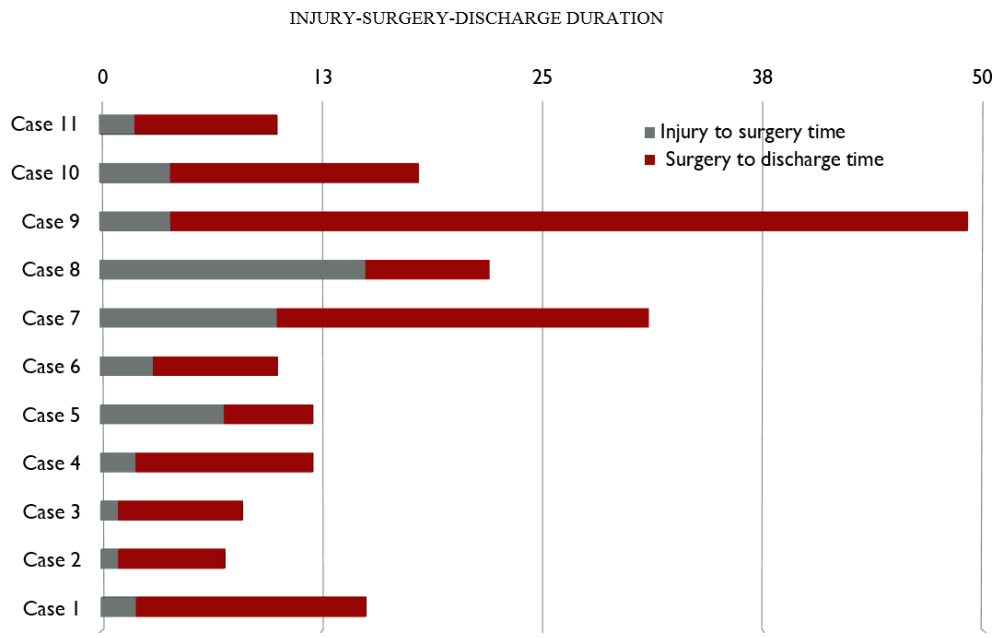

Fig 21: Barchart showing the interval between injury-surgery-discharge

In our study the average duration of hospital stay ranges from 7 days to 45 days with an average duration of 1 7.6 days. The injury to surgery duration varies from as short as 1 day to longest duration of 15 days but never beyond that. On an average patients were taken up for surgery 4.5 days after injury(Fig 21).

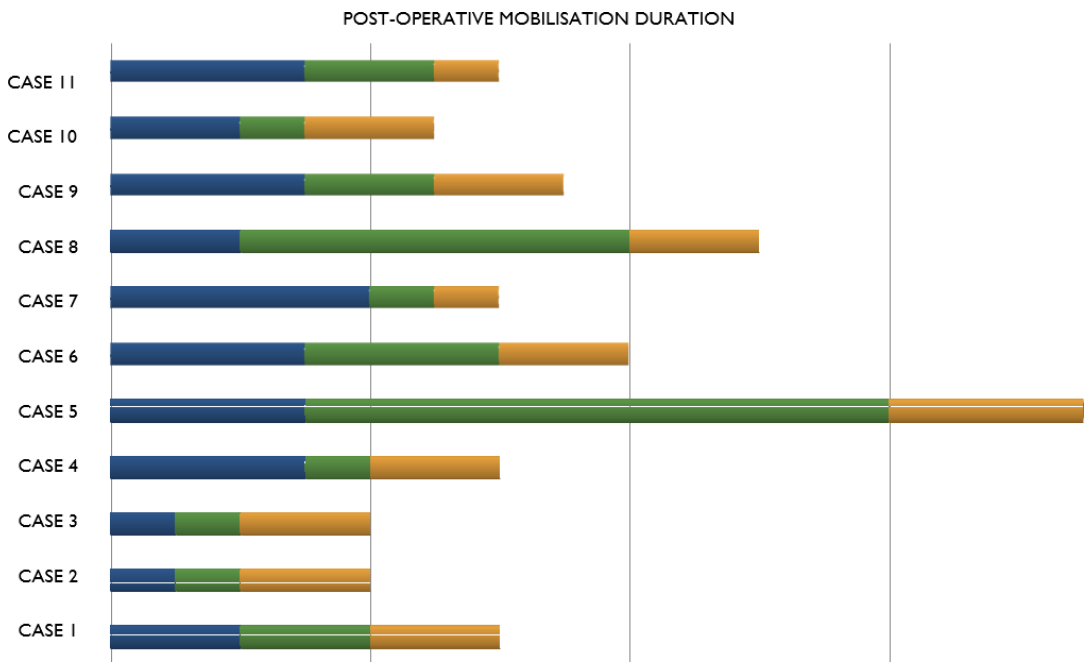

Fig 22: Bar Chart representing BED REST (blue)-NON WEIGHT BEARING (green)-PARTIAL WEIGHT BEARING(yellow) duration

On an average bed rest was given for period of 2.4 months, NWB for next 2.6 months and PWB for next 1.9 months following which FWB was started(Fig 22).

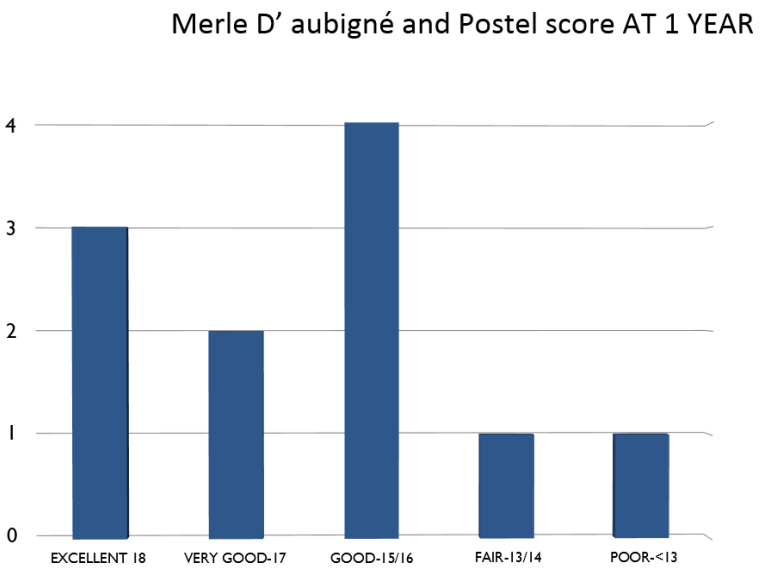

Fig 23: Bar Chart showing MDA score outcome at 1 year. We observed excellent results in 3(27.2%), very good in 2(18.1%), good in4(36.3%), fair in 1(9.1%) and poor in 1 case (9.1%).

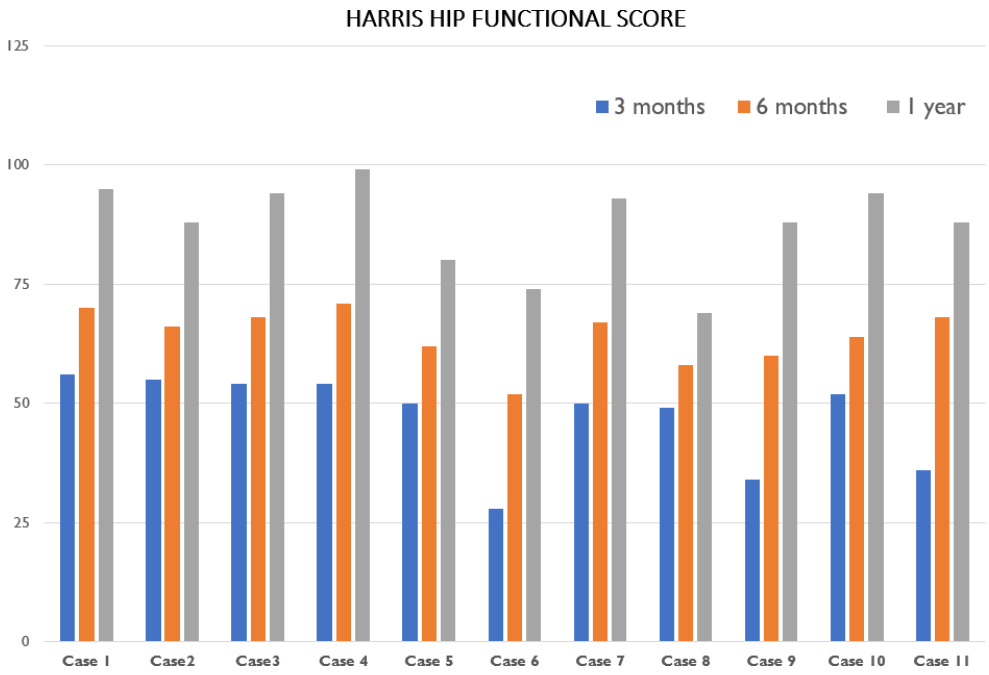

Fig 24. Bar Chart showing the HHS of all cases at 3mon/6mon/1 year follow up. At the end of 1year, 5 cases had HHS above 90, 4 cases hadHHS above 80, 1 case had HHS above 70 and 1 case had

HHS above 60.

	N	Minimum	Maximum	Mean	SD
AGE	11	19	52	34.36	10.70
Harris_3mn	11	28.00	56.00	47.09	9.70
Harris_6mn	11	52.00	71.00	64.18	5.74
Harris_1yr	11	69.00	99.00	87.45	9.40

Table 6: MEAN and SD of HHS at 3/6/12 months

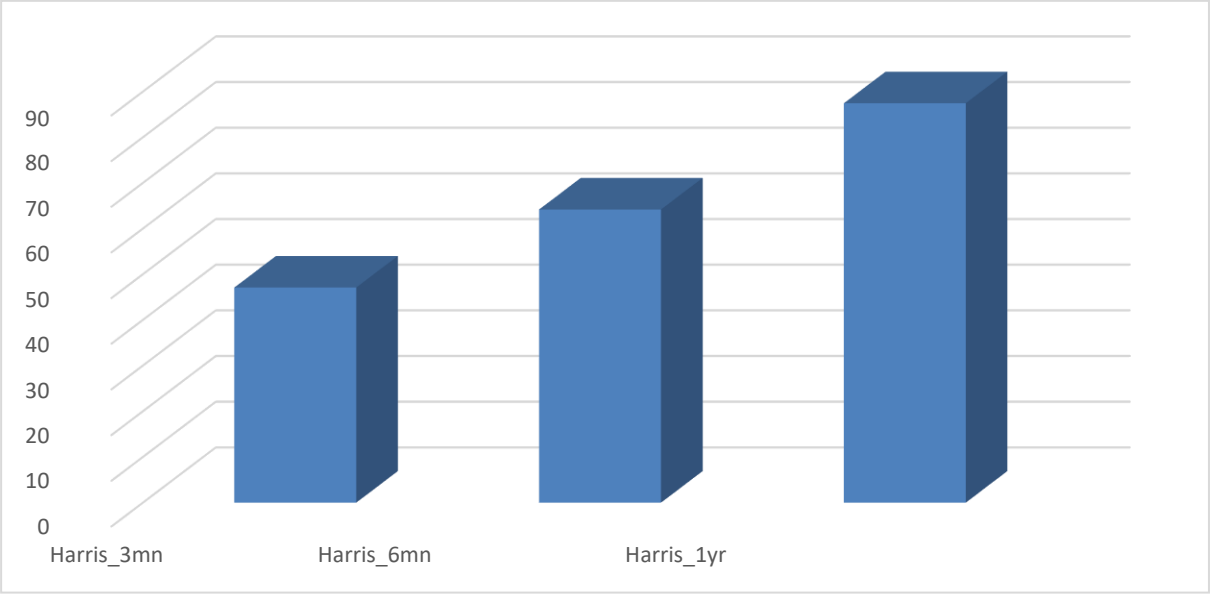

Fig 25: The bar chart showing the mean harris hip score at3mon/6mon/1year was 47.09/64.18/87.45 respectively

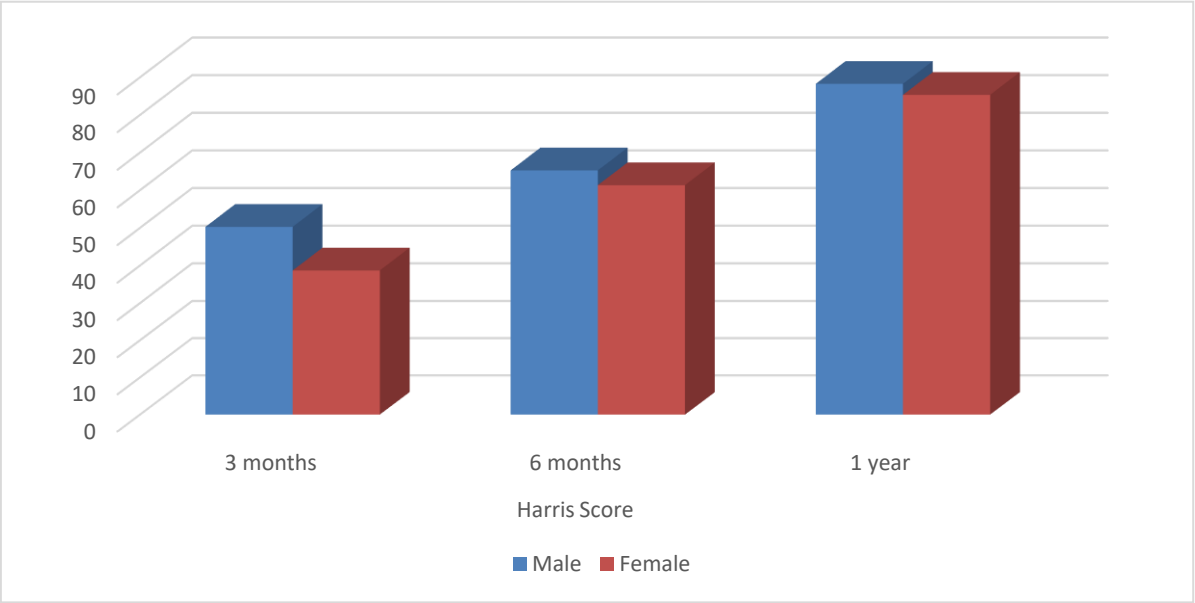

Fig26: Bar chart comparing HHS scores between males and females atend of 3mon/6mon/1year

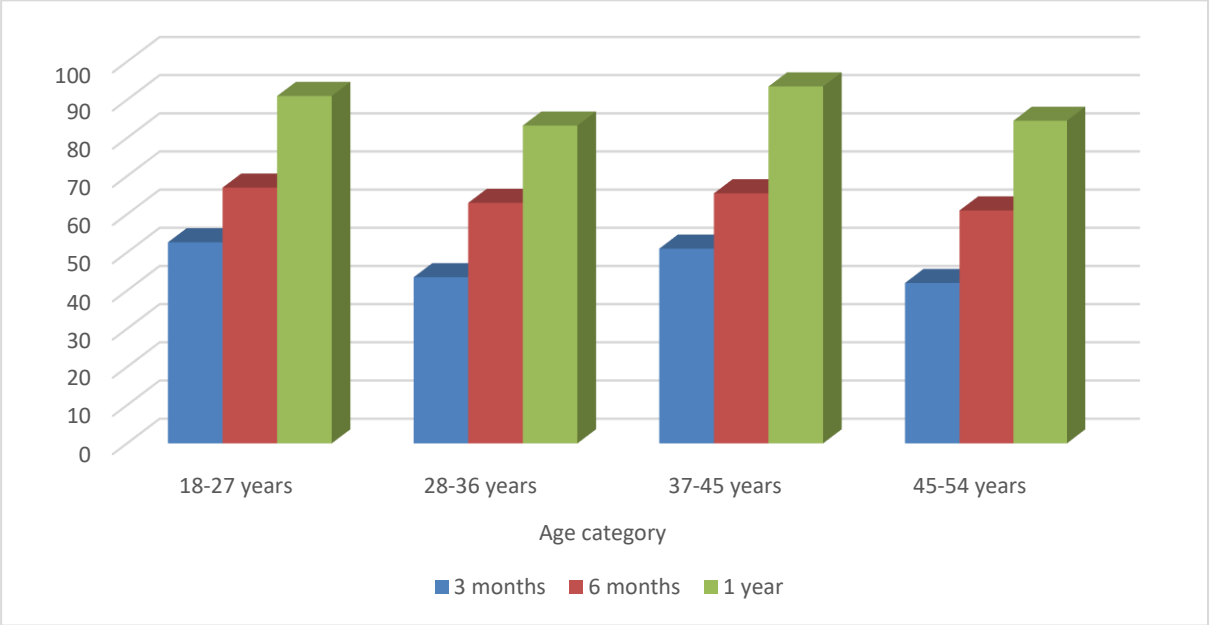

Fig 27: Barchart showing age wise distribution of HHS at end of 3 months/6months /1 year

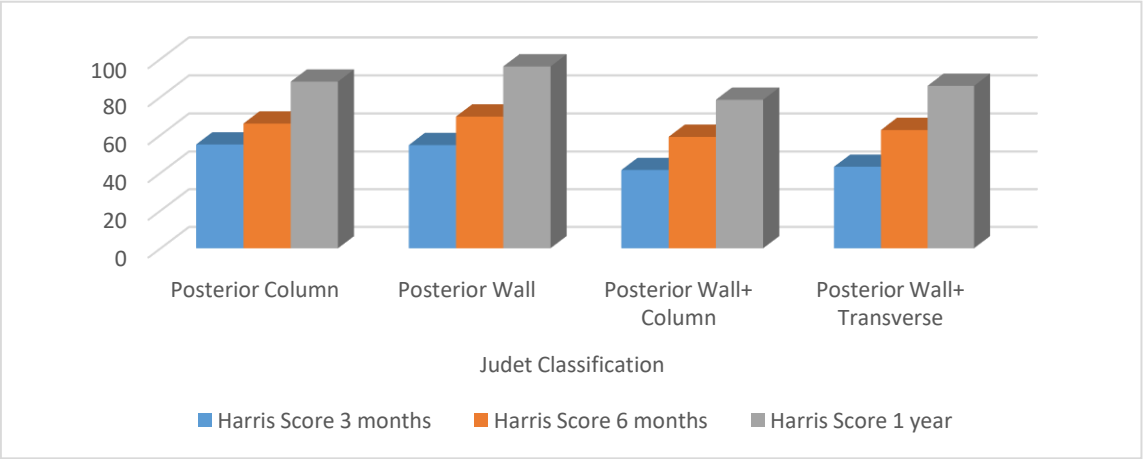

Fig 28: Clustered Bar Chart Comparing HHS vs fracture pattern

		Harris_3 mn		Harris_6 mn		Harris_1yr	
		Mean	**SD**	**Mean**	**SD**	**Mean**	**SD**
Age category	18-27 years	52.67	2.31	67.00	4.58	91.00	9.85
	28-36 years	43.50	10.15	63.00	4.76	83.25	9.50
	37-45 years	51.00	1.41	65.50	2.12	93.50	0.71
	45-54 years	42.00	19.80	61.00	12.73	84.50	14.85
	***P value**	**0.56**		**0.726**		**0.593**	
Gender	Male	50.25	7.07	65.25	4.74	88.25	9.68
	Female	38.67	12.22	61.33	8.33	85.33	10.26
	^P value	**0.249**		**0.209**		**0.819**	

		Harris_3 mn		Harris_6 mn		Harris_1yr	
		Mean	**SD**	**Mean**	**SD**	**Mean**	**SD**
Judet Classification	**Posterior Column**	55.00	-	66.00	-	88.00	-
	Posterior Wall	54.67	1.15	69.67	1.53	96.00	2.65
	Posterior Wall+ Column	41.50	10.61	59.00	1.41	78.50	13.44
	Posterior Wall+ Transverse	43.20	10.64	62.60	6.39	85.80	8.61

*One-way ANOVA test, ^Unpaired t test

Table 7: HHS vs age/gender/fracture pattern

The mean Harris hip score of patients in the age group of 18 - 27 years was 52.6/67/91, for 27-36 years was 43.5/63/83.3, for 36-45years
was 51/65/93.5 and for 45-54 years it was 42/61/84.5 at end of3mon/ 6mon/ 1year respectively.P value as calculated by ANOVA test was insignificant when compared with age. (p>0.05)

The mean Harris hip score in males was 50.25/ 62.5/ 88.25 and in females was 38.67/61.33/ 85.33 at the end of 3mon/6mon/1yearrespectively.P value as calculated by unpaired t test was insignificant at 3months, 6 months and 1 year(p>0.05)

		MDA SCORE					**Total**	**Value**	**P value**
		1	**2**	**3**	**4**	**5**			
Age category	18-27	0	1	0	0	2	3	**11.764**	**0.465**
	28-36	1	0	2	1	0	4		
	37-45	0	0	1	1	0	2		
	45-54	0	0	1	0	1	2		
Total		1	1	4	2	3	**11**		

Chi-square test, *Statistically significant at p ≤0.05

Table 8: Age VS MDA

MDA scores were calculated in different age groups and p value calculated using chi-square test which was statistically insignificant(p>0.05)(Table 8).

		MDA SCORE					Total	Value	P value
		1	2	3	4	5			
GENDER	**Male**	1	1	1	2	3	8	**7.219**	**0.125**
	Female	0	0	3	0	0	3		
Total		1	1	4	2	3	**11**		

Chi-square test, *Statistically significant at p ≤0.05

Table 9: Gender vs MDA

P- value was calculated using the chi square test. MDA score compared with general distribution was found statistically insignificant.(p>0.05)(Table 9).

		MDA SCORE							
		1	2	3	4	5	**Total**	**value**	**P value**
Judet Classification	**Posterior Column**	0	0	0	1	0	1	**20.625**	**0.05***
	Posterior Wall	0	0	0	0	3	3		
	PosteriorWall+ Column	1	0	1	0	0	2		
	PosteriorWall+ Transverse	0	1	3	1	0	**5**		

Chi-square test, *Statistically significant at p ≤0.05

Table 10: Fracture pattern vs MDA

MDA scores were calculated with respect to different fracture patterns and p value was statistically significant ($p<0.05$) using chi - square test, but this is of no relevance practically because of less number of casesin our study(Table 10).

	Fracture	Mean	Std. Deviation	t value	P value
HHS 3mon	Simple	54.7500	.95743	2.408	**0.039**
	Complex	42.7143	9.74191		
HHS 6mon	Simple	68.7500	2.21736	2.439	**0.037**
	Complex	61.5714	5.53345		
HHS 1yr	Simple	94.0000	4.54606	1.984	**0.04**
	Complex	83.7143	9.60407		

Unpaired t test, Statistical significance fixed at $p \leq 0.05$

Table 11: HHS vs Simple/ Complex acetabular fracture

	Injuries	N	Mean	Std. Deviation	t value	P value
HHS 3mon	Isolated acetubular injuries	7	45.0000	11.84624	0.940	**0.372**
	Associated limb injuries	4	50.7500	2.21736		
HHS 6mon	Isolated acetubular injuries	7	64.0000	6.21825	0.132	**0.898**
	Associated limb injuries	4	64.5000	5.68624		
HHS 1yr	Isolated acetubular Injuries	7	88.7143	7.22759	0.567	**0.584**
	Associated limb injuries	4	85.2500	13.42572		

Unpaired t test, Statistical significance fixed at $p \leq 0.05$

Table 12: HHS vs isolated acetabular fracture/ associated limb injury

	Hip dislocation	Mean	Std. Deviation	Std. Error Mean	t value	P value
HHS 3mon	Yes	42.8333	11.66905	4.76387	1.752	**0.114**
	No	52.2000	2.28035	1.01980		
HHS 6mon	Yes	63.1667	7.65289	3.12428	0.622	**0.549**
	No	65.4000	2.40832	1.07703		
HHS 1yr	Yes	85.5000	11.74308	4.79409	0.738	**0.480**
	No	89.8000	6.01664	2.69072		

Unpaired t test, Statistical significance fixed at $p \leq 0.05$

Table 13: HHS vs dislocated hips

		Fracture type		Injuries		Hip dislocation	
		Simple	Complex	Isolated acetubalar Inuries	Associated limb injuries	Yes	No
MDA SCORE	1	0	1	0	1	1	0
	2	0	1	0	1	0	1
	3	0	4	4	0	3	1
	4	1	1	1	1	0	2
	5	3	0	2	1	2	1
Chi-square		8.839		5.958		5.286	
P value		**0.065**		**0.202**		**0.259**	

Table 14: MDA vs fracture type/associated limb injury/hipdislocation

100% Radiological union

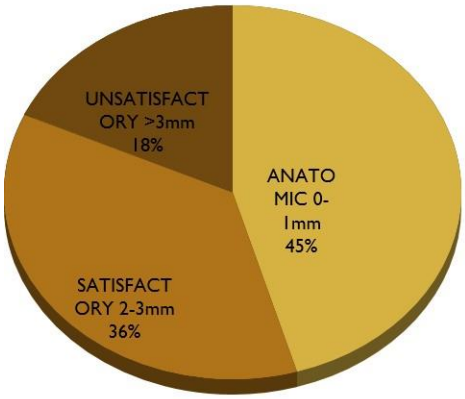



Fig 29: Pie chart showing postoperative fracture reduction according to MATTA'S CRITERIA OF FRACTURE REDUCTION

5cases (45%) showed anatomic reduction, 4 cases (36%) showed satisfactory reduction and 2cases(18%) showed unsatisfactory reduction. Radiological union was obtained in all cases (100%) at end of one year.

		Matta criteria fracture reduction					
		Anatomic	Unsatisfactory	satisfactory	Total	value	P value
Fracturetype	PosteriorColumn	1	0	0	1	10.340	0.111
	Posterior Wall	3	0	0	3		
	Posterior Wall+ Column	0	0	2	2		
	PosteriorWall+ Transverse	1	2	2	5		

Chi-square test, *Statistically significant at p ≤0.05

Table 15: Matta's criteria of fracture reduction vs fracture type

MDA		Matta criteria fracture reduction			Total		
		Anatomic	Unsatisfactory	satisfactory		value	P value
	Excellent	3	0	0	3	11.275	.187
	Fair	1	0	0	1		
	Good	0	2	2	4		
	Poor	0	0	1	1		
	Verygood	1	0	1	2		

Chi-square test, *Statistically significant at p ≤0.05

Table 16: Matta's criteria of fracture reduction vs MDA

Intraoperative	Early	Late
1. Neuro-vascular injury.	1. Infection.(2)	1. Hip Stiffness.(3)
2. Inadequate reduction.(2)	3. DVT.	2. Arthritis.(3)
4. Screw penetration.	2. Pulmonary Embolism.	3. Heterotopic Ossification
	4. Implant Failure.	5. Non Union.
	6. Foot Drop.	5. AVN.
		6. Limb length discrepancy.(2)
		7. Disuse osteopenia.(1)

Table 17: COMPLICATIONS OBSERVED

Various post operative complications occurred in our study in 6/ 11(54.5)% of cases which included surgical site infection in 2cases,arthritis in 3 cases,limb length discrepancy in 2 cases,1 patient developed disuse osteopenia over entire ipsilateral lower limb.None of the cases had iatrogenic foot drop,although 3 cases had foot drop preoperatively at the time of injury.None of them had implant failure/ non union/ heterotopic ossification/ AVN/ revision surgery/ pulmonary embolism.

DISCUSSION

Our study evaluated the short-term results of functional and radiological outcomes of patients who underwent surgical fixation of posterior wall and column acetabular fractures. We evaluated radiological union and functional scores to assess the outcome. In our study, di fferent surgeons with a similar surgical technique and single approach, operated on all our patients. The postoperative protocols followed were identical for all the patients including the rehabilitation. Outcomes of 11 out of 11 surgically fixed acetabular fractures reported(between 2018-2020) followedfor short term period about 6mon to 1 year

The aim of treatment of displaced acetabular fractures is to obtain a stable anatomical reduction with a functional, mobile and pain - free hip [55]. The accuracy of reduction correlates strongly with outcome [56].A thorough understanding of the fracture pattern as a function of the intricate relationship between the point of impact, the energy involved, the position of the hip and the strength of the bone is essential. Plastic deformation
often occurs before fracturing, making fracture lines difficult to judge and reduction occasionally a challenge. It is sometimes necessary t o accept extra- articular malalignment to achieve intra -articular anatomical reduction.

Complications are common in acetabular fracture surgery, with
20-25% of patients having poor functional outcome in medium term [57].The decision to treat a fracture surgically, the surgical approach and accuracy of the reduction are strongly influenced by the surgeons training and expertise [58.] Factors influencing the outcome include delay in surgical treatment [59,60,61]fracture pattern [62,63] patients age [56]associated chondral damage to the femoral head and acetabulum [16,17] dislocation at the time of injury[18] associated neurovascular compromise and preexisting co morbids [56].

Knowing and understanding the mechanism of injury is the key factor in identifying the potential injurie s and providing optimum care in trauma patients [65]. Pre-op evaluation including special views and CT helpsin pre-op planning the appropriate approach, minimizing the duration of surgery and reducing the intraoperative and postoperative complications. *Kocher- Langenbeck* approach is one of the preferred surgical approaches by many pelvi acetabular surgeons and used in majority of fractures not involving anterior wall, anterior column. It is used frequently in about 90% of cases in many studies [66,67] . In our study kocher langenbech approach was used in all cases (100%).

Regarding the delay between the injury and surgery **, Zhang et al** .[68] conducted study on 17 cases with delay of 6 hours to 9 days using Matta's radiological criteria , he concluded that it is important to minimize the delay in case of transverse with posterior wall fractures to achieve anatomical reduction and to reduce the incidence of arthritis. In our study mean time between the injury to surgery was 4.5days(ranges from as early as 1 day to longest of 15 days) but never delayed beyond three weeks which would result in poorest outcome. Complex associated fractures need to be fixed within the first five days, but more simple fractures can be adequately managed up to 15 days after the injury [61] **.** Beyond this time, results become less satisfactory. In **Letournel' s** original series, the outcome of all reconstructions which were undertaken beyond three weeks was significantly worse[69].

H.J.Kreder et al. [70] in their study involving 128 acetabular fractures, suggested that anatomical reduction alone was not sufficient to restore the joint function. In addition to articular reduction functionaloutcome was also determined by fracture pattern, marginal impaction, age
of the patient and associated comorbid conditions. They also suggested primary total hip replacement surgery in patients with age more than 50 years for fractures involving marginal impaction with posterior wall comminution. In our study none of the cases underwent primary total hip replacement. In order to observe number of cases which would require

secondary total hip replacement,mid term or long term follow up study isrequired.

Matta J et al [11] in 1996 done his study in 259 pts with 262 acetabular fractures operated within 21 days of injury.255 hips were followed up to 6 years and other 7 which had poor results followed till 2y ears. Our study being a short term study we followed all 11 patients between 6 mon to 1 year.258 hips operated by single kocher langenbeck/ilio inguinal approach and other 4 by both approaches. Our study is about posterior acetabular fractures and therefore all 11 patients were operated using single *Kocher Langenbeck* approach. Anatomic reduction was obtained in 185(71%) in their study whereas anatomic reduction was obtained in 5(46%) of our cases. Loss of anatomic reduction was attributed to the fact of complexity of fractures, associated limb injuries which resulted in delay in injury to surgery time. MDA outcomes were Excellent for 104(40%),good 95(36%) fair 21(8%)poor 42(16%) in their study whereas excellent for3(27%)very good for 2(18%)good for 4(36%) fair in 1(9%) and poor in1(9%) observed in our study. He concluded in his study that anatomic reduction and postoperative congruity between acetabulum and femoral head is the key factor for better outcomes. Accuracy of reduction and best clinical results can be achieved in patients operated within three weeks. In our study average duration from injury to surgery time was 4.5days.

Fracture pattern*	Letournei(ref 69) (%)	Matta (ref55) (%)	Dakin (ref71) (%)	Giannou dis(ref 57(%)	Our study(%)
TV + PW	20.6	23.5	35.3	17.4	45.5
PW	22.4	8.6	12.9	23.6	27.3
PW + PC	3.5	3.9	18.8	5.7	18.2
PC	2.3	3.1	1.2	3.5	9.1

Table 18: Fracture pattern observed in various stuides

The distribution of fracture pattern varies in various studies (Table 18), both column involvement being the most common, second being the posterior wall with transverse fractures. In our study posterior wall with transverse fractures in 4/ 11 cases(36.4%) are most common type observed when compared to 20.6% and 23.5% in leutornel and matta et al study respectively. Isolated posterior wall fractures in our study accounts to about 3/ 11 cases(27.2%) when compared to **Leutornel** study(22.4%) and **Matta** study(8.6%).Although few cases involving anterior column or wall fractures have been operated in our institute but were excluded from our study.

In our study 4 cases had simple fracture pattern (1 isolated posterior column and 3 isolated posterior wall fracture) all of which had anatomic reduction among which three (75%) had excellent and one(25%) had very good outcome. In study by **Briffa et al** out of 119cases(75%) who had anatomic reduction showed excellent outcome in 66(55%) and good outcome in 28(25%). Unsatisfactory reduction was observed in 2/11(18%)
of our cases both of which showed good outcome whereas in study doneby **Briffa et al** 23 cases(20%) had unsatisfactory reduction am ong which 4(17%)had excellent outcome and 5(22%)had good outcome.

In this series we analyzed the quality of reduction and outcome. We found that accurate assessment of gaps and steps was very difficult unless intra-operative, and so felt that it was justified to use congruency as part
of the assessment of reduction, judged on post -operative anteroposterior and oblique radiographs. We found a strong correlation between reduction and outcome. In the congruent group there was a much higher incidence of good outcomes (Table 16). It has been reported that incongruent reduction correlates strongly with a poor outcome [72], and most poor results werewithin this group. Recent studies showed that although anatomic reduction is essential for best outcomes but articular cartilage damage plays key rolein future outcomes[70].

Author/s	Cases	Mean follow-up (yrs)	Excellent/ good (%)
Bircher	161	11.3	*73*
Madhu et al [61]	237	2.9	*76*
Deo et al [64]	74	2.6	*74*
Fica et al [73]	84	5.5	*68*
Rommens et al [74]	175	2	*76*
Matta et al [55]	255	6	76
Mayo [75]	163	3.7	*75*
Ruesch et al [76]	53	1	*83*
Brueton [60]	26	2	*61*
Our study	11	1	*81.8*

Table 19: Comparison of published results from other studies

Table 19 showing mean age of follow up in acetabular fracture surgeriesin various studies with functional outcomes using MDA score. Our study results of excellent/ good outcome(81.8%) coincides with many of theabove mentioned studies by Madhu et al(76%),mayo et al(75%), Rommens et al(76%),ruesch et al(83%).

	MDA Outcome			
Fracture pattern	**Excellent (%)**	**Good (%)**	**Fair (%)**	**Poor (%)**
PW	*52.17*	*17.39*	*4.35*	*26.09*
PC	*14.29*	*14.29*	*28.57*	*42.86*
TV + PW	*28.57*	*21.43*	*28.57*	*21.43*
PC + PW	*45.45*	*27.27*	*0.00*	*27.27*

Table 20: Relative frequencies of fracture pattern vs outcome in 161patients in Briffa et al study

* PW, posterior wall; TV, transverse; PC, posterior column; TS, T - shaped; DC, double column; TV + PW, transverse posterior wall; AC, anterior column; PC + PW, posterior column posterior wall; AC + PHTV, anterior column posterior hemi transverse.

In study done by **Briffa et al.** 52.1% cases with isolated posterior wall fractures had excellent outcomes but on ly 28.57% of cases with posterior wall with transverse column fractures had excellent outcomes. In our study excellent outcomes are seen in 99% of cases with isolated posterior wall fractures but only 28% of cases with transverse and posterior wall fracture showed excellent results. The associated transverse fracture makes thereduction difficult and hence inappropriate congruency results in poor outcomes.

Those with a combined posterior wall traumatic dislocation and sciatic nerve palsy had a statistically significant negative impact on outcome. The small subgroup of patients with T - shaped fractures combined with a fracture of the posterior wall seem to represent the worst case scenario in many studies, i.e., a fracture that is difficult to reduce. The biology of the fracture (primary articular cartilage damage) has now become the limiting factor, and the role of primary arthroplasty may become more important in carefully selected cases as stated in study by **H.J.Kredal et al**[70].

In a study done by **Rommens et al.**[74] in a retrospective method in total of 77 cases who were surgically treated for acetabular fractures were followed up to an average of 45 months. Preoperatively 38(49.4%) cases had subchondral impaction,intra-articular fragments and comminution identified in CT scan.20 out of 23 cases with moderate MDA score cases and 20 out of 22 cases with moderate HHS score cases have modifiers as mentioned above. In our study one case which had intra articular incarcerated fragment with marginal impaction had poorest functional score among all. Hence preoperatively identified intraarticular fragments/comminution/subchondral impaction have lower midterm scores.

In a study done by **Pascarella et al.**[77] in 2017 in 121 patients who were operated for isolated posterior wall fractures and were followed up on an average of 53 months, the functional outcome scores were evaluated using MDA,HHS,SF-36 questionnaire and Matta radiological criteria. Anatomic reduction was obtained in 115(95%)cases satisfactory in remaining 6(5%)cases. MDA score observed as excellent in 45hips(40.2%) good in 52hips(46.4%)poor in only 8hips(7.1%) They concluded that prompt reduction of hip dislocation and accurate reduction are key factors in better outcome whereas associated injuries and nerve palsy have negative impact on outcomes. Similar to this in our study anatomic reduction was achieved in all three cases(99%) with isolated posterior wall fractures and showed excellent results in all of them, but when associated with ipsilateral limb injuries only few had excellent to good results.

The various complications observed in our study include sciatic nerve palsy(3/ 11) but none of them were iatrogenic, osteoarthritis in(3/ 11),limb length discrepancy in (2/ 11) surgical site infection in (2/11) and there was no heterotopic ossification or iatrogenic foot drop or non union or implant failure or conversion into THR in any of the case. In a study done by **Briffa et al.** sciatic nerve injury observed in 12.4% cases when compared to 27.2% in our study. Hip arthritis which is seen in 27.25% of cases in our study compared to 38% of cases as in study by **Briffa et al.** which may require treatment with hip replacement at later date. The occurrence of avascular necrosis was mentioned as in study by Briffa et al but none of them were observed our study due to short term period.

Rate of infection is around 5% of acetabular fractures treated operatively. Increased risk of infection in patients with open fractures and morel- Lavalle lesions. None of the cases in our study had open injury. Gastrointestinal and urologic injuries increase risk of infection. In our study, one case which had polytrauma and associated bladder injury developed surgical site infection **Haas et al.** reported infection in 6 out of 66cases(9%) who were treated with postoperative irradiation to prevent

heterotopic ossification.58%(7 out of 12cases)got infected who underwentembolization who has pelvic arterial injuries[78.]

Morbidly obese individuals have 5 times higher risk of infection[79,80] .One out of the two patients who developed surgical site infection in our study who is morbidly obese and also had extensive fracture communition which required more soft tissue dissection and prolonged surgery duration. Infection rates were about 2/11(18.18%) in our study. In our study both the cases which developed surgical site infection were superficial and were treated with antibiotics and regular dressings. In study done by **Briffa et al** reported total infection rate about 18% out of which deep infection were 9%. Prophylactic antibiotics were administered in all cases. Neg pressure wound therapy used over closed surgical wound, can treat infection. (Deep infection occurs with *Kocher Langenbeck* approach because of direct joint exposure and soft tissue stripping from innominate bone. Wound debridement and irrigation for deep seated wounds,culture specific antibiotic treatment for 6 weeks must be administered. Although it is important to limit our soft tissue exposure to minimize infection rates, a number of case s achieved a good outcome with adequate exposure and congruent reduction.

Iatrogenic injury to the sciatic nerve is major complication in acetabular fractures. More commonly occurs in posterior approaches where retraction of sciatic nerve is done. **Matta et al**. reported 3 - 5% rate of nerve injury in his study(ref 11). **Middle brook et al** . demonstrated no any reduction of rate of iatrogenic nerve injuries even with the use of intra - operative somatosensory- evoked potential monitoring. Various methodsadvised to prevent injury are careful patient positioning, maintaining knee flexion, cautious placement of retractor and limited traction on nerve while reduction.

The overall incidence of sciatic nerve palsy was 12% (20)in study by **Briffa et al** ; three were iatrogenic, two of which had a delayed presentation (one to two weeks after surgery) and were caused by a

hematoma in the greater sciatic notch, probably due to anticoagulation. An early post-operative palsy in a nerve that was functioning normally in the immediate post- operative period must be decompressed urgently. Intra -operative monitoring of the nerve was not done in our case as it has no significance in reducing the sciatic nerve injury [81,82] In our study, three cases had foot drop, all of them were present preoperatively. These three cases had associated hip dislocation and complex fracture pattern. All were treated conservatively and foot drop splint was given. They showed gradual recovery by end of one year.

Management of nerve injury includes ankle foot orthroses, observation, and physical therapy. Release of the sciatic nerve from thescar tissue and heterotopic bone shown to be helpful. Recovery time ranges from 6 months to 3 years in some cases. Sensory symptoms can recover but motor symptoms may not. In some refractory cases even chronic pain regional syndrome can occur.

The accuracy of fracture reduction is main determinant for the risk of late arthritis (less than 1mm fracture gap have better outcomes)[4,11].
Increased incidence of osteonecrosis occurs in patients with hip dislocation. **Matta et al.**[55] emphasized that the primary complication following a fracture of the acetabulum is post - traumatic osteoarthritis. The overall incidence of osteoarthritis in **Briffa et al.** series was 38%, in our study was 3/11(27.3%) which was similar to the the 26.6% reported by **Giannoudis et al.**[57] in his 2005 meta- analysis. The length of follow- up is critical, and with a longer follow-up arthritis is more likely to develop even in 'perfectly' reduced fractures. As our study is short term follow up, accurate results cannot be assessed In this aspect. None of our cases underwent primary or secondary THR [83,84] shows that results of secondary THA for posttraumatic arthritis after ORIF is inferior to that of primary THA for degenerative arthritis.

Leutornel and judet [4] reported 13 deaths after acetabular fracture surgery,4 of which were due to massive pulmonary embolism [85] in a study

done in 229 cases of acetabular fractures, thromboembolic prophylaxis regimen was given for all and postoperative DVT occurred in 4% cases, whereas nonfatal pulmonary embolism occurred in 1%. There were no cases of fatal pulmonary thromboembolism. There were no cases of postoperative pulmonary embolism or DVT with our current anticoagulation protocol, namely immediate post- operative prophylactic dose of low molecular weight heparin followed by three months of warfarinisation aiming at an INR of two to three. No formal pre - or post-operative DVT screening was undertaken.

Intra- articular placement of screws is serious complication in acetabular fracture surgery which can lead to posttraumatic arthritis. **Leutornel and judet** [54] proposed making full movement of hip through range of motion in complete silence and hear for crepitus [86,87] and they have described intraop and postop radiography to ensure the hardware is placed outside. In our study any screw placement was doubtful as checked using fluoroscopy about intraarticular placement, that was removed and reinserted. Post operative CT scan would help in clear picture of any intraarticular screw placement.

Heterotopic ossification can occur from 18 - 90% after acetabularfracture surgery. Greater than 20% loss of hip movement can be termed as severe HO[11] according to **Brooker** classification for HO [88,89]. Radiographic judet views also can be done to assess HO [90]. Symptomatic HO requires surgical excision followed by secondary prophylaxis for prevention of recurrence 91. **Wu et al.** reported 18 acetabular fractures with HO,7 had resection within 6 months,8 between 6 to 12 mon and 3 after 1 year. Recurrence was 29% when done before 6 mon and 36% when done after 6 months but none of the recurrences were clinically significant. Prophylactic postoperative irradiation therapy, indomethacin, or combination was advised for post excision prophylaxis. None of the patients in our study developed heterotopic ossification classified as Brooker III/ IV. The indomethacin, and its efficacy is still controversial. The nil occurrence here is almost certainly attributable to the fact that very few extensile approaches were used, and a thorough debridement was undertaken before closure of the wound.

SUMMARY

- Of the total of 11 patients, 11 were followed for a mean of 1year; none were lost to follow-up postoperatively.
- The 11 patients had a mean age of 34.3, there were 8 males (72.7%) and 3 females (27.3%). The mechanism of injury was a road traffic accident in all our cases. We observed simple fractures in 4(36.4%) cases and complex fractures in 7 cases (63.6%).
- The frequency of fracture patterns is shown in Table 5; 7 patients(63.6%) sustained polytrauma and almost half had associated limb fractures.
- Dislocation of the hip was recorded in 6 patients (54.6%).All hips were presented with dislocation except for one which had been closed reduced outside hospital. The mean time to surgery was 4.5days as illustrated in (Fig 21). The quality of reduction in the immediate postoperative x-rays was shown in (Fig 29). The outcome was better in the anatomical and congruent groups; there were more excellent results recorded in the anatomical group. Out of 5 anatomic reductions achieved, 4 had elementary fracture type. 2 unsatisfactory reductions were observed ,both of which had associated transverse component(both of them developed arthritis changes within an year).
- The complications in our study are shown in (Table 16).
- THR was required in none of our patients.
- 3 foot drops(27.3%) observed in my study were preoperatively associated and no iatrogenic foot drop occurred .All three cases associated with hip dislocations. Foot drop was treated conservatively and completely recovered in one case and partially recovered in two cases at end of 1 year.
- Limb length discrepancy associated with slight limp was observedin two cases(18.2%) in my study.
- Surgical site infection occurred in two cases(18.2%) (one had poly trauma and was morbidly obese and other had bladder injury).

- Disuse osteopenia seen in one case(9.1%)(associated with head injury because of which she was prolonged immobilized)
- No any implant failure or non-union observed in my study.
- The results according to the modified MERLE D' AUBIGNÉ AND POSTEL SCORING SYSTEM was excellent in 3 patients (27.3%), very good in 2 patients(18.2%)good in 4 patients(36.4%), fair in 1(9.1%) and poor in 1 (9.1%).
- Mean HARRIS HIP SCORE at end of 3mon/6mon/ 12mon was 47.08/64.18/87.45.

In conclusion, a good to excellent functional and radiological outcome was seen in 9/11 patients treated surgically. Complications are common in the short, medium and long term as observed in many studies. There was a disappointingly high infection rate, but a low rate of heterotopic ossification and minimal significant incidence of DVT or pulmonary embolism. No patient developed a DVT when an appropriate prophylaxis regime was used. At present, the aim of the management of displaced acetabular fractures is to achieve anatomical reduction and stable fixation, thereby maintaining the congruence of the joint.

CONCLUSION

- Gold standard treatment is open reduction and internal fixation in dedicated centers by experienced surgeons as soon as possible.
- Early intervention in case of hip dislocation is important to prevent the chondral damage.
- Early ORIF is necessary to provide accurate anatomic reduction and joint congruency which can prevent or delay future requirement of THA.
- Posterior wall and dome of acetabulum parts are most important to reconstruct as they are the weight bearing structures.
- Associated injuries must be addressed well to improve the overall functional scores.
- Poor functional results are due to increased age/ delay in surgery/complex fracture/ associated transverse component fracture/inappropriate reduction/ dome incongruency/ polytrauma.

LIMITATIONS IN THE STUDY

- Our study is not a comparative study.
- Long term study is required to assess the occurrence of hip arthritisand avascular necrosis(incidence of future conversion to THA)
- Postoperative CT scan will help in assessing the accurate anatomicreduction and joint congruency.
- If sample size is more, outcome results can be more reliable.
- Isolated elementary fractures and complex fractures are studiedtogether which may bring fallacies in the results.

BIBLIOGRAPHY

1. Laird A, Keating JF. Acetabular fractures: A 16 -year prospective epidemiological study. *J Bone Joint Surg Br*. 2005;87:969–973.
2. Mauffrey C, Hao J, Cuellar DO III, et al. The epidemiology and injury patterns of acetabular fractures: Are the USA and China comparable? *Clin Orthop Relat Res*. 2014;472: 3332–3337.
3. Ferguson TA, Patel R, Bhandari M, et al. Fractures of the acetabulum in patients aged 60 years and older: An epidemiological and radiological study. *J Bone Joint Surg Br*. 2010; 92:250–257.
4. Letournel E, Judet R. Fractures of the Acetabulum. 2nd ed. New York: Springer-Verlag;1993.
5. Vrahas M, Gordon RG, Mears DC, et al. Intraoperative somatosensory evoked potential monitoring of pelvic and acetabular fractures. *J Orthop Trauma*. 1992;6:50–58.
6. Al- Qahtani S, O'Connor G. Acetabular fractures before and after the introduction of seatbelt legislation. *Can J Surg* . 1996;39:317 – 320.
7. Gary JL, Lefaivre KA, Gerold F, et al. Survivorship of the native hip joint after percutaneous repair of acetabular fractures in the elderly. *Injury*. 2011;42:1144–1151.
8. Tannast M, Najibi S, Matta JM. Two to twenty - year survivorship of the hip in 810 patients with operatively treat ed acetabular fractures. *J Bone Joint Surg Am*. 2012;94:1559–1567.
9. de Ridder VA, de Lange S, Popta JV. Anatomical variations of the lateral femoral cutaneous nerve and the consequences for surgery.*J Orthop Trauma*. 1999;13:207–211.
10. Kaempffe FA, Bone LB, Border JR. Open reduction internal fixation of acetabular fractures: Heterotopic ossification and other complications of treatment. *J Orthop Trauma*. 1991;5:439–445.
11. Matta J. Fractures of the acetabulum: Accuracy of reduction and clinical results in patients managed operatively within three weeks after the injury. *J Bone Joint Surg Am*. 1996; 78A:1632–1645.

12. Giannoudis PV, Grotz MR, Papakostidis C, Dinopoulos H. Operative treatment of displaced fractures of the acetabulum. Bone & Joint Journal. 2005 Jan 1;87(1):2-9.

13. Letournel E. Acetabulum fractures: classification and management. Orthopedic Trauma Directions. 2007 Sep;5(05): 27 - 33.

14. Helfet DL, Beck M, Gautier E, et al. Surgical techniques for acetabular fractures. In: Tile M, Helfet DL, Kellam JF, eds. Fractures of the Pelvis and Acetabulum. 3rd ed. Philadelphia, PA: Lippincott Williams & Wilkins; 2003:533–603.

15. Fassler PR, Swiontkowski MF, Kilroy AW, et al. Injury of the sciatic nerve associated with acetabular fracture. J Bone Joint Surg Am 1993;75A:1157-1166.

16. Matta JM. Fracture of the acetabulum: accuracy of reduction and clinical results in patients managed operatively within three weeks after the injury. Orthopedic Trauma Directions. 2011 Mar;9(02):31-6.

17. Moed BR, Carr SEW, Gruson K, et al. Compu ted tomography assessment of fractures of the posterior wall of the acetabulum after operative treatment. J Bone Joint Surg Am 2003; 85A:512 - 522.

18. Taeger G, Ruchholtz S, Waydhas C, Lewan U, Schmidt B, Nast - Kolb D. Damage control orthopedics in patients with multiple injuries is effective, time saving, and safe. Journal of Trauma and Acute Care Surgery. 2005 Aug 1;59(2):408-15.

19. Judet R, Judet J, Letournel E. Fractures of the acetabulum: Classification and surgical approaches for open reduction. *J Bone Joint Surg Am*. 1964;46A:1615–1638.

20. Bray TJ, Esser M, Fulkerson L. Osteotomy of the trochanter in open reduction and internal fixation of acetabular fractures. *J Bone Joint Surg Am*. 1987;69A:711–717.

21. Kregor PJ, Templeman D. Associated injuries complicating the management of acetabular fractures: Review and case studies. *Orthop Clin North Am*. 2002;33:73–95.

22. Moed BR, Carr SEW, Watson JT. Results of operative treatment of fractures of the posterior wall of the acetabulum. *J Bone Joint Surg Am*. 2002;84A:752–758.

23. Osgood GM, Manson TT, O'Toole RV, et al. Combined pelvic ring disruption and acetabular fracture: Associated injury patterns in 40 patients. *J Orthop Trauma*. 2013;27:243–247.

24. American College of Surgeons Committee on Trauma. Advanced Trauma Life Support Student Course Manual. 9th ed. Chicago, IL: American College of Surgeons; 2012.

25. Hess AE, Johal HS, O'Toole RV, et al. Early postoperative displacement of combined pelvic ring injury with acetabular fracture. *Orthopedics*. 2017;40:163–168.

26. Judet R, Judet J, Letournel E. Fractures of the acetabulum: classification and surgical approaches for open reduction: preliminary report. *J Bone Joint Surg [Am]* 1964;46-A: 1615-46.

27. Beaulé PE, Dorey FJ, Matta JM. Letournel classification for acetabular fractures: assessment of interobserver and intraobserver reliability. *J Bone Joint Surg [Am]* 2003;85-A: 1704-9.

28. Patel V, Day A, Dinah F, Kelly M, Bircher M. The value of specific radiological fea- tures in the classification of acetabular fractures. *J Bone Joint Surg [Br]* 2007;89- B:72-6.

29. Brandser E, Marsh JL. Acetabular fractures: easier classification with a systematic approach. *AJR Am J Roentgenol* 1998; 171: 1217 -28.

30. Ohashi K, El- Khoury GY, Abu- Zahra KW, Berbaum KS. Interobserver agreement for Letournel acetabular fracture classification with multidetector CT: are standard Judet radiographs necessary? *Radiology* 2006;241:386-91.

31. Durkee NJ, Jacobson J, Jamadar D, et al. Classification of common acetabular fractures: radiographic and CT appearances. *AJR Am J Roentgenol* 2006;187:915-25.

32. Harris JH Jr, Coupe KJ, Lee JS, Trotscher T. Acetabular fractures revisited: part 2: a new CT- based classification. *AJR Am J Roentgenol* 2004;182:1367-75.

33. Jantzen JP. More on acetabular fractures: The Trojan War and the Roman Empire. *Eur J Trauma Emerg Surg*. 2013;39:421–422.

34. Knight RA, Smith H. Central fractures of the acetabulum. *J Bone Joint Surg Am*. 1958;40A:1–120.

35. Rowe CR, Lowell JD. Prognosis of fractures of the acetabulum. *J Bone Joint Surg Am* . 1961;43A:30–59.

36. Stewart MJ. Discussion of prognosis of fractures of the acetabulum. *J Bone Joint Surg Am*. 1961;43A:59.

37. Cooper SA, Travers B. Surgical essays 1818. Part I.;51.

38. MacGuire CJ. Fracture of the acetabulum. Ann. Surg. 1926;83:718-9.

39. Phemister DB. Fractures of the neck of femur, dislocations of hip, and obscure vascular disturbances producing aseptic necrosis of head of femur. Surg Gynecol Obstet.. 1934;59:415- 40.

40. Campbell WC. POSTERIOR DISLOCATION OF THE HIP WITH FRACTURE OF THE ACETABULUM. JBJS. 1936 Oct 1;18(4):842-50.

41. Levine MA. A treatment of central fractures of the acetabulum. JBJS Case Connector. 1943 Oct 1(4):902-6.

42. Thompson VP, Epstein HC. TRAUMATIC DISLOCATION OF THE HIP: A Survey of Two Hundred and Four Cases Covering a Period of Twenty-one Years. JBJS. 1951 Jul 1; 33(3):746- 92.

43. Rowe CR, Lowell JD. Prognosis of Fractures of the Acetabulum. JBJS. 1961 Jan 1; 43(1):30- 92.

44. Judet R, Judet J, Letournel E. Fractures of the Acetabulum: Classification and Surgical Approaches for Open Reducti on: PRELIMINARY REPORT. JBJS. 1964 Dec 1;46(8):1615-75.

45. Matta JM, Merritt PO. Displaced acetabular fractures. Clinical orthopaedics and related research. 1988 May 1;230:83-97.

46. Olson SA, Matta JM. The computerized tomography subchondral arc: a new method of assessing acetabular articular continuity

after fracture (a preliminary report). J Orthop Trauma. 1993 Oct1;7(5):402-13.

47. Tornetta PI. Non- operative management of acetabular fractures. J Bone Joint Surg Br. 1999 Jan 1;81(1):67-70.

48. Andersen RC MD, O'Toole RV, Nascone JW, et al. Modified Stoppa approach for acetabular fractures with anterior and posterior column displacement: Quantification of radiographic reduction and analysis of interobserver variability. *J Orthop Trauma*. 2010; 24:271–278.

49. Anglen JO, Burd TA, Hendricks KJ, et al. The "gull sign": Aharbinger of failure for internal fixation of geriatric acetabular fractures. *J Orthop Trauma*. 2003;17:625–634.

50. Kazemi N, Archdeacon MT. Immediate full weight bearing after percutaneous fixation of anterior column acetabulum fractures. *J Orthop Trauma*. 2012;26:73–79.

51. Moed BR, Carr SEW, Gruson K, et al. Computed tomography assessment of fractures of the posterior wall of the acetabulum after operative treatment. *J Bone Joint Surg Am*. 2003; 85A:512 – 522.

52. Gregorios I Mitsionis. Surgical management of posterior hip dislocations associated with posterior wall acetabular fracture: a study with a minimum follow- up of 15 years. J Orthop Trauma 2012 Aug;26(8):460-5. doi: 10.1097/BOT.0b013e31822c4d6c.

53. Reza Firoozabadi. Risk Factors for Conversion to Total Hip Arthroplasty After Acetabular Fractures Involving the Posterior Wall. J Orthop Trauma 2018 Dec;32(12):607-611. doi: 10.1097/BOT.0000000000001327.

54. Merle d'Aubigné R, Postel M. Functional results of hip arthroplasty with acrylic prosthesis: 1954. *J Bone Joint Surg [Am]* 1954;36-A:451-75.

55. Matta JM, Mehne DK, Raffi R. Fractures of the acetabulum: early results of a prospective study. *Clin Orthop* 1996;205:241-50.

56. Mears DC, Velyvis JH, Chang CP. Displaced acetabular fractures managed operatively: indicators of outcome. *Clin Orthop* 2003;407:173-86.

57. Giannoudis PV, Grotz MR, Papakostidis C, Dinopoulos H. Operative treatment of displaced fractures of the acetabulum: a meta-analysis. *J Bone Joint Surg [Br]* 2005;87-B:2-9.

58. Giannoudis PV, Bircher M, Pohlemann T. Advances in pelvic and acetabular surgery. *Injury* 2007;38:395-6.

59. Bircher M, Lewis A, Halder S. Delays in definitive reconstruction of complex pelvic and acetabular fractures. *J Bone Joint Surg [Br]* 2006;88-B:1137-40.

60. Brueton RN. A review of 40 acetabular fractures: the import ance of early surgery. *Injury* 1993;24:171-4.

61. Madhu R, Kotnis R, Al-Mousawi A, et al. Outcome of surgery for reconstruction of fractures of the acetabulum: the time dependent effect of delay. *J Bone Joint Surg [Br]* 2006; 88-B:1197-203.

62. Moed BR, Yu PH, Gruson KI. Functional outcomes of acetabular fractures. *J Bone Joint Surg [Am]* 2003;85-A:1879-83.

63. Murphy D, Kaliszer M, Rice J, McElwain JP. Outcome after acetabular fracture: prognostic factors and their inter - relationships. *Injury* 2003;34:512-17.

64. Deo SD, Tavares SP, Pandey RK, et al. Operative management of acetabular fractures in Oxford. *Injury* 2001;32:581-6.

65. Beuran M, Negoi I, Păun S, Runcanu A, Gaspar B. Mechanism of injury--trauma kinetics. What happend? How?. Chirurgia/ Uniunea Societătilor de Stiinte Medicale din România. 2012;107(1):7-14.

66. Fica G, Cordova M, Guzman L, Schweitzer D. Open reductionand internal fixation of acetabular fractures. Int Orthop.1998;22(6):348-51.

67. Murphy D, Kaliszer M, Rice J, McElwain JP. Outcome afteracetabular fracture. Prognostic factors and their inter -relation-ships. Injury. 2003;34(7):512-7.

68. Zhang L, Xu M, He C, Du H, Chen H, Guo Y, et al. Effectivenessof acetabular transverse and posterior wall fractures by Kocher-

Langenbeck approach. Zhongguo Xiu Fu Chong Jian Wai Ke Za Zhi. 2010;24(12):1428-31.
69. Letournel E, Judet R. Operative treatment between three weeks and four months after injury. In: *Fractures of the acetabulum* . Second ed. Berlin: Springer-Verlag, 1998: 591 -633.
70. Kreder HJ, Rozen N, Borkhoff CM, Laflamme YG, McKee MD, Schemitsch EH, Stephen DJ. Determinants of functional outcome after simple and complex acetabular fractures involving the posterior wall. Bone & Joint Journal. 2006 Jun 1;88(6):776-82.
71. Dakin GJ, Eberhardt AW, Alonso JE, Stannard JP, Mann KA. Acetabular frac- ture patterns: associations with motor vehiclecrash information. *J Trauma* 1999;47:1063-71.
72. Murray MM, Zurakowski D, Vrahas MS. The death of articular chondrocytes after intra-articular fracture in humans. *J Trauma* 2004;56:128-31.
73. Fica G, Cordova M, Guzman L, Schweitzer D. Open reduction and internal fixation of acetabular fractures. *Int Orthop* 1998;22: 348 - 51.
74. Rommens PM, Broos PL, Vanderschot P. Preparation and technique for surgical treatment of 225 acetabulum fractures: 2 year results of 175 cases. *Unfallchirurg* 1997;100:338 -48 (in German).
75. Mayo KA. Open reduction and internal fixation of fractures of the acetabulum: results in 163 fractures. *Clin Orthop* 1994;305:31-7.
76. Ruesch PD, Holdener H, Ciaramitaro M, Mast JW. A prospective study of surgically treated acetabular fractures. *Clin Orthop* 1994;305:38-46.
77. Raffaele Pascarella. Surgical results and factors influencing outcome in patients with posterior wall acetabular fracture https://doi.org/10.1016/j.injury.2017.05.039
78. Manson TT, Perdue PW, Pollak AN, et al. Embolization of pelvic arterial injury is a risk factor for deep infection after acetabular fracture surgery. *J Orthop Trauma*. 2013;27:11 –15.

79. Karunakar MA, Shah SN, Jerabek S. Body mass index as a predictor of complications after operative treatment of acetabular fractures. *J Bone Joint Surg Am*. 2005;87:1498–1502.

80. Porter SE, Russell GV, Dews RC, et al. Complications of acetabular fracture surgery in morbidly obese patients. *J Orthop Trauma*. 2008;22:589–594.

81. Helfet DL, Anand N, Malkani AL, et al. Intraoperative monitoring of motor pathways during operative fixation of acute acetabular fractures. *J Orthop Trauma* 1997;11:2-6.

82. Haidukewych GJ, Scaduto J, Herscovici D Jr, Sanders RW, Di Pasquale T. Iatrogenic nerve injury in acetabular fracture surgery: a comparison of monitored and unmonitored procedures.*J Orthop Trauma* 2002;16:297-301.

83. Morison Z, Moojen DJF, Nauth A, et al. Total hip arthroplasty after acetabular fracture is associated with lower survivorship and more complications. *Clin Orthop Relat Res* . 2016;474:392–398.

84. Ranawat A, Zelken J, Helfet D, et al. Total hip arthroplasty for posttraumatic arthritis after acetabular fracture. *J Arthroplasty* . 2009;24:759–767.

85. Moed BR, McMichael JC. Outcomes of posterior wall fractures of the acetabulum. *J Bone Joint Surg Am*. 2007;89A:1170–1176.

86. Ebraheim NA, Savolaine ER, Hoeflinger MJ, et al. Radiologicdiagnosis of screw penetration of the hip joint in acetabular fracture reconstruction. *J Orthop Trauma*. 1989; 3:196–201.

87. Norris BL, Hahn DH, Bosse MJ, et al. Intraoperative fluoroscopyto evaluate fracture reduction and hardware placement during acetabular surgery. *J Orthop Trauma*. 1999;13:414–417.

88. Mears DC, Rubash H. Pelvic and Acetabular Fractures. Thorofare, NJ: Slack; 1986.

89. Moed BR, Maxey JW. The effect of indomethacin on heterotopic ossification following acetabular fracture surgery. *J Orthop Trauma*. 1993;7:33–38.

90. Moed BR, Smith ST. Three- view radiographic assessment of heterotopic ossification after acetabular fracture surg ery. *J OrthopTrauma*. 1996;10:93–98.
91. Nauth A, Giles E, Potter BK, et al. Heterotopic ossification in orthopaedic trauma. *J Orthop Trauma*. 2012;26:684–688.