

Caesarean Scar Pregnancy: Laparoscopic management along with Uterine Artery ligation at origin.

¹Dr Richa Pal, ²Dr Niteen Ghorpade, ³Dr Shanmugapriya Mahendran

¹ Fellow Endoscopy, ²Consultant, ³Fellow Endoscopy

¹Department of Obstetrics and Gynaecology, Inspiria Laparoscopy and IVF Research Centre, Rahata, Maharashtra, India.

Abstract:

Caesarean scar ectopic pregnancy is a rare type of ectopic pregnancy. With increasing caesarean delivery rates, an increased caesarean scar pregnancy incidence may be expected. It may be managed medically or surgically. Surgical management has been done successfully in the past but the importance of minimally invasive approach of retroperitoneal bilateral uterine artery ligation along with freshening of previous caesarean scar margins needs to be emphasized specifically in patients desirous of future fertility. In this case series, we describe two patients with caesarean scar ectopic pregnancy managed laparoscopic ally, along with retroperitoneal approach of bilateral uterine artery ligation at origin.

Keywords: Scar ectopic pregnancy, laparoscopic management, Trans vaginal USG, Retroperitoneal approach, minimally invasive,uterinearteryligation.

INTRODUCTION:

The incidence of Caesarean scar pregnancy is 1:1800- 1:2216 in a women with ectopic pregnancy.¹ Hence it is a rarest form of ectopic pregnancies. In caesarean scar pregnancy, the gestational sac gets implanted into the myometrium of previous caesarean scar area. Improvement in diagnostic techniques and advancement in transvaginal ultrasound and advent of minimal access surgery has contributed to early diagnosis and timely management of CSP.² In this case series, we describe two patients who came to us with different clinical presentations and were diagnosed to have caesarean scar ectopic pregnancy and managed laparoscopic ally, along with retroperitoneal approach of bilateral uterine artery ligation at origin.

CASE SERIES:

Case 1- A 30 year old G2P1L1 presented to the OPD with complaints of one and half months of amenorrhea with vague lower abdominal pain and backache. She underwent an uneventful term LSCS one year back for breech presentation. On examination, tenderness felt in suprapubic area. On bimanual examination, Uterus was soft, bulky, retroverted. Urine pregnancy test found to be positive. Trans vaginal USG revealed a single live gestational sac in the lower uterine segment at the level of previous LSCS scar suggestive of scar ectopic pregnancy (Fig 1). Tab Mifegest 200 mg was given. Serum beta HCG was 49,591mIU/ml.

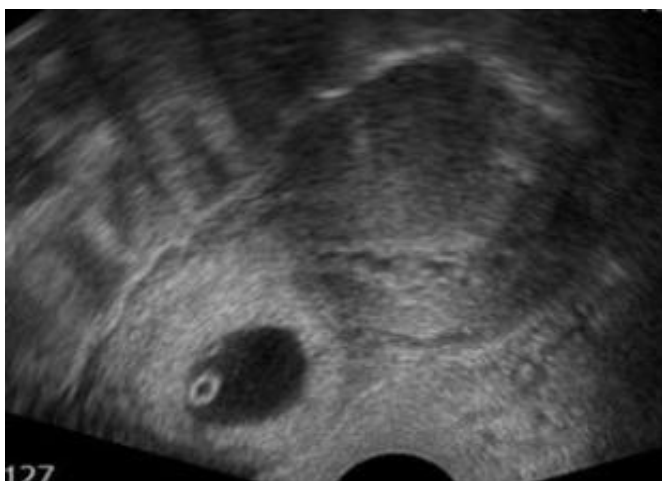


Fig 1: Transvaginal scan showing caesarean scar ectopic pregnancy.

Case 2-A 28 year old G2P1L1 with two months of amenorrhea with history of previous one caesarean presented with abdominal pain and spotting per vagina. Her urine pregnancy test was positive. Trans vaginal USG revealed a single gestational sac in the lower uterine segment at the level of previous LSCS scar suggestive of scar ectopic pregnancy. Cardiac flicker was absent and outline of gestational sac was irregular suggesting missed abortion.

Both the cases were managed via laparoscopy under spinal anaesthesia. Uterine manipulator was inserted. On Laparoscopy, a bulge was seen in the lower segment at the site of previous LSCS scar with progression towards bladder (Fig 2).

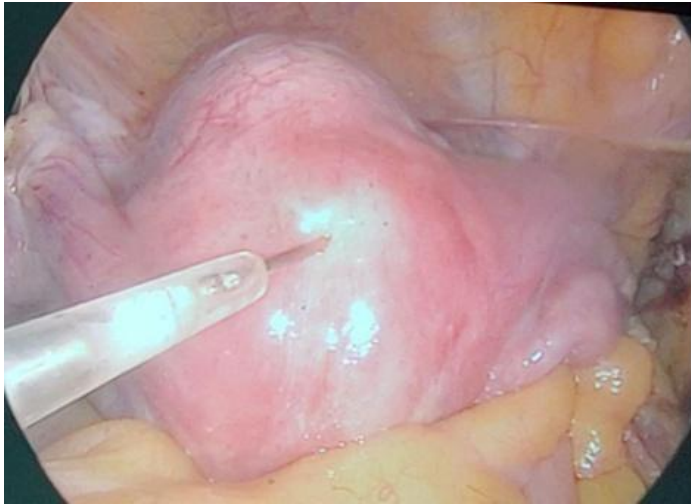


Fig 2: Bulge seen in lower uterine segment.

Adhesions were present. After adhesiolysis, retro peritoneum was entered. Para rectal and paravesical spaces were created. Ureterolysis was performed to free the peritoneal as well as uterine artery attachments. The uterine artery was skeletonized cephalad to the hypogastric bifurcation and was coagulated at origin by harmonic to minimize the bleeding (Fig 3). Similar procedure repeated on other site. 10% of injection vasopressin injected in the myometrium .

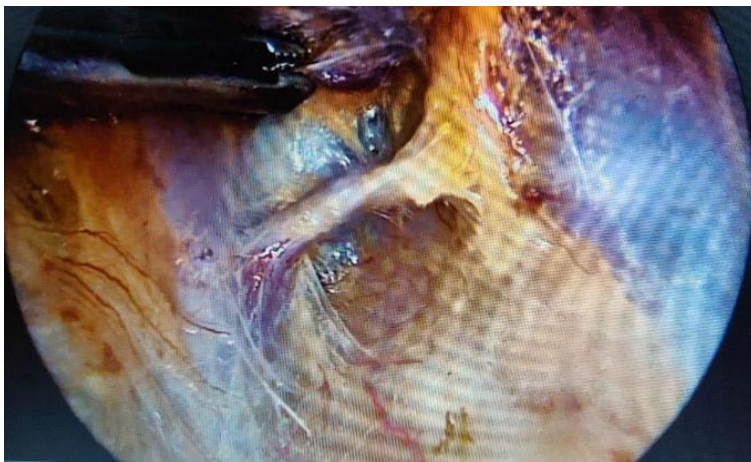

Fig 3: Uterine artery coagulated at origin.

UV fold of peritoneum dissected and bladder mobilized downward carefully exposing cervicovesical fascia and the lower margin of cervix. Then the cervicovesical fascia was mobilized sufficiently down so as to visualize the thin bluish tinge of the sac seen through the isthmus. The incision was taken over the sac with the active blade of harmonic. Amniotic fluid was drained out by suction, and the sac enucleated followed by retrieval in endobag (Fig 4).

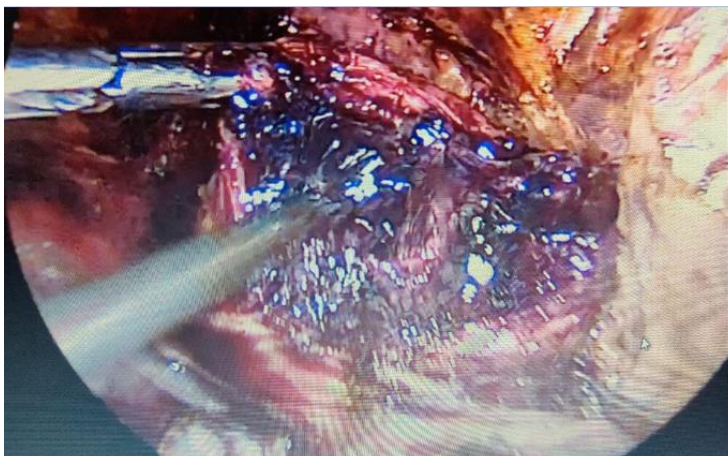


Fig 4: Enucleation of the sac.

It was ensured all the products of conception were removed and it was sent for histopathological examination. After thorough suctioning and draining the uterine cavity, scar margins were freshened and repair of defect done laparoscopically with barbed suture (V-Loc) (Fig 4) .

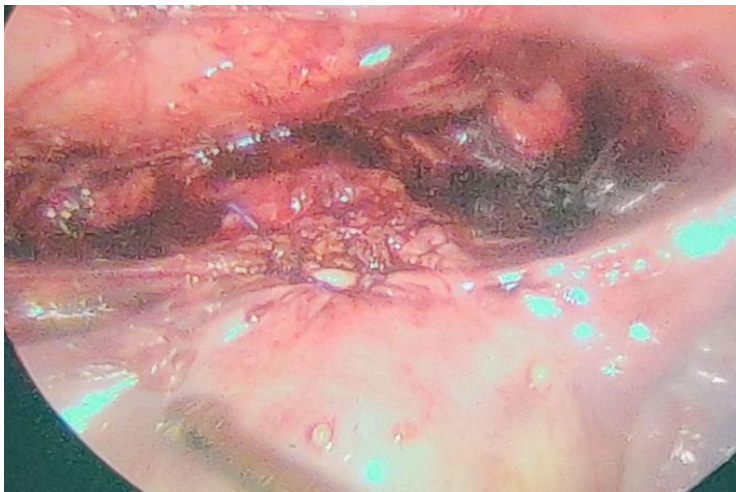


Fig 4: scar defect repair.

Both patients were hemodynamically stable postoperatively and were discharged the next day with advice to avoid conception for the next 6 months.

DISCUSSION:

Caesarean scar pregnancy has been hypothesized to occur from early invasion of myometrium which occurs through a microscopic tract in caesarean scar tissue.³

Two types of Caesarean scar pregnancy have been explained:

Endogenic or Type I or Exogenic or type II.

Endogenic caesarean scar pregnancy progresses towards cervicoisthmic space, or uterine cavity could progress to viability but with high risk of bleeding from placental site. Exogenic progresses towards bladder or abdominal cavity with deep invasion of scar defect. Type II usually complicates with uterine rupture or bleeding in early pregnancy.⁴ Though scar ectopic pregnancy is a rare condition, the incidence is on the increasing trend due to increase in the incidence of cesarean deliveries and availability of good imaging techniques. Ultrasound plays a pivotal role in diagnosis. Caesarean scar pregnancy is characterized by certain ultrasound findings:⁵

1. An empty uterine cavity and cervical canal .
2. Discontinuity in anterior uterine wall when running through amniotic sac and the gestational sac is located in anterior isthmus portion of uterus with diminished myometrium between bladder and gestational sac.
3. Circular blood flow surrounding the sac on Doppler.

Aborting gestation and cervical pregnancy are easily mistaken for caesarean scar pregnancy. Early diagnosis is very essential to prevent serious complications like severe hemorrhage which endangers a woman's life. Moreover there is lack of therapeutic protocols for optimal management of the patient since the condition is rare. Selection of modality of treatment depends on clinical condition of the patient, severity of symptoms, gestational age, desire for preserving fertility, and finally experience of the surgeon.

Treatment options available and reviewed are

- Dilatation and curettage and excision of trophoblastic tissue using laparoscopy or laparotomy.
- Local or systemic Methotrexate.
- Bilateral internal artery ligation and dilatation and extraction under laparoscopic guidance.
- Selective uterine artery embolization +D n C and Methotrexate
- Transvaginal resection
- Hysteroscopy

A systematic review of above management option was done by Petersen et al⁶ focusing on efficacy and complications related to each method in 2037 cases, where it was found that laparoscopy has 97.1% success rate with no severe complications. Rest of management options had a variable success rate. Least success rate was seen with expectant management of 41.5% with

complication rate of 53.7%. Maximum success rate was noticed with High intensity focused ultrasound (HIFU) ablation of 100% with no complications, but only 16 cases were studied as compare to 69 cases who underwent laparoscopy.

Interventional approach is preferred in management of caesarean scar pregnancy. Laparoscopic management is a reasonable approach if the facilities and expert surgeon are available. It gives excellent view of pathology at hand and offers benefit of removal of ectopic tissue with complete reconstruction of the lower uterine segment, which may be important for outcomes of pregnancies.

CONCLUSION:

Minimally invasive approach for treatment of caesarean scar pregnancy reduces admission to recovery time for the patient as compared to medical management. Retroperitoneal approach of bilateral uterine ligation minimizes the risks of bleeding and further complications. Freshening margins of previous caesarean scar and repair reduces the chances of re-implantation of pregnancy at caesarean site, in turn beneficial for the patients desiring of future fertility.

Funding: None.

Conflict of Interest: None declared.

REFERENCES:

1. Fuchs N, Manoucheri E, Verbaan M, Einarsson JI. Laparoscopic management of extrauterine pregnancy in caesarean section scar: description of a surgical technique and review of the literature. BJOG 2014; DOI: 10.1111/1471-0528.13060
2. Menon RM. Laparoscopy in caesarean scar pregnancy. World J Lap surg 2017; 10 (3):135-138
3. Godin PA, Bassil S, Donnez J. An ectopic pregnancy developing in previous caesarean section scar. Fertil Steril 1997 Feb ;67(2):398-400.
4. Maheux-Lacroix S, Li F, Bujold E, Nesbitt-Hawes E, Deans R, Abbott J. Cesarean scar pregnancies-a systematic review of treatment options. J Minim Invasive Gynaecol 2017 Sep-Oct ;24(6): 915-925.
5. Jurkovic D, Hillaby K, Woelfer B, Lawrence A, Salim R, Elson CJ. First trimester diagnosis and management of pregnancies implanted into the lower segment cesarean section scar. Ultrasound Obstet Gynaecol 2003 Mar;21(3): 220-227.
6. Birch Petersen K, Hoffmann E, Riffjer Larsen B, Svarre Neilsen H. Cesarean scar pregnancy: a systematic review of treatment studies Fertil Steril 2016 Apr; 105(4):958-967.