

# Scrotal Calcinosis - A Rare Idiopathic Benign Entity and Diagnostic Dilemma

Dr. Ujwala Maheshwari<sup>1</sup>, Dr. Almas Ibrahim Dalvi<sup>2</sup>, Dr. Ankita Raj<sup>3</sup>, Dr. Piyush Sahu<sup>4</sup>

<sup>1</sup>Professor, <sup>2</sup>Junior Resident (Corresponding author), <sup>3</sup>Senior resident, <sup>4</sup>Assistant Professor  
Department of Pathology,

<sup>1</sup>Mahatma Gandhi Mission's Medical College, Kamothe, Navi Mumbai

**Abstract:** Scrotal calcinosis is an uncommon benign medical condition. The pathogenesis of this disease is still ambiguous. Patients mostly present with an asymptomatic nodule gradually increasing in size in the absence of any metabolic or systemic disorder. These intradermal nodules containing calcium deposits vary in number and size.

We report a case of scrotal calcinosis in a 51-year-old man who presented with a solitary hard, painless swelling in the scrotal wall. The nodule was surgically excised and sent for histopathological examination. Only dermis with vast areas of calcification and fibrosis were examined on histopathology.

**Keywords:** Scrotal calcinosis, calcium deposits, idiopathic, nodule

## INTRODUCTION

Idiopathic scrotal calcinosis (ISC) is a rare benign medical condition characterized by multiple and typically asymptomatic nodules on the scrotal skin wall. It is a rare disorder which was first described by H. M. Lewinski in the year 1883<sup>1</sup> and later named by Shapiro et al in the year 1970.<sup>13</sup> Calcinosis cutis is defined as abnormal deposition of calcium salts in the subcutaneous tissue or skin. Four types of calcinosis cutis are known to occur based on the etiology: idiopathic, dystrophic, metastatic and iatrogenic.<sup>2</sup>

It is categorised as idiopathic only after carrying out a complete biochemical and hormonal profile to rule out other causes and confirming the absence of calcification elsewhere in the body. Scrotal calcinosis is usually asymptomatic and variation is observed in number as well as size. In few patients, other symptoms reported are itching, ulceration, discharge of chalky material and secondary bacterial infection occasionally. Other than the scrotum, other sites in the genitalia are vulval and penile where cases of calcinosis have been reported.<sup>3, 4, 5</sup>

This lesion commonly appears in the third and fourth decade of life; nonetheless few cases have also been reported in extremes of age. The disease usually takes an indolent course, growing gradually in size over several years.

## CASE REPORT

A 51-year-old male presented with a hard, painless lump over the right scrotal wall since one year gradually increasing in size with normal serum calcium and phosphorus levels. No past history of trauma, metabolic disorders or sexually transmitted diseases was elicited.

On physical examination, a single, nodular lesion measuring 2 x 1 cm was noted on the right scrotal wall skin which was non-tender and painless on palpation with no redness or changes in the overlying skin. It was movable in relation to the underlying structures and fascia.

Gross examination: A single, globular, grey-white tissue piece which was firm to hard in consistency was noted measuring 2 cm in diameter. The cut surface showed chalky white homogenous area. (Figure 1)

Microscopy: Microscopic examination revealed a well circumscribed lesion comprising abundant amorphous basophilic material (calcium deposits) along with mild mononuclear inflammatory infiltrate comprising lymphocytes, histiocytes and occasional neutrophils in the subcutaneous tissue. Occasional foreign body giant cells were also noted. (Figure 2 and 3)



Figure 1

**Figure 1:** Gross examination reveals a nodular lesion with cut surface showing chalky-white homogenous areas of calcium deposition.

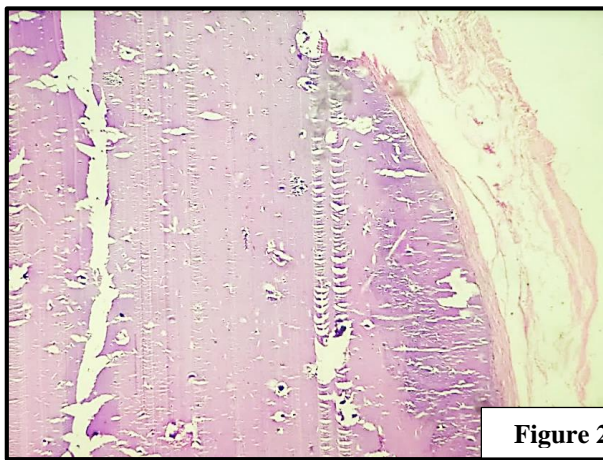


Figure 2

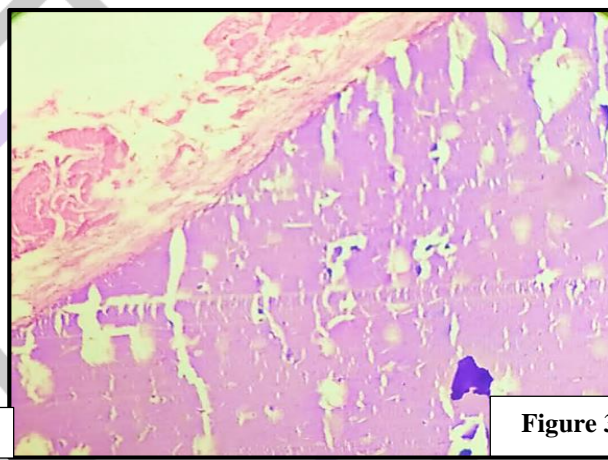


Figure 3

**Figure 2 (4x magnification) and Figure 3 (10x magnification):** Sections show well circumscribed intradermal nodule with amorphous basophilic material (calcification).

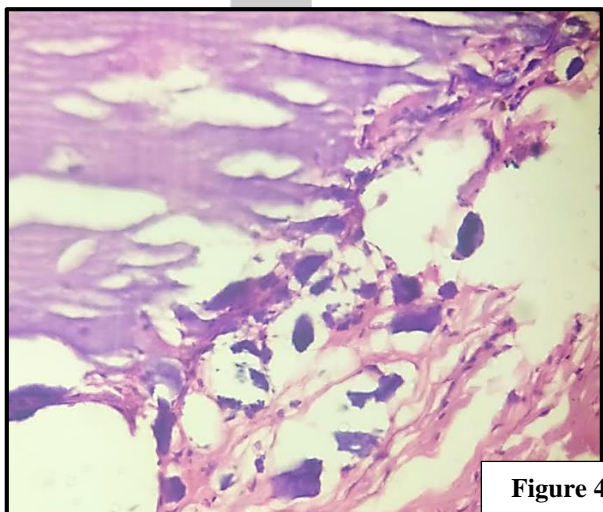


Figure 4

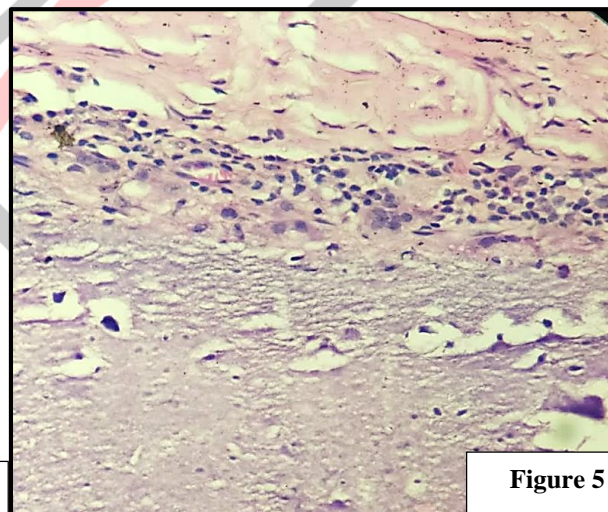


Figure 5

**Figure 4 and 5 (40x magnification):** Sections studied show calcified areas in the dermis along with mild mononuclear inflammatory infiltrate.

## DISCUSSION

Scrotal calcinosis is characterized by scrotal nodules which are firm to hard, single or multiple and vary in size from few millimetres to few centimetres. They are most commonly asymptomatic and cosmetic concern is the main purpose for medical consult. The exact cause of scrotal calcinosis remains equivocal and continues to be debated. It has been stated by Dubey et al. that inflammation

of epidermal cyst can result in dystrophic calcification of the cyst wall followed by degeneration of the cyst wall. The only remnants in these cases are calcific deposits.<sup>6,8</sup>

Other possible hypothesis proposed include calcification secondary to minor trauma of the scrotum<sup>9</sup>, eccrine duct millia<sup>10</sup>, or degeneration of dartoic muscle.<sup>7</sup> Histopathology is the required investigation for definitive diagnosis. Histopathology reveals only presence of amorphous calcium deposits in the dermis without evidence of any preceding keratinous or epithelial cyst lining. Only in few cases it has been observed that fine needle aspiration cytology may help in the diagnosis in pre-operative period and is otherwise not helpful.<sup>12</sup>

Most common cause of calcinosis cutis is dystrophic calcification. Normal levels of serum calcium, phosphorus and blood glucose have been observed in most of the patients. There is no evidence of any association found of idiopathic scrotal calcinosis with endocrinologic, metabolic, or systemic diseases. In a small proportion of the cases, association with few connective tissue disorders, for example dermatomyositis, scleroderma and systemic lupus erythematosus were identified.<sup>11</sup>

Surgical excision from the scrotal wall is the choice of treatment with good aesthetic outcome. The calcified nodules are confined in the dermis of the scrotum and hence the excision is limited only to the scrotal skin. However, cases of recurrence have also been reported due to remnants of neglected microscopic calcific areas. Malignant transformation has not been reported in any of the cases. Differential diagnosis includes other benign conditions of the scrotum such as epidermal inclusion cyst, calcified onchocercoma, angiokeratoma, steatocystoma and lymphangioma circumscriptum.<sup>7,14</sup>

## CONCLUSION

Idiopathic scrotal calcinosis is a benign condition seen in mostly young adults, which is generally asymptomatic. It presents as one or more solid nodules of varying size in the scrotal skin. Complete excision remains the gold standard treatment and diagnosis is confirmed on histopathology which demonstrates areas of calcification. It is essential to inform the patient about the chances of recurrence. Although it is considered as an idiopathic benign disease, the patients should be thoroughly investigated for any metabolic or systemic disorders and any hidden pathology must be ruled out.

## REFERENCES

- [1] Lewinski HM. Lymphangiome der Haut mit Verkalkem Inhalt. Arch Pathol Anat. 1883; 91:371–4.
- [2] Valenzuela A, Chung L. Calcinosis: pathophysiology and management. Curr Opin Rheumatol. 2015;27(6):542–8.
- [3] Coban YK, Aytakin AH, Aydin EN. Idiopathic Calcinosis Cutis of the Vulva. Indian J Dermatol. 2013;58(6):464–6.
- [4] Cohen PR, Tschen JA. Idiopathic calcinosis cutis of the penis. J Clin Aesthet Dermatol. 2012;5(12):23–30.
- [5] Katoh N, Okabayashi K, Wakabayashi S, Kishimoto S, Yasuno H. Dystrophic calcinosis of the penis. J Dermatol. 1993;20(2):114–7.
- [6] Dubey S, Sharma R et al. Scrotal calcinosis: idiopathic or dystrophic? Dermatology Online Journal, vol. 16, no. 2, article 5, 2010.
- [7] Chaudhari S, Bhat S, Hatwal D, Bhat P, Batra N. Scrotal Calcinosis - An Etiological Dilemma: A Prospective Study. Int J Sci Stud 2015;3(7):186-188.
- [8] Swinehart JM, Golitz LE. Scrotal calcinosis. Dystrophic calcification of epidermoid cysts. Arch Dermatol 1982; 118:985-8.
- [9] Feinstein A, Kahana M, Schewach-Millet M, Levy A. Idiopathic calcinosis and vitiligo of the scrotum. J Am Acad Dermatol 1984; 11:519-20.
- [10] Dare AJ, Axelsen RA. Scrotal calcinosis: Origin from dystrophic calcification of eccrine duct milia. J Cutan Pathol 1988; 15:142-9.
- [11] Kaur G, Phogat D, Trehan A. Idiopathic scrotal calcinosis. J Mar Med Soc 2017; 19:131-3.
- [12] Chakrabarti I, Sharma SR. Idiopathic scrotal calcinosis: Is cytological diagnosis enough? Indian Dermatol Online J. 2013; 4(1): 58–59.
- [13] Shapiro L, Platt N, Torres-Rodriguez VM. Idiopathic calcinosis of the scrotum. Arch Dermatol. 1970; 102(2):199- 204.
- [14] Ruiz-Genao DP, Rios-Buceta L, Herrero L, Fraga J, Aragüés M, Garcia-Diez A. Massive scrotal calcinosis. Dermatol Surg. 2002;28(8):745-747.