

# Deciphering Intra-abdominal Ruptured Liver Abscess: Analyzing Computed Tomography Scans and Clinical Presentations

<sup>1</sup>Dr B Kranthi Abhishek, <sup>2</sup>Dr Avala Varun Sai, <sup>3</sup>Dr Pawar Swathi, <sup>4</sup>Dr B Sridhar, <sup>5</sup>Dr B Nuthan, <sup>6</sup>Dr G S Kejiriwal <sup>6,7</sup>Professor, <sup>7</sup>Dr J C Naidu, <sup>8</sup>Dr Giridhar Gopal

<sup>1,2,3,4</sup>Junior resident, <sup>5</sup>Senior Resident, <sup>6,7,8</sup>Professor  
Department of Radio Diagnosis  
Maharajah's Institute of Medical Sciences (MIMS)  
Nellimarla, Vizianagaram, Andhra Pradesh, India.

## Abstract-

**Objectives:** This study aims to elucidate the computed tomography (CT) and clinical findings associated with intra-abdominal ruptured liver abscesses.

**Patients and Methods:** Retrospective analysis was conducted on CT and clinical data of 32 patients diagnosed with intra-abdominal ruptured liver abscesses at Maharajah's Institute of Medical Sciences (MIMS), Nellimarla between 2022 and 2023.

**Results:** The study comprised 32 patients with a median age of 53.3±15.3 years (range, 24–85 years). Male predominance was observed, with a male-to-female ratio of 1.9:1. Predominant clinical symptoms included abdominal pain (96.9%), malaise and anorexia (96.9%), fever (78.1%), and peritonitis (78.1%). The mean size of liver abscesses was 8.4 cm (range, 4.0–14 cm), with single abscesses in 11 patients and multiple abscesses in 21 patients. Unilobar involvement was predominant, with the right lobe affected in 68.8% (22 of 32) of cases. Abscess liquefaction was observed in 25 patients, while gas was present in the abscess cavity in 7 patients. Free intraperitoneal fluid was evident in all patients.

**Conclusion:** Understanding intra-abdominal ruptured liver abscesses is crucial for early diagnosis and appropriate management.

**Keywords:** Liver abscess, ruptured, computed tomography, clinical.

## Introduction:

Liver abscess is a significant health issue in tropical regions, often associated with considerable morbidity and mortality rates. Traditionally, hepatic abscesses are categorized as either pyogenic or amoebic<sup>(1,2)</sup>, each presenting its unique set of complications, with abscess rupture being a prevalent concern<sup>(3-5)</sup>. Intra-abdominal rupture of liver abscess, although rare, represents a potentially life-threatening condition, particularly affecting elderly individuals burdened with significant medical co morbidities and surgical risks<sup>(6,7)</sup>. Achieving an accurate preoperative diagnosis remains challenging, often requiring exploratory laparotomy to address resultant peritonitis effectively<sup>(8)</sup>.

Computed tomography (CT) plays a crucial role in the diagnosis of hepatic abscesses, boasting a high sensitivity of up to 97 %<sup>(9)</sup>. CT imaging typically depicts hepatic abscesses as single or multiloculated masses with low attenuation<sup>(9)</sup>, enabling timely detection and intervention to mitigate associated morbidity and mortality risks. Timely identification and appropriate management of hepatic abscesses are paramount in preventing adverse outcomes. Although mortality rates are relatively low when the abscess remains confined to the liver, extension into adjacent cavities significantly increases mortality risks<sup>(10)</sup>. While hepatic abscesses may give rise to various complications<sup>(11-13)</sup>, reports detailing complications specifically in pyogenic hepatic abscesses are sparse<sup>(10)</sup>. Limited studies have focused on imaging characteristics in a small patient cohort<sup>(13,14)</sup>. This article presents the CT and clinical findings of patients diagnosed with intra-abdominal ruptured liver abscesses.

## Patients and Methods:

This retrospective observational study examines patients presenting with intra-abdominal ruptured liver abscesses at Maharajah's Institute of Medical Sciences, Nellimarla between 2022 and 2023. The study received approval from the Hospital Ethical Board. All diagnosed cases of ruptured liver abscess, confirmed through radiological and laparoscopic investigations, were included. Patient demographics, clinical characteristics, and computed tomography findings were documented. Data analysis will be performed using SPSS software.

### Clinical Parameters:

In this study, clinical parameters encompassed demographic characteristics, including age and sex, alongside detailed information regarding underlying medical conditions. These conditions comprised diabetes mellitus, biliary disorders, hemodialysis, liver cirrhosis, malignancy, immunosuppression, as well as the presence of cavities from old calcified echinococcus cysts or simple benign liver cysts. Additionally, the study meticulously recorded symptoms and signs observed at presentation, along with the origin of the abscess. Furthermore, the administration of empiric antibiotic therapy prior to admission was documented for each patient.

### Liver CT Characteristics:

Prior to laparoscopic drainage of the liver abscess, all patients underwent contrast-enhanced CT examinations. In some instances, additional CT studies were performed during follow-up to monitor the size of the abscess cavity and identify any complications. However, for the purpose of this study, only the contrast-enhanced CT images acquired before abscess drainage were reviewed. CT scans were conducted using GE Revolution 16 slice machine. Scan parameters varied over the study period and across different scanners, including collimation (ranging from 1.25 mm to 7 mm), pitch (ranging from 0.75 to 1.5), and section thickness (ranging from 1 mm to 5 mm). Intravenous non-ionic iodinated contrast medium (Omnipaque) was administered at a dosage calculated based on patient weight and delivered via a power injector at a rate of 3 mL/sec. Axial sections, with a thickness of 3-5 mm, were reconstructed, reported, and archived.

The CT scans were interpreted by two radiologists, and a consensus was reached between them. The recorded CT features included: (a) lobe involvement (unilobar [right or left] or bilobar), (b) number of abscesses (single or multiple), (c) maximal abscess diameter (with measurement of the largest abscess in cases of multiple abscesses), (d) presence of unilocular or multilocular abscess (identified by the presence of  $\geq 1$ -mm-thick septations), (e) assessment of solid or cystic appearance (with an attenuation value of  $\leq 20$  HU, indicating  $>50\%$  of the abscess cavity appears hypodense or liquefied, predominantly in most sections showing the abscess cavity), (f) identification of gas within the abscess cavity, and (g) determination of spontaneous rupture of the abscess (based on CT findings and clinical symptoms).

## Results

### Clinical Features:

The study cohort comprised 32 patients, with a median age of  $53.3 \pm 15.3$  years (range, 24-85 years). There was a male predominance, with a male-to-female ratio of 1.9:1. The most prevalent underlying medical condition was diabetes mellitus (25.0%), followed by bacterial pneumonia (18.8%), hypertension (6.3%), and bile duct stones (3.1%), as detailed in Table 1. Notably, none of the patients had cirrhosis. The majority of patients presented with abdominal pain (96.9%), malaise and anorexia (96.9%), fever (78.1%), peritonitis (78.1%), and other clinically significant signs, as outlined in Table 2.

**Table 1. Underlying Diseases among Patients with Intra-abdominal Ruptured Liver Abscess**

Underlying Disease	Frequency	Percentage (%)
Hypertension	2	6.3
Diabetes Mellitus	8	25.0
Bacterial Pneumonia	6	18.8
Bile Duct Stones	1	3.1

Note: None of the patients had cirrhosis.

**Table 2. Clinical Presentations of Intra-abdominal Ruptured Liver Abscess**

Clinical Presentation	Frequency	Percentage (%)
Abdominal Pain	31	96.9
Malaise and Anorexia	31	96.9
Nausea/Vomiting	20	62.5
Fever $>38^{\circ}\text{C}$	25	78.1

Clinical Presentation	Frequency	Percentage (%)
Jaundice	5	15.6
Peritonitis	25	78.1
Hepatomegaly	4	12.5

### Liver CT Characteristics:

The average time lapse between the onset of fever and CT imaging was 8.3 days (range, 1-30 days). The average size of the liver abscess was 8.4 cm (range, 4.0-14 cm). Among the patients, 11 exhibited a solitary abscess, while 21 manifested multiple abscesses. Unilobar involvement was evident in 29 patients, predominantly affecting the right lobe (68.8%, 22 out of 32 cases). The abscesses appeared completely liquefied in 25 patients, whereas gas was observed within the abscess cavity in 7 patients. Free intraperitoneal fluid was detected in all patients. Comprehensive liver CT characteristics of intra-abdominal ruptured liver abscesses are outlined in Tables 3 and 4. Figures 1 and 2 depict CT scan images illustrating the ruptured liver abscesses.

### Discussion:

Liver abscess represents a significant gastrointestinal ailment, particularly prevalent in tropical regions<sup>(15, 16)</sup>. It is typically categorized into pyogenic and amoebic types, both of which carry serious implications, especially when diagnosed late. In developing nations, liver abscess stands out as a major contributor to mortality and morbidity rates<sup>(17, 18)</sup>. Despite the advent of modern radiological techniques, diagnosing hepatic abscesses in their early stages allows for nonsurgical management. However, a portion of patients, either due to delayed presentation or resistant disease, may develop ruptured liver abscesses, thereby escalating mortality rates and necessitating urgent surgical intervention<sup>(8, 19)</sup>.

CT findings	All patients (n=32)
Abscess size (cm)	8.4 (4.0–14)
No. of abscesses	
1	11 (34.4)
>1	21 (65.6)
Lobar involvement	
Unilobar	29 (90.6)
Bilobar	3 (9.4)
Abscess appearance	
Completely liquefied	25 (78.1%)
Gas in the abscess cavity	7 (21.9)
Peritoneal effusion	32 (100%)

Table 4. Locations of rupture on CT-scanned image

Liver segments	Right lobe VI			Left lobe			
	IV	V	VI	VII	VIII	II	III
N (%)	5 (15,6)	8 (25)	13 (40,6)	8 (25)	8 (25)	8 (25)	5 (15,6)
Total	22 (68, 8%)			7 (21, 9%)			

Intraperitoneal rupture stands as a significant complication of liver abscesses<sup>(5, 10, 20, 21)</sup>, with its occurrence frequency ranging from 2.5% to 17%<sup>(22)</sup>. Clinically, escalating hepatic tenderness may serve as an indicator of an impending rupture<sup>(22)</sup>. Computed tomography (CT) imaging assumes a pivotal role in gauging the extent of intraperitoneal dissemination of the liver abscess. In a study by Dal Mo Yang et al.<sup>(23)</sup>, comprising 81 patients with confirmed pyogenic hepatic abscess, complications manifested in 3 patients (3.7%). Two discernible types of complications surfaced: loculated perihepatic abscess (n=2) and diffuse peritonitis (n=1). In instances of diffuse peritonitis stemming from hepatic abscess rupture, CT scans typically unveil copious ascites and diffuse thickening of the parietal peritoneum. While amoebic peritonitis following the rupture of a hepatic amoebic abscess carries a dismal survival rate despite surgical intervention, all patients with intraperitoneal rupture of pyogenic hepatic abscesses could be effectively managed through percutaneous drainage and antibiotic therapy.

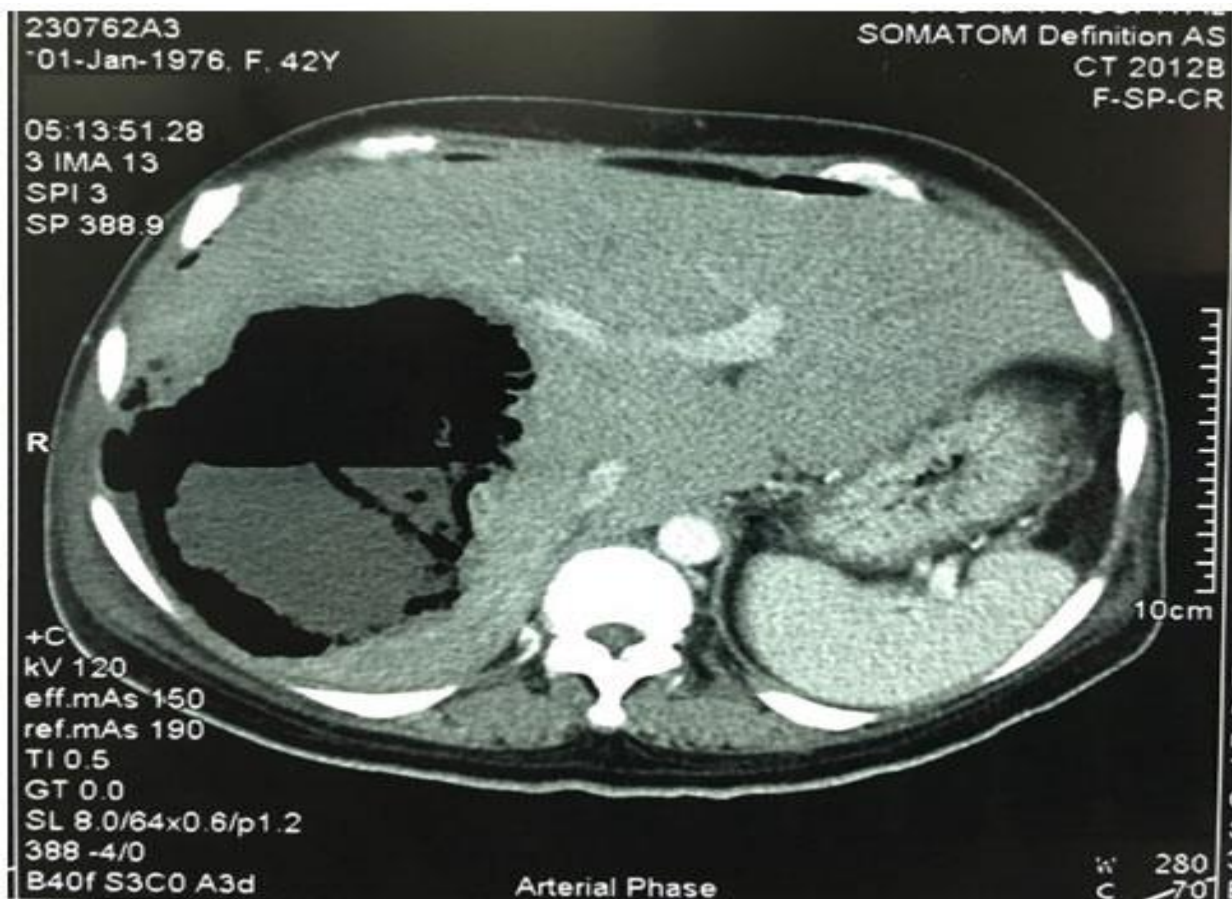


Figure 1 illustrates a case involving a 42-year-old woman who experienced a rupture of a pyogenic hepatic abscess into the peritoneal cavity, leading to peritonitis. The abscess is situated within the right hepatic lobe, with evidence of gas accumulation inside it.

The predominant clinical presentation included abdominal pain (96.9%), malaise and anorexia (96.9%), fever (78.1%), peritonitis (78.1%), nausea/vomiting (62.5%), and jaundice and hepatomegaly (15.6% and 12.5%, respectively). These findings are consistent with those reported by Hind S. Alsaif, where fever and/or chills were the most common presentation, followed by gastrointestinal symptoms (e.g., upset stomach, diarrhea, vomiting, nausea, discomfort, pain), respiratory symptoms (e.g., cough, dyspnea, chest distress), and jaundice<sup>(24)</sup>. The clinical features of ruptured liver abscesses from other studies were summarized in Table 5.

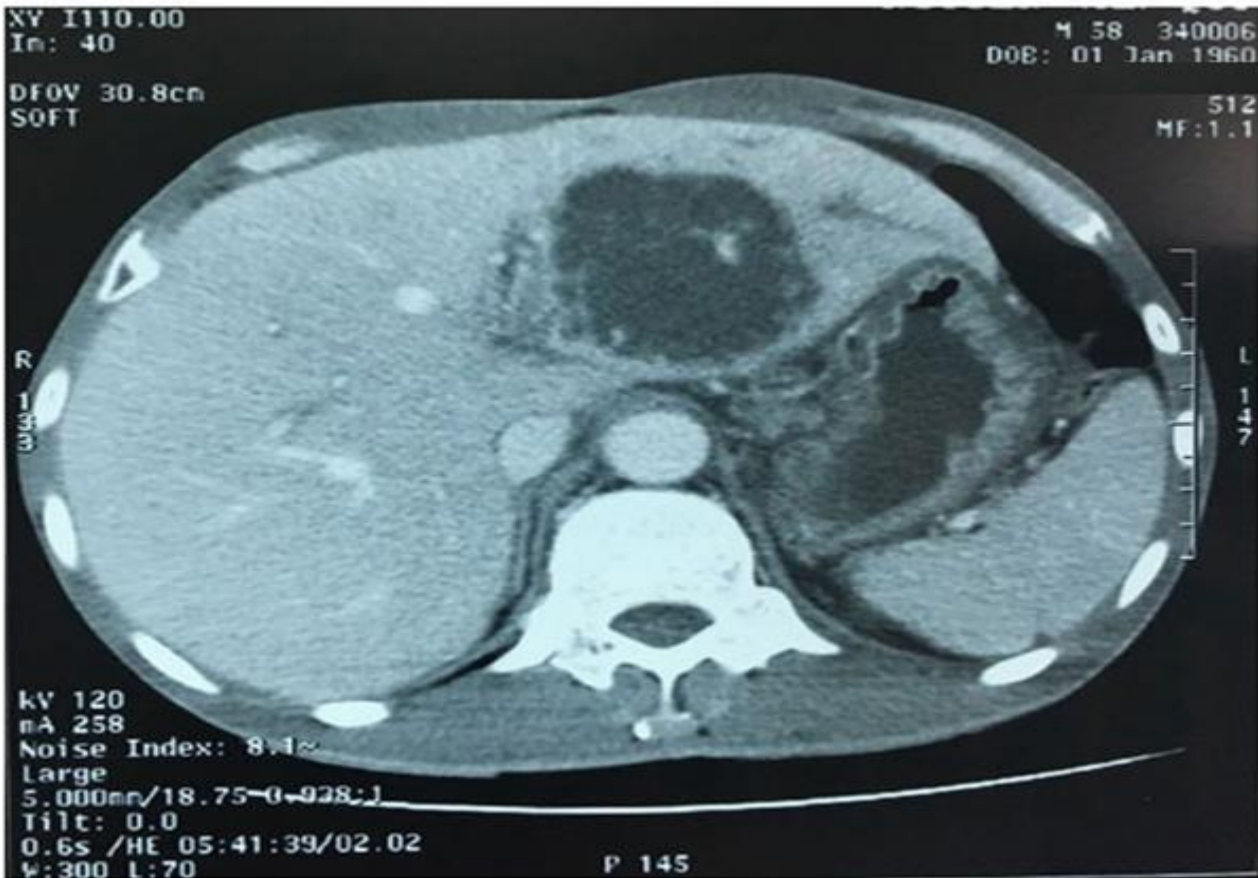

Figure 2 depicts a 62-year-old man with a ruptured pyogenic hepatic abscess, resulting in a perihepatic abscess formation. Enhanced helical computed tomography (CT) reveals a heterogeneously hypodense abscess in the left hepatic lobe.

The CT appearance of liver abscesses can be diverse and lacks specificity. Typically, CT scans reveal one or more round or oval lesions with low density, ranging from 2 to 16 cm in diameter. The margin of the abscess may appear smooth or nodular, and internal septations might be present. While an enhancing wall is often observed, it may not always be visible without contrast-enhanced CT scans. Therefore, the differential diagnosis of an amebic liver abscess in adults encompasses various conditions, including simple hepatic cysts, infected or hemorrhagic cysts, pyogenic liver abscesses, echinococcal cysts, hematomas, bilomas, cystic or necrotic hepatic metastases, undifferentiated embryonal sarcomas, and biliary cystadenomas. In cases where there is a rim of edema surrounding the lesion, diagnostic considerations may be narrowed down to inflammatory conditions <sup>(26)</sup>. One characteristic feature that can help differentiate an amebic liver abscess from other focal hepatic lesions is its tendency to extend beyond the liver's surface.

**Table 5. Presentation symptoms according to other studies**

Symptoms	Shrikant Perka et al (2016) <sup>(25)</sup>	Alexopoulou A et al (2010) <sup>(3)</sup>	Mukhopadhyay M et al (2010) <sup>(4)</sup>
Pain	100%	75.7%	83%
Fever	86.7%	96.7%	80%
Vomiting	43.3%	--	--
Cough/pleurisy	30%	--	26.4%
Diarrhea	53.3%	--	--
Jaundice	--	12.1%	--

Our study on liver CT characteristics is consistent with previous research. Alsaif et al. reported a median interval of 3 days (range: 1–24 days) between fever onset and CT imaging. The median liver abscess size was 7 cm (range: 1.7–14 cm). They found a single abscess in 95 patients, with multiple abscesses seen in 36 patients. Unilobar involvement occurred in 100 patients, predominantly affecting the right lobe (55.0%, 72 of 131). Abscesses were mainly solid and mass-like in 67 patients and cystic in 64 patients. Multilocular abscesses were observed in 115 patients (87.8%). Thrombophlebitis was present in 30 patients, pylephlebitis in three, and gas in the abscess cavity in 17 cases, with six

patients showing pneumobilia. Gas formation was noted in four patients (12.1%), and localized sub collections were observed in three (9%)<sup>(24)</sup>.

In the study by Alexopoulou et al., most liver abscesses (69.7%) involved the right lobe, with sizes ranging from 5 to 9 cm in 63.6% of cases, primarily presenting as solitary lesions (75.7%). Multiple abscesses were found in 24.2% of patients. Chest radiography revealed an elevated hemi diaphragm (42.4%), pleural effusion (18.2%), and basilar infiltrate (6%). Liver abscess was accompanied by pylephlebitis in one patient. Gas formation occurred in four patients (12.1%), and localized sub collections were seen in three (9%)<sup>(3)</sup>.

Chang Z et al. found a single abscess in 54 patients (81.8%) and multiple abscesses in 12 patients (18.2%)<sup>(27)</sup>. Among those with multiple abscesses, the average number of lesions per patient was 2.5. Unilobar involvement was seen in 54 patients (81.8%), and multilocular abscesses were present in 50 patients (75.8%). Thrombophlebitis was present in nine patients (13.6%), and gas in the abscess cavity was noted in 11 patients (16.7%). Additionally, four patients (6.1%) experienced spontaneous abscess rupture<sup>(27)</sup>.

A precise diagnosis of liver abscess typically relies on imaging techniques, with both sonography and CT scans playing crucial roles. While sonography is a valuable tool, it is operator-dependent and may face limitations in identifying small or solitary abscesses. Its sensitivity, averaging around 79%, falls short compared to the higher sensitivity of CT scans, which can reach up to 98%<sup>(28)</sup>. However, in urgent scenarios, such as bedside assessments, sonography can offer swift insights into potential abscesses.

Certain distinctive features observable on CT scans, such as the presence of a hairball sign or an air-fluid level, may strongly indicate a Klebsiella abscess<sup>(29)</sup>. Nevertheless, it's important to note that while these imaging distinctions are helpful, the ultimate choice of antibiotics should be guided by culture and sensitivity results.

The progression of radiologic techniques has significantly contributed to improved patient outcomes, particularly in terms of mortality rates associated with liver abscesses. Both ultrasonography and CT scans with contrast remain the preferred modalities for screening and diagnosis. Moreover, they serve as effective tools for guiding percutaneous procedures like aspiration and drainage.

With the evolution of multidetector CT scan technology, there has been a notable enhancement in image quality, leading to more precise and reliable detection of liver abscesses. Additionally, the utilization of gallium and technetium radionuclides has expanded the diagnostic capabilities, offering further insights into the nature and extent of liver abscesses.

### Conclusion:

The rupture of a hepatic abscess poses a grave risk compared to its non-ruptured counterpart. Timely and precise diagnosis, followed by prompt surgical intervention, is paramount in effectively managing such cases. The majority of patients typically manifest acute symptoms, with the right lobe of the liver being predominantly affected. Among the symptoms, abdominal pain emerges as the most prevalent. Computed tomography emerges as the cornerstone diagnostic modality for identifying hepatic abscesses and their associated complications due to its superior imaging capabilities.

It's worth emphasizing that the prompt identification of a ruptured hepatic abscess is crucial, as it significantly impacts patient outcomes. Therefore, healthcare providers should remain vigilant for any signs or symptoms suggestive of this complication, especially in patients with predisposing factors such as underlying liver disease or immunocompromised status.

Furthermore, multidisciplinary collaboration among clinicians, radiologists, and surgeons is essential for ensuring timely and appropriate management strategies. By leveraging the collective expertise of various healthcare professionals, the holistic care of patients with ruptured hepatic abscesses can be optimized, ultimately improving clinical outcomes and reducing mortality rates associated with this serious condition.

In terms of competing interests, the authors affirm that they have no conflicts to declare, underscoring their commitment to transparency and ethical conduct in research and publication practices.

### Acknowledgements:

The authors are grateful to physicians, administrative staff at Maharajah's Institute of Medical Sciences (MIMS), Nellimarla for allowing us to undertake this research.

### REFERENCES:

1. Akhondi H and Sabih DE. Liver Abscess, in StatPearls. Treasure Island (FL). 2019.
2. Chia DWJ, Kuan WS, Ho WH, Sim TB and Chua MT. Early predictors for the diagnosis of liver abscess in the emergency department. Intern Emerg Med. 2019. | Article | PubMed
3. Alexopoulou A, Dimopoulou H, Soultati A, Panetsos G, and Dourakis SP. Factors related to complications and mortality in pyogenic liver abscesses. Annals of Gastroenterology. 2010; 23:296-301. 4. Mukhopadhyay M,

- Saha AK, Sarkar A and Mukherjee S. Amoebic liver abscess: presentation and complications. *Indian J Surg.* 2010; 72:37-41.
5. Satish KR, Sathyanarayana BA, Madhu SL, Nataraj NR, Amit GM and Hemanth V. A study of predictors for identification of risk of complications in patients with liver abscess. *Trop Gastroenterol.* 2015; 36:96-100. | PubMed
  6. Elechi EN and Etawo SU. Management of intraperitoneal rupture of amoebic liver abscess: a 6-year experience with 11 cases in Port Harcourt, Nigeria. *Trop Doct.* 1991; 21:43-4.
  7. Sarda AK, Bal S, Sharma AK and Kapur MM. Intraperitoneal rupture of amoebic liver abscess. *Br J Surg.* 1989; 76:202-3.
  8. Memon AS, Siddiqui FG, Memon HA and Ali SA. Management of ruptured amoebic liver abscess: 22-years experience. *J Ayub Med Coll Abbottabad.* 2010; 22:96-9. | PubMed
  9. Halvorsen RA, Korobkin M, Foster WL, Silverman PM and Thompson WM. The variable CT appearance of hepatic abscesses. *AJR Am J Roentgenol.* 1984; 142:941-6. | Article | PubMed
  10. Munoz LE, Botello MA, Carrillo O and Martinez AM. Early detection of complications in amoebic liver abscess. *Arch Med Res.* 1992; 23:251-3. | PubMed
  11. Mondragon-Sanchez R, Cortes-Espinoza T, Sanchez-Cisneros R, ParraSilva H and Hurtado-Andrade H. Rupture of an amoebic liver abscess into the pericardium. Presentation of a case and review of current management. *Hepatogastroenterology.* 1994; 41:585-8.
  12. Mowji PJ, Cohen AJ, Potkin B and Viltuznik J. Amoebic liver abscess with hepatoduodenal fistula. *Am J Gastroenterol.* 1987; 82:558-9. | PubMed
  13. Tandon N, Karak PK, Mukhopadhyay S and Kumar V. Amoebic liver abscess: rupture into retroperitoneum. *Gastrointest Radiol.* 1991; 16:240-2.
  14. Yamada S, Maruo H, Mori K and Kosaka A. [An unusual case of pyogenic hepatic abscess rupturing into the pericardial cavity]. *Nihon Kyobu Geka Gakkai Zasshi.* 1996; 44:2072-5. | PubMed
  15. Cook GC. Gastroenterological emergencies in the tropics. *Baillieres Clin Gastroenterol.* 1991; 5:861-86.
  16. Reeder MM. Tropical diseases of the liver and bile ducts. *Semin Roentgenol.* 1975; 10:229-43. | Article | PubMed
  17. Blessmann J, Van Linh P, Nu PA, Thi HD, Muller-Myhsok B, Buss H and Tannich E. Epidemiology of amoebiasis in a region of high incidence of amoebic liver abscess in central Vietnam. *Am J Trop Med Hyg.* 2002; 66:578-83. | Article | PubMed
  18. Kannathasan S, Murugananthan A, Kumanan T, de Silva NR, Rajeshkannan N, Haque R and Iddawela D. Epidemiology and factors associated with amoebic liver abscess in northern Sri Lanka. *BMC Public Health.* 2018; 18:118. | Article | PubMed Abstract | PubMed FullText
  19. Short M and Desai AP. Laparoscopy and transdiaphragmatic thoracoscopy in management of ruptured amoebic liver abscess. *J Laparoendosc Adv Surg Tech A.* 2008; 18:473-6.
  20. Adams EB and MacLeod IN. Invasive amoebiasis. II. Amoebic liver abscess and its complications. *Medicine (Baltimore).* 1977; 56:325-34. | Article | PubMed
  21. Jolobe OM. Intrahepatic expansion of amoebic liver abscess can also generate life-threatening complications. *South Med J.* 2010; 103:1189-90.
  22. Eggleston FC, Handa AK and Verghese M. Amoebic peritonitis secondary to amoebic liver abscess. *Surgery.* 1982; 91:46-8. | PubMed
  23. Yang DM, Kim HN, Kang JH, Seo TS, Park CH and Kim HS. Complications of pyogenic hepatic abscess: computed tomography and clinical features. *J Comput Assist Tomogr.* 2004; 28:311-7.
  24. Alsaif HS, Venkatesh SK, Chan DS and Archuleta S. CT appearance of pyogenic liver abscesses caused by *Klebsiella pneumoniae*. *Radiology.* 2011; 260:129-38.
  25. Perka S, Khajanchi M, Pothare A and Nandu V. Audit of patients with ruptured amoebic liver abscess and outcome of surgical versus nonsurgical treatment. *International Surgery Journal.* 2016; 3:2163-2166.
  26. Gabata T, Kadoya M, Matsui O, Kobayashi T, Kawamori Y, Sanada J, Terayama N and Kobayashi S. Dynamic CT of hepatic abscesses: significance of transient segmental enhancement. *AJR Am J Roentgenol.* 2001; 176:675-9.
  27. Chang Z, Zheng J, Ma Y and Liu Z. Analysis of clinical and CT characteristics of patients with *Klebsiella pneumoniae* liver abscesses: an insight into risk factors of metastatic infection. *Int J Infect Dis.* 2015; 33:50-4.
  28. Pearl R, Pancu D and Legome E. Hepatic abscess. *J Emerg Med.* 2005; 28:337-9.
  29. Kim SB, Je BK, Lee KY, Lee SH, Chung HH and Cha SH. Computed tomographic differences of pyogenic liver abscesses caused by *Klebsiella pneumoniae* and non-*Klebsiella pneumoniae*. *J Comput Assist Tomogr.* 2007; 31:59-65.